



Cauda Equina Syndrome Due to Arachnoiditis After Cesarean Section Under Combined Spinal-Epidural Anesthesia

MagdaTsolaki^{1*}, Ilias Katsoulas², Efthimios Dardiotis³, Vasileios Siokas⁴, Stelios Christodoulou⁵ and Eleni Arnaoutoglou⁶

¹Department of Neurology, Medical School, Aristotle University of Thessaloniki, Thessaloniki, Greece

²Medical school, Aristotle University of Thessaloniki, Thessaloniki, Greece

³Department of Neurology, University Hospital of Larissa, Faculty of Medicine, School of Health Sciences, University of Thessaly, 41100 Larissa, Greece

⁴Department of Neurology, Laboratory of Neurogenetics, University of Thessaly, University Hospital of Larissa, Greece

⁵Private Hospital Iassos, Larissa, Greece

⁶Department of Anesthesiology, School of Health Sciences, Faculty of Medicine, University of Thessaly, University Hospital of Larissa, 41110 Larissa, Greece

***Corresponding Author:** MagdaTsolaki, Department of Neurology, Medical School, Aristotle University of Thessaloniki, Thessaloniki, Greece.

Received: January 02, 2025

Published: January 14, 2025

© All rights are reserved by **MagdaTsolaki, et al.**

Abstract

This report presents a case of cauda equina syndrome resulting from toxic arachnoiditis caused by the administration of levobupivacaine with spinal-epidural anesthesia. A 31-year-old woman underwent a cesarean section using combined spinal-epidural anesthesia. However, post-surgery she developed monoparesis of her right lower extremity along with numbness in the same area and saddle-shaped numbness on the right side of her genital area. Subsequent tests including computed tomography of the lumbar and thoracic spine the following day and non-contrast magnetic resonance imaging of the lumbar spine performed five days later did not reveal any abnormal findings. However, contrast-enhanced magnetic resonance imaging of the cervical, thoracic, and lumbar spine after 6 days showed pathological contrast uptake from the meninges in the right lateral part of the conus medullaris and cauda equina roots consistent with arachnoiditis, with no other findings from the spinal cord. The patient was treated with anti-inflammatory treatment with hydrocortisone sodium succinate from the first day and then with high doses of methylprednisolone in combination with a program of physical therapy, kinesiotherapy, and psychotherapy. Despite the above holistic therapeutic approach, 7 years later the patient continued to report weakness and numbness of the lower limb, inability to urinate and defecate, and saddle hypoesthesia in the genital area. Physicians should be aware of the potential neurologic complications of spinal-epidural anesthesia, the potentially toxic role of levobupivacaine in the arachnoid and conus medullaris, and the potential failure of corticoid and physical therapy, although these cases are very rare.

Categories: Anesthesiology, Obstetrics/Gynecology, Neurosurgery.

Keywords: Cauda Equina Syndrome; Cesarean Section; Arachnoiditis; Anesthesia; Levobupivacaine

Introduction

Cesarean section during childbirth carries risks for the mother and the newborn child [1]. Instances of cauda equina syndrome caused by arachnoiditis during cesarean section are infrequent complications recorded in global literature [5-7]. In this report, we illustrate the occurrence of cauda equina syndrome in a 31-year-old pregnant woman who underwent combined spinal-epidural anesthesia for her cesarean section utilizing levobupivacaine.

Case Description

A fully healthy woman 31 years old, 66 kg, 169 cm high, and with BMI = 23.1 was introduced to the hospital for a scheduled cesarean section on the 38th week of her pregnancy. She didn't mention any history of back pain, allergies, and neurological pathologies. The patient followed combined spinal-epidural anesthesia with 2.5ml levobupivacaine with the use of Tuohy epidural needle 18 G, and

Quincke spinal needle 26 G in the intervertebral space L3-L4 for the cesarean section. While the anesthesia was in progress, the patient experienced a drop in blood pressure, numbness in the upper limbs, difficulty breathing, and dysphagia. Then, the symptoms completely subsided with the administration of oxygen and ephedrine and placing the patient in a semi-flower position with the use of an oxygen mask. The cesarean section was completed without any gynecological complications. However, after the end of the surgery, the patient developed an episode of diplopia which disappeared immediately.

Also, the patient developed monoparesis accompanied by complete anesthesia in the right lower limb and anesthesia in the region of the genital organs like a saddle, mainly on the right side. The day after the surgery, computed tomography (CT) of the lumbar and thoracic spine was performed to rule out the possibility of an epidural hematoma in which no hematoma or any other pathology was found. Also, the patient was treated with hydrocortisone sodium succinate, which lasted for 5 days. In the neurological examination performed on the same day, a paresis of 1/5 in the central muscles, 4+/5 peripheral hypoesthesia-anesthesia of the right limb including 2/3 of the buttock was found. The patellar and ankle reflexes right were abolished. On the 5th day after surgery and due to the persistence of symptoms, a non-contrast magnetic resonance tomography (MRI) of the lumbar spine was performed to ensure the mother's ability to breastfeed, in which no abnormal findings were found.

The next day, the patient was transferred to the Neurology Clinic of another hospital with an admission examination: Monoparesis of the lower limb with thigh flexion 2/5, thigh extension 2/5, thigh adduction 2/5, thigh abduction 2/5, tibial flexion 2/5, leg extension 2/5, foot dorsiflexion 3/5, foot plantarflexion 3/5. Also, abolished tendon reflexes in the right lower limb, and the abolition of all kinds of sensibility in the right lower limb from the rhizomerium as well as in the genitals with saddle distribution on the ipsilateral. The patient reported no urge to urinate or defecate or urine-fecal passage. On the same day, a CT scan of the brain was performed, in which no pathological findings were found. In addition, on the same day, the patient was treated with anti-inflammatory drugs with high doses of corticosteroids, receiving a total of 5.5 g of methylprednisolone in 7 days, followed by per os treatment with a gradual reduction. The next day, a cervical, thoracic, and lumbar spine MRI with contrast was performed, which revealed pathological uptake of contrast from the meninges in the

right lateral part of the conus medullaris and at the roots of the cauda equina, indicative of arachnoiditis (Figure 1). No pathological findings were found in the remaining spinal cord.

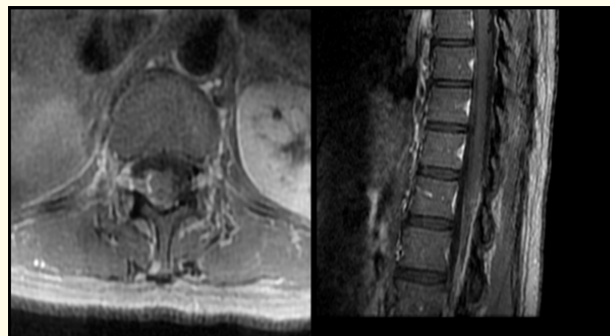


Figure 1: Lumbar spine MRI with contrast showing pathological contrast uptake from the meninges in the right lateral part of the conus medullaris and roots of the cauda equina indicative of arachnoiditis.

During her hospitalization, the patient remained hemodynamically stable and afebrile and followed a physical therapy-kinesiotherapy and psychotherapy program. She had an urinary catheter and defecation was facilitated by enemas. Bowel sounds were present. Concerning her clinical course, during her hospitalization, she showed a mild improvement in the weakness of the limb (antibaric movement) and walking with bilateral support for a few steps. After the closure of the catheter, she reported only a mild pressure sensation in the bladder and the residual with opening was about 300ml. The urinary catheter was removed and anticholinergic medication and four intermittent catheterizations per day were started. Due to reported pain in the left iliac fossa, she was examined by an obstetrician with normal findings of cesarean delivery. A new MRI of the lumbar spine was performed on the 13th postoperative day, one day before discharge from the neurology department, which showed an improvement in the imaging findings with a reduction in pathological contrast uptake from the meninges in the right lateral part of the conus medullaris and from the roots of the cauda equina. However, the imaging findings of arachnoiditis of the cauda equina remained unchanged. The patient was discharged with a recommendation for intensive physiotherapy and kinesiotherapy.

During the follow-up, 1 month after the surgery had a mild clinical improvement as follows; Flexion of the thigh right 4/5, abduc-

tion of the thigh 4/5, adduction of the thigh 3/5, quadriceps 3+/5, flexion of the foot end 3/5, foot-toe extension 4/5. The patellar and ankle reflexes right was abolished eight years after the event. There was numbness of the right lower limb, saddle numbness in the genitals and anus, inability to urinate for which she underwent intermittent catheterizations, and inability to void (assisted voiding enemas). In her current condition, she did not agree to be re-examined. However, she reports that there has been no further improvement in her symptoms since the last follow-up 8 years ago.

Discussion

Cesarean section is an operation with increased risks and should only be performed when there are clear advantages for mother and child [2]. One of the central nerve block techniques used in cesarean sections is the combined spinal and epidural anesthesia [3]. Levobupivacaine is the most commonly used drug in combined spinal-epidural anesthesia and compared to other anesthetics it is less toxic to the heart and central nervous system [4]. However, a case of the possible toxicity of the drug levobupivacaine has been reported in the past, in which a healthy woman after cesarean section with the use of levobupivacaine presented symptoms of cauda equina syndrome which. However, it resolved almost completely after 8 weeks of physical therapy [5]. Also, in another case of cauda equina syndrome after combined spinal-epidural anesthesia with levobupivacaine in a 33-year-old woman, the symptoms had almost completely resolved at a follow-up after 9 months. The patient was treated with methylprednisolone, cyanocobalamin, pyridoxine, thiamine, and pregabalin concurrently with physical therapy [6]. However, a case has been reported where after a case of spinal-epidural anesthesia with bupivacaine and the subsequent appearance of cauda equina syndrome in a 29-year-old woman, despite treatment with high doses of methylprednisolone for a total of 13 days, the patient continued to have a galloping gait on the right two years later [7]. We report a case where a woman who was administered levobupivacaine following spinal-epidural anesthesia developed cauda equina syndrome due to toxic arachnoiditis from the anesthetic and despite treatment with hydrocortisone sodium succinate, methylprednisolone, and physical therapy, the patient's symptoms did not completely resolve but there was a slight improvement. Cauda equina syndrome is a rare condition that most commonly presents with low back pain, bladder and bowel dysfunction, motor weakness of the lower extremities, and saddle anesthesia. The most common causes of cauda equina syndrome are disc herniation (60.9%), degenerative (8.2%), tumor (5.5%), postoperative complications (2.7%), and other causes (4.5%) [8].

In the case of our patient, direct damage to the spinal cord, conus medullaris, cauda equina, and spinal roots from the puncture does not seem likely due to the absence of pain or dysesthesia at the time of needle insertion and due to the involvement of multiple roots in the patient's symptoms. The patient also had no clinical or laboratory evidence of infection. The possibility that the cauda equina syndrome was caused by a herniated disc, a tumor, or any other damage to the spinal cord was ruled out by performing thoracic and lumbar spine CT scans at the first postoperative day and brain, cervical, thoracic, and lumbar spine MRIs performed during the course. Finally, systemic toxicity from local anesthetics (different from neurotoxicity from local anesthetics) due to intravascular infusion of the drug was ruled out both due to the appropriateness of the dosage (2.5ml levobupivacaine) and the absence of an accompanying clinical picture with severe central nervous system toxicity and severe cardiotoxicity. It is possible in our patient that her symptomatology resulted from toxic damage of the anesthetic administered (levobupivacaine) to the arachnoid meninge that surrounds the conus medullaris, the cauda equina and the spinal roots as result of causing the clinical symptomatology, i.e., weakness and numbness of the right lower limb, inability to urinate and saddle hypoesthesia in the genital area.

In terms of patient management, corticosteroids are recognized to possess neuroprotective and anti-inflammatory effects and facilitate neuronal excitability, impulse conduction, and inhibition of lipid peroxidase and inflammation [9]. However, there is a great debate in the literature on the use of methylprednisolone in acute spinal cord injury as recent meta-analyses show that the administration of methylprednisolone does not cause a significant increase in mobility and the overall neurological score of the patients who received it, while at the same time, there is a report of an increased risk of adverse events such as hyperglycemia and pneumonia [10,11]. In our case, despite the diagnosis of acute damage due to toxic arachnoiditis, the initiation of a rehabilitation program with physical therapy, and the administration of sodium hydrocortisone from the first postoperative day and methylprednisolone from the fifth day, the patient did not show a significant improvement in her symptoms, nor no adverse effects from the use of methylprednisolone.

Conclusions

In summary, the syndrome that arises after levobupivacaine administration is believed to stem from neurotoxicity caused by an individual's atypical response to the local anesthetic. Consequently,

resorting to physical therapy, specifically kinesiotherapy, and employing methylprednisolone may not be absolutely effective in aiding the patient's recovery, potentially leading to chronic symptoms.

Conflict of Interest

The authors have no conflict of interest to declare.

Bibliography

1. Antoine C and Young BK. "Cesarean section one hundred years 1920-2020: the Good, the Bad and the Ugly". *Journal of Perinatal Medicine* 49.1 (2020): 5-16.
2. Mylonas I and Friese K. "Indications for and Risks of Elective Cesarean Section". *DÄ International - Deutsches Ärzteblatt* 112.29-30 (2015): 489-495.
3. Aragão FF, et al. "Analgésia de parto no neuroeixo: uma revisão da literatura [Neuraxial labor analgesia: a literature review]". *Brazilian Journal of Anesthesiology* 69.3 (2019): 291-298.
4. Cheng Q, et al. "Ropivacaine vs. levobupivacaine: Analgesic effect of combined spinal-epidural anesthesia during childbirth and effects on neonatal Apgar scores, as well as maternal vital signs". *Experimental and Therapeutic Medicine* 18.9 (2019): 2307-2313.
5. Sarifakioglu AB, et al. "Cauda equina syndrome after cesarean section". *American Journal of Physical Medicine and Rehabilitation* 92.2 (2013): 179-182.
6. Marinho S, et al. "Cauda equina syndrome following combined spinal-epidural anesthesia with levobupivacaine for cesarean section". *Revista Española de Anestesiología y Reanimación (Engl Ed)* 68.8 (2021): 484-486.
7. Chen X, et al. "Persistent cauda equina syndrome after cesarean section under combined spinal-epidural anesthesia: a case report". *Journal of Clinical Anesthesiology* 27.6 (2015): 520-523.
8. Mustafa MA, et al. "Definition and surgical timing in cauda equina syndrome-An updated systematic review". *PLoS One* 18.5 (2023): e0285006.
9. Lee BJ and Jeong JH. "Review: Steroid Use in Patients With Acute Spinal Cord Injury and Guideline Update". *Korean Journal of Neurotrauma* 18.1 (2022): 22-30.
10. Sultan I, et al. "The safety and efficacy of steroid treatment for acute spinal cord injury: A Systematic Review and meta-analysis". *Heliyon* 6.2 (2020): e03414.
11. Thomas AX, et al. "Pharmacologic and Acute Management of Spinal Cord Injury in Adults and Children". *Current Treatment Options in Neurology* 24.7 (2022): 285-304.