



## Follicular Fluid Aspiration and Oocyte Retrieval Techniques, Several Flushing, Difficulty Situations Damage Risk to the Cumulus Complex and Complications

Mohamed Zarqaoui<sup>1</sup>, Mustafa Zakaria<sup>2\*</sup>, Nouredine Louanjli<sup>3</sup>,  
Nisrine En-Naciri<sup>4</sup>, Mohamed Ennaji<sup>5</sup>, Malak Jamil<sup>6</sup>, Amal Kabit<sup>5</sup>,  
Saadani Brahim<sup>7</sup> and Boutiche Romaiassa<sup>8</sup>

<sup>1</sup>General Medical Coordinator of IRIFIV Fertility Center, Casablanca, Morocco

<sup>2</sup>Consultant at IRIFIV Fertility Center, Casablanca, Morocco

<sup>3</sup>Head of LABOMAC Laboratory of Clinical Analysis and Assisted Reproductive Technology IRIFIV Center, AFC Center, Casablanca, Morocco

<sup>4</sup>Senior Clinical Embryologist, Laboratory IVF Agadir, Souss-Massa, Morocco

<sup>5</sup>Senior Clinical Embryologist at IRIFIV Fertility Center, Casablanca, Morocco

<sup>6</sup>Clinical Embryologist at IRIFIV Fertility Center, Casablanca, Morocco

<sup>7</sup>General Medical Coordinator of IRIFIV Fertility Center, Casablanca, Morocco

<sup>8</sup>Clinical Embryologist, Laboratory IVF Algeria, Rotaby Fertility Center, Algeria

\*Corresponding Author: Mustafa Zakaria, Consultant at IRIFIV Fertility Center, Casablanca, Morocco.

Received: August 28, 2020

Published: September 28, 2020

© All rights are reserved by Mustafa Zakaria, et al.

### Abstract

In Assisted Reproductive Technology (ART), oocyte retrieval is a vital step. It was initially performed through laparoscopy, which was complex and difficult and of low efficiency. Ultrasound-guided transvaginal oocyte retrieval was safer and more effective; it is presently the standard operation for *in vitro* fertilization (IVF) treatment. Theoretically, oocyte retention is achievable after the initial aspirate due to abnormal development of the follicle or oocyte and human technical factors, and such retention could be overcome by recurrent follicular flushing. Follicular flushing is considered to maximize the number of oocytes retrieved and thereafter to improve the rate of IVF pregnancy. There are a number of factors that can affect egg collection and/or egg damage. These involve variables like pump vacuum flow, velocity, needle bore size and length, follicle pressure and size and collection techniques. Cook Medical Technology, Brisbane, has developed appropriate equipment to study the factors influencing the success of egg collection and the cause of egg trauma.

**Keywords:** Vacuum Profiles in Aspiration System; Damage to the Cumulus; Clinical Aspects of Oocyte Retrieval; Preparation the Success of Oocyte Retrieval; Retrieval Techniques; Follicular Flushing; Difficulties; Complications

### Abbreviations

IVF: *In-Vitro* Fertilization; hCG: Human Chorionic Gonadotrophin; GnRH/FSH: Gonadotrophin Releasing Hormone/Follicle Stimulating Hormone; COH: Controlled Ovarian Hyperstimulation; IVF-ET: *In Vitro* Fertilization and Embryo Transplantation; ICSI: Intracytoplasmic Sperm Injection; 2PN: Two Pronuclei

### Introduction

The initial studies on the maturation of human oocytes *in vitro* were carried out on oocytes which were obtained when ovaries or pieces of ovaries were acquired by laparotomy [1]. By 1970, Steptoe and Edwards had developed a laparoscopic method for aspirating oocytes from their Graafian follicles, with a method that

yielded oocytes from approximately one-third of follicles [2]. Initially, they used a needle and syringe to provide the suction, but later developed an aspiration device, which provided continuous suction, with control being exerted by the assistant's finger on the bypass valve. A similar technique, using a Venturi system activated by a foot-operated "on-off" valve, was utilized by Lopata, *et al* [3]. Following the first few births from *in-vitro* fertilization (IVF) and embryo transfer, attention was focused on the instruments used for oocyte recovery. Equipment, including a variety of needles and regulated aspiration pumps, became commercially available in the early 1980s: for example, a 'Teflon' coated needle was developed that resulted in oocyte collection rates of > 90% [4]. The next major development was the change from laparoscopic to trans-vaginal ultrasound-guided aspiration [5].

### Experimental and physical aspects of oocyte retrieval

Apart from a comparison between manual and mechanical suction on the impact of zonal damage [6], surprisingly little has been reported on oocyte collection theory until the studies carried out by Cook Medical Technology, Brisbane [7]. A variety of variables may impact oocyte collection and/or ovary damage. These include variables like vacuum flow of the pump, velocity, size and length of the needle lumen, follicular pressure and size and collection techniques. Cook Medical Technology, Brisbane, established appropriate equipment for the study of factors affecting the performance of oocyte collection and the cause of oocyte trauma [7]. Velocity and flow rate via the needle and connected lines were determined from the pressure difference seen between collection tube and the needle tip. The velocity and flow rate were underestimated slightly, particularly at the moment when the needle punctured the follicle wall. Studies on bovine follicles were completed.

### Application of vacuum to a follicle

**Vacuum applied to the follicle after needle entry:** When vacuum is applied, the vacuums in the device adjust to stable flow conditions, the period of time depending on the volume of the follicle, the vacuum used and the needle 's capacity. The follicle wall collapses during this process, as the amount of fluid decreases until the follicle collapses completely and blocks the tip of the needle. During the steady state, maximum flow is reached, then slows significantly as the follicle collapses, blocking the tip of the needle. In certain situations, the fluid keeps moving very slowly up the needle, probably because air is drawn into the follicle at the point of the needle 's entry (i.e. the system was not fully closed).

**Deactivated vacuum before leaving the follicle:** Modifications in vacuum and flow happen when the controlled vacuum is stopped while the tip of the needle remains in the follicle, so that the device remains closed (i.e. no air leakage). After the pump is shut off and the pressure in the collection tube returns to ambient pressure, a backflow of fluid into the follicle occurs. The magnitude of the back flow depends on (i) how much air is entering the system and (ii) the collection tube's height above the tip of the needle.

**Activated and deactivated vacuum outside the follicle:** A comparison of flow rates during aspiration of a 15 mm follicle, where activation and deactivation of the vacuum occurs outside the follicle reveals that flow decreases as the follicle drops but there is a sudden rapid flow to the collection tube as the needle is extracted from the follicle. That can help to clear the follicle. This is probably the best technique.

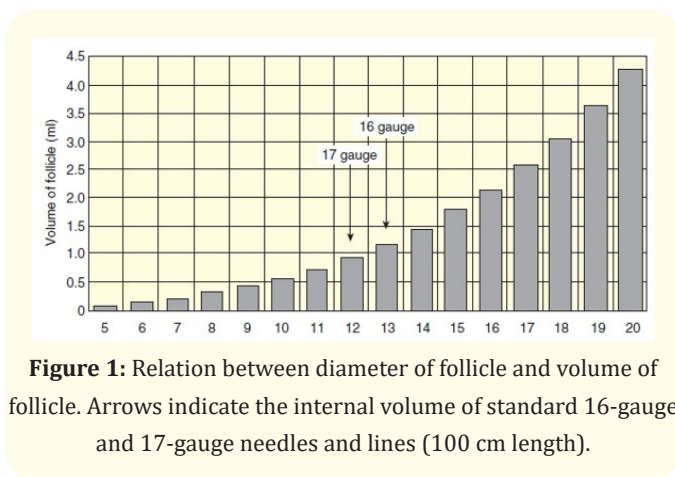
**Damage to oocytes:** The results of flow rates and maximum velocities obtained in the aspiration system using a 17-gauge needle at different vacuums on oocyte cumulus mass morphology indicate that all oocytes lost their cumulus mass after aspiration at 20 kPa (150 mm Hg).

### Vacuum profiles in aspiration system

Generally, for oocyte collection, the vacuum in the collection system is < 20 kPa (150 mm Hg). It is assumed that, using 20 kPa (150 mm Hg), it will take -5s for the system mentioned above to stabilize to the selected vacuum. Large follicles have a small positive pressure 3.75 - 7.5 mm Hg. Follicular pressure depends on the size (and therefore the maturity) of the follicle, its shape and position, with the pressure increasing with the follicular size growing. At the moment of needle penetration, the pressure of the fluid in the follicle may be much higher than the regular follicular pressure. As the needle tip is being pushed into the wall, the deformation of the surface of the follicle will provoke the pressure to rise. The blunter the needle, the higher the pressure (up to 60 mm Hg), and therefore, the greater the volume of fluid that bursts out of the follicle when punctured. Some of this fluid runs through the needle, while the rest flows between the outer needle wall and the follicular wall. If a vacuum has already been implemented before the needle penetrates the follicle, little follicular fluid is lost.

**Follicular and needle volumes:** With a growing interest in extracting oocytes from immature follicles, it is important to remember that such follicles are small in volume (Figure 1). For ex-

ample, an immature follicle with a diameter of 5 mm has a volume of ~0.065 ml. It would end up taking the contents of over 17 such follicles to fill the lumen of a standard 16-gauge needle and line (total length 100 cm).



**Application of vacuum:** Once the follicle is perforated by a needle, the pressure between the follicle and the needle balance out. The follicular wall will usually allow a tentative seal around the needle and resistance inside the needle will put the fluid to rest, in the absence of an applied vacuum. As the operated vacuum is applied, the vacuums appear to balance out to stable flow conditions in the system. In the preceding case, where there is a strong seal around the tip of the needle, if the regulated vacuum is stopped when the tip of the needle is still in the follicle, a backflow of fluid toward the follicle occurs. The magnitude of the reverse flow in this closed system is identical to the maximum flow towards the collection tube but only remains for a couple of seconds and slows quickly. If the needle is removed from the follicle while the vacuum is still being applied, a sudden fluid rush into the collection tube occurs. The tip of the needle goes from follicle’s high vacuum to atmospheric pressure. If the oocyte is contained in the last fraction of the collected follicular fluid or originates from an immature follicle where the volume is small, it may be subject to speeds well above those predicted. It can also be subjected to greater turbulence in both the needle and collection tube.

**Damage within the needle/vacuum lines:** The collection system has a vacuum gradient, with the vacuum at the tip of the needle being just 5% of the vacuum selected at the vacuum pump. The ovum therefore is subjected to an ever-increasing vacuum

throughout its travel along the collection system. This increased vacuum can cause swelling of the ovum, and cracking of the zona. The oocyte cumulus can be stripped by high velocities. Even in laminar flow, there will be a notable change between the velocity of the fluid in the middle of the needle and that towards the periphery. Thereby, the outer layers of the cumulus may be exposed to “drag”, which may strip them. The longer the needle, or the smaller its internal diameter, the greater the vacuum needed to preserve the same velocity and the higher the risk of oocyte damage. If there is turbulent flow, the ovum may be tossed about, which could lead in either stripping off the cumulus or cracking the zona.

**Damage within the follicle:** The ovum has to be accelerated from a resting state within the follicle to the velocity of the fluid within the needle. Besides that, it has to accelerate to this velocity as it reaches the needle tip. This rapid acceleration could strip the cumulus off. In theory, this harmful effect should be highest in smaller follicles, particularly immature follicles, where oocyte adhesion can occur, requiring the use of higher suction vacuums. In addition, as the follicle collapses, the oocyte will be brought closer to the tip of the needle. This implies that if it is separated from the wall, it will be exposed to a growing accelerative force. This may cause the cumulus to tear off from the oocyte. In addition, there is a rapid increase in vacuum at the needle tip, which may also affect the oocyte.

**Damage to the cumulus:** The findings above suggest an intact cumulus may be a significant factor in oocyte resistance to damage. The cumulus morphology is not altered after *in-vitro* aspiration at vacuums and velocities above those usually used *in vivo*, providing the cumulus is usual, compact and refractive. The cumulus is less resistant in cases of damage or degeneration.

The above results illustrate two significant issues concerning the collection of oocytes. Firstly, maintenance of suction: follicular fluid (and oocytes) may be lost if entry into and exit from the follicle are made in the absence of suction. This gain, even so, may be offset by possible damage due to the dramatic forward flow of fluid toward the collection tube. Secondly, the needle tip movement inside the follicle: oocyte damage, particularly cumulus damage, can happen due to collection technique. It is common practice to ‘spin’ the needle inside the follicle during oocyte collection. Significant damage may occur as the oocyte is ‘scraped’ from the follicular wall by the edge of the needle, especially in small follicles or in the col-

lapsed follicle, where the needle size becomes large compared to the volume of follicles. There is a necessity to conduct further studies on the impact of needle movement in follicles on oocyte quality and subsequent blastocyst development. But one potential alternative may be to combine follicle flushing with lower suction vacuums.

### Clinical aspects of oocyte retrieval

**Timing of oocyte retrieval:** The development of the ovarian follicles is tracked by vaginal ultrasound scanning of the ovaries and measurement of serum estradiol. The clinical conditions for administration of human chorionic gonadotrophin (hCG) can differ with protocol of stimulation. For example, in gonadotrophin releasing hormone/follicle stimulating hormone (GnRH/FSH) stimulated cycles, a cohort of at least 3 follicles with a diameter of more than 17 mm is needed. Moreover, the concentrations of serum estradiol should be approximately 800 to 1000 pmol/L per follicle. For natural cycles, on the other hand, one mature follicle is all that can be anticipated. When the conditions are met, the final maturation of the oocytes is launched by an intramuscular injection of hCG (5,000 to 10,000 IU) to mimic the endogenous LH surge. The oocytes are required to ovulate approximately 37h later after administration of hCG. Retrieval of oocytes is scheduled to precede ovulation, approximately 34 to 36h after injection of hCG. Cytoplasmic changes in the oocyte occur during this time, and meiosis is resumed. The intercellular cytoplasmic connections between both the granulosa cells and the oocyte are stopped. The cortical granules, vesicles synthesized by the Golgi-apparatus, eventually move towards the oolemma. The prophase of the first meiotic division is resumed and the oocyte progresses to the metaphase of the second meiotic division at which stage it becomes arrested for the second time. During this process the nuclear envelope has broken down and the first polar body has been expelled.

**Oocyte pick-up technique anesthesia:** Analgesia and anaesthesia use differs across countries and in various patients. Light anesthesia is most appropriate because the patient is unconscious, has no memory of the operation, wakes up within 5 minutes of completing the oocyte collection and will return home within 1 - 2 hours. It requires preoperative counseling and physical examination. Since it is a low risk routine surgical procedure tests were occasionally skipped. If there is an upper respiratory infection or a fever of unknown origin is apparent, the operation should be cancelled or done under local anaesthesia. The degree of anaesthesia

can vary depending on the procedure (transvaginal or laparoscopic) and the particular patient requests. For transvaginal procedures pain relief may be procured with a paracervical block (e.g. xylocaine or mepivacaine) or mild sedation (diazepam I m or iv) in conjunction with opioid analgesics (pethidine hydrochloride). Spinal or general anaesthesia can also be used. One anaesthetic protocol is outlined in figure 2.

*Fentanyl*  
1–2 g/kg iv (average dose 100 g)

*Midazolam*  
0.05–0.1 mg/kg iv (average dose 2–5 mg)

*If required, add Propofol*  
1–2 mg/kg

Monitor oxygen saturation and administer oxygen as indicated

PREPARATION

The success of oocyte retrieval is dependent on good visualization, accessibility of both ovaries, and on the materials and methods used for the oocyte collection.

Pretreatment diagnostic laparoscopy will reveal difficult vaginal access to one or both ovaries and should be corrected prior to controlled ovarian hyperstimulation. When confronted with inoperable pelvic adhesions the feasibility of transvaginal retrieval is assessed by transvaginal ultrasound. Occasionally it may be necessary to perform laparoscopic oocyte pickup because the ovaries are adherent high on the lateral pelvic sidewall.

**Figure 2:** Anaesthetic protocol of IVF procedures.

An excellent degree of relaxation is obtained allowing for a quick and safe procedure, and immediate recovery at conclusion of the operation. On average, the oocyte retrieval takes no longer than 10 minutes minimizing the exposure of the oocytes to the anaesthetic agents. These pharmaceutical agents accumulate rapidly in follicular fluid during the procedure [8]. There is little evidence that sedative and anaesthetic agents have an adverse effect on the postconceptional development of the exposed human oocyte [9]. Even though the concentrations of these drugs in the follicular fluid are much lower than their serum concentrations, it is advisable to reduce the procedure time to a minimum.

**Preparation:** The quality of oocyte recovery depends on good visualization, accessibility of both ovaries, and the materials and methods used to collect the oocytes. Diagnostic laparoscopy pretreatment can show difficult vaginal access to either or both ova-

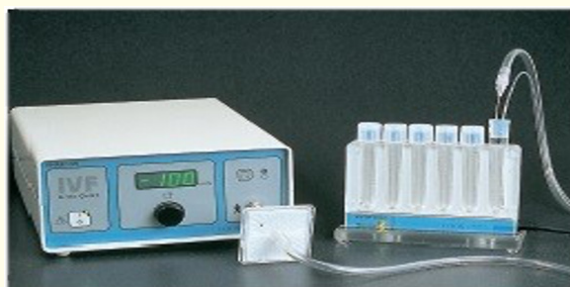

ries, which should be corrected before ovarian hyperstimulation is controlled. When confronted with inoperable pelvic adhesions the feasibility of transvaginal retrieval is assessed by transvaginal ultrasound. Occasionally, laparoscopic oocyte pick-up may be required because the ovaries adhere high on the lateral pelvic side-wall.

**Materials checklist for transvaginal oocyte retrieval**



**Figure 3:** (Left) K-MAR-5100B aspiration unit (Cook IVF).



**Figure 4:** (Right) K-FTH 1012 Falcon tube heater and connecting tubing (Cook IVF).



**Figure 5:** (Left) Needle showing echo tipping to obtain a bright image on ultrasound (Coo IVF).



**Figure 6:** (Centre) Needle with different bevels (Cook IVF).

Most of the materials in this list are preheated in a heating box at 37°C, except for the dry heater component. The heating stage with thermostat control is placed on a trolley which is covered with a sterile drape immediately before the operation. Set at 37°C, the heating stage is protected by a transparent plastic drape to reduce interaction with textile fibres. The “warm blocks” with the test tubes, glass syringe, and glass beaker are placed in the heating stage. The thermometer is placed in one of the test tubes filled with handling medium and the temperature is verified and adjusted. The glass syringe and beaker are filled with handling medium and kept ready for flushing, remaining in the warm blocks at all times. Glass syringes are also used to prevent potential toxicity associated with silicone lubricants and rubber plungers. Automated pumps make the flushing procedure easier. These pumps also offer predetermined flushing volumes and injection rates. The aspirating needle can be either a single or double lumen needle. The double lumen needle is helpful when requiring multiple follicle flushes (e.g. natural IVF cycle). It must be noted that the dead space volume of the single lumen needle and its tubing are approximately 1 mL and the oocyte might therefore move backward and forward within this dead space during aspiration and flushing. The design of the double lumen needle removes this problem since the aspirating channel and the flushing channel are separated, guaranteeing a unidirectional flow in the aspirating channel. Prior to use, the aspiration needle and its Teflon tubing are flushed thoroughly with heparinized handling medium. To prevent unnecessary oocyte cooling, the length of the Teflon tubing between the needle and the collecting test tube should be minimized. A pedal-operated suction pump with vacuum regulator is used. A wide range of different models are now available. The maximum aspiration pressure is set at approximately -15 kPa or -125 mmHg.

## Retrieval techniques

### Laparoscopic oocyte retrieval

This technique can also be suggested when the ovaries cannot be reached with the trans-vaginal method due either to their elevated position in the pelvis or behind an enlarged uterus, or when the ovaries are too mobile to make the trans-vaginal technique difficult or dangerous. This procedure necessitates general anaesthesia and endotracheal intubation, which is a major disadvantage. The ovary is immobilized by maintaining it with grasping forceps in the utero-ovarian ligament. Retrieval of laparoscopic oocytes is only feasible when part of the ovarian cortex is exposed and follicles are visible on the surface. After the follicles are established, they are punctured with the aspiration needle, which has been flushed previously with heparinized flushing medium. The needle should be placed where the follicular wall is slightly thicker, to avoid the follicle wall from tearing and breaking the seal around the needle. While the needle is still in the follicle, the aspirate in the collecting tube is given to the embryologist and verified for the presence of an oocyte. When no oocyte is found, the follicle may be gently flushed until the oocyte is retrieved. The procedure is repeated until all accessible oocytes are aspirated. Ultrasound-Guided Retrieval In our centre an Accuson 128 with a 7.5 MHz transvaginal probe is used for all transvaginal oocyte retrievals. After applying the conducting jelly to the tip of the transducer, the transvaginal probe is covered with a latex probe cover. Care is required to correctly aim the needle guide onto the probe. Regular checks are important to the safety of the operation to ensure that the indicator line on the imaging screen actually corresponds with the path of the aspirating needle. The needle tip is specially treated to improve echogenicity and pops up as a bright spot on the monitor. They should follow the indicator line throughout the operation. If a lot of lateral tension is exerted on the needle, it can bend, and the tip of the needle can leave the indicator line's path. In such cases, the needle can be removed and the curvature can be manually corrected, or better still, the needle can be substituted. On the imaging panel, the ovaries are localized and aligned with the indicator line. The follicle nearest to the probe is entered with a short, controlled stabbing motion. A more gradual drilling motion can be suggested when follicles are situated in the vicinity of major pelvic blood vessels or bowel loops at the posterior side of the ovary. The needle tip is held in the follicle center while the follicle wall collapses around it. The operator should ensure full emptying of the follicle. Rotating the needle around the longitudinal axis may help remove tiny follicular fluid pickets. When the follicle is aspirated, the follicular fluid is imme-

diately sent to the embryologist. The distance between the patient and the embryology lab should be minimal to minimize detrimental effects of temperature variations on the oocytes. Alternatively, the oocytes should be stored in warm blocks with the collecting tubes. When follicles are flushed, the assistant injects the pre-warmed heparinized carrying medium through the Teflon tubing. The amount injected depends on the follicle size; this should not surpass the volume of the aspirated follicular fluid to avoid rupture of the follicle. The operator will examine follicle filling while the medium is being injected. In many cases only one puncture through the ovarian capsule is needed to aspirate all or most follicles: this greatly reduces the risk of postoperative haemoperitoneum. Many follicles may be aligned in the path of the needle to minimize the number of puncture wounds in the ovary. When all follicles in one ovary are aspirated, the needle is withdrawn and flushed by holding the needle tip in a test tube filled with heparinized handling medium. The vaginal vault is then punctured a second time in order to enter the contralateral ovary, and the process is repeated. When all follicles in both ovaries have been aspirated, Douglas' pouch is inspected for any accumulation of fluids. Fluid is trans-vaginally aspirated and tested at the time of puncture by the embryologist for the presence of spontaneously-ovulated oocytes or oocytes missing. When the pelvic aspirate comprises mainly blood, this routine also aims to minimize postoperative pain triggered by peritoneal irritation. After the needle is removed, it is flushed once more. We need to verify all needle flushes for oocytes. The vaginal vault is swabbed, and any bleeding is examined. After each retrieval the transvaginal probe is cleaned with warm soapy water, rinsed and dried. It is then soaked in 0.5% aqueous chlorhexidine for 10 minutes. Ovarian endometriomas are usually visible on ultrasound when follicles are more than 15 mm in diameter but may only be detected in smaller follicles when the follicular aspirate reveals chocolate colored fluid. Similar fluid may sometimes be found in a hemorrhagic corpus luteum. The fluid aspirate may be embryotoxic and thorough washing of the needle and aspirating system should be carried out before another follicle is aspirated. If cleansing is difficult a new needle and aspirating set is used. If large endometriomas are aspirated at the time of egg pick-up, an intravenous antibiotic is given to prevent the risk of pelvic infection which may occur secondary to chemical peritonitis resulting from peritoneal spill of endometriotic fluid. When the needle is in or close to the ovary, blood may be aspirated with follicular fluid. This may result from prior bleeding inside the follicle, which can be recognized by a speckled appearance on ultrasound, or by bleed-

ing commencing after the needle punctures the wall of the follicle. Bleeding caused by a needle puncture is less likely to occur with a sharp (new) needle and to penetrate the follicle at right angles to the follicle circumference. The follicle wall is less likely to be teared, as is the loss of fluid from the follicle before effective aspiration. The needle should be held in the follicle 's center as contact between the needle and the follicle's inside wall is prevented until the follicle is clear, minimizing trauma, potential bleeding and blood in the aspirate. Often the aspiration needle reveals pure venous or arterial blood, meaning an ovarian artery has reached. The needle should be withdrawn and the needle and aspirating system flushed clean before reuse. Re-entry to the same follicle may be worthwhile when ultrasound indicates bleeding has stopped, and few follicles are available for oocyte retrieval.

### **Follicular flushing**

The value of follicular flushing is debatable [10,11]. Its importance is apparent in cases where there is a low number of follicles, such as in patients on a natural or limited stimulation (Clomid only) IVF cycle or in weak responders for controlled ovarian hyperstimulation. However, the effects of flushing are less evident when more than 10 follicles have been recruited during controlled ovarian hyperstimulation. Flushing all follicles thoroughly prolongs the operation, increasing the discomfort of the patient and increasing the total cost of the procedure [12]. Up to six times flushing all follicles will increase yield by 20%. The time factor can be reduced by flushing all follicles only once. Interestingly, in the first aspirate and in the dead space of the needle and its tubing, similar proportions of oocytes were detected, suggesting that the cumulus-oocyte complex is often aspirated when the follicle nearly collapses completely [12]. This illustrates the importance of aspirating the complete content of the follicle. Both heparinized culture medium and heparinized normal saline can be utilized for follicular flushing. A recent randomized study [13] showed that heparinized normal saline is an equally good, but cheaper, and more convenient medium than standard heparinized culture medium and could be replaced by flushing follicles for IVF-ET procedures during oocyte recovery.

### **Important points**

Clean vagina of particulate matters before needle entry, as it reduces contamination of needle and vaginal bacterial count. Vaginal ultrasound aimed at boosting the size of each follicle, allowing the needle to reach the follicle center. Enter the follicle at its maximum diameter. Aspiration, to avoid leakage, began before entering the follicle. Avoid excess aspiration pressure as cumulus may be torn

from oocyte. Flush follicles at low pressure: Flush aspirating system after the first follicle is drained to remove vaginal mucous or tissue. An empty follicle is defined by (a) several ultrasound views and (b) observation of aspiration of the tube. Aspiration is easier if the ovary is fixed by firm manual pressure with one hand-reduces rotation of the ovary. Operator watches both ultrasound picture and tubal aspirate to control ultrasound probe movement within follicle.

### **Difficulties**

Transuterine needle puncture - minimize distance by manipulation of uterus or pressure on ovary - needle may bend or break. Endometriosis fluid may be embryotoxic - leave endometriomas alone or aspirate endometriomas and flush cyst and needle repeatedly to clean. Bleeding - ovarian vessels, remove needle, bleeding stops: (A) Iliac vein remove needle gently, if rapid bleeding perform laparotomy. (B) Vaginal bleeding apply pressure for 2 minutes; if bleeding continue suture. Infection - I.V. antibiotics if vaginal or cervical infection, pelvic infection in past history, bowel or pelvic adhesions.

### **Complications**

The ultrasound-guided transvaginal technique is a very efficient and simple procedure. However, this should not distract from the fact that a number of potentially dangerous complications exist, consisting mainly of hemorrhage, trauma to pelvic anatomical structures, and infection [14].

### **Discussion**

*In vitro* fertilization and embryo transfer refer to the process that induces follicular development during the natural cycle or by administration of gonadotropin, and then extracts the mature ovum from the ovary for *in vitro* embryo culture and embryo transplantation [15-18]. The first step of IVF-ET is to aspirate the matured oocytes from the ovary [19,20]. However, on the day of collecting oocytes some patients can experience difficulties. Some can reveal failed oocyte extraction, with no transplant embryo as a consequence [21]. Others, after repeated flushing, could procure oocytes but a limited number of embryos appropriate for transplantation [15]. This research retroactively analyzed 133 cases that encountered hardship on the day of oocyte collection, assessed the number of oocytes retrieved, the development of embryos, clinical and neonatal outcomes. It is commonly accepted that the ovum will only get even worse when treated *in vitro* [22,23]. Many variables, like air quality, light, pH, and also *in vitro* operation, can cause a

reduction in oocytes quality. Also, important factors influencing the oocyte quality are the time taken for oocyte recovery and the difficulty for ovum retrieval [24,25]. The current research involved patients experiencing retrieval difficulty on the 2017 oocyte collection day, as well as those with good oocyte retrieval (control group), comparing embryo development, clinical pregnancy outcome and neonatal outcomes between the two groups. In patients with different methods of fertilization, we have also compared embryo development to examine whether the oocyte recovery process may affect the quality of the oocytes and embryo development potential. In situations obtaining IVF, the difficulty group demonstrated decreased rates of 2PN fertilization and day 5 blastocyst utilization compared with controls. In cases obtaining ICSI, the difficulty group demonstrated reduced number of MII stage oocytes, lower rates of day 3 good quality embryo and day 5 blastocyst utilization. Good embryo quality is necessary for successful embryo implantation in *in vitro* fertilization [26,27]. So, improving the number of retrieved oocytes is an effective approach to improve the count of high-quality embryos [15,28,29]. During ovum collection, because of various reasons, some patients, may experience retrieval difficulty, and finally receive oocytes after repeated flushing. The excessive flushing pressure, however, can cause the follicular wall to break up early and cause damage to the oocytes. Oocyte damage may often not be detected via the complexes of the cumulus oocyte, although it has already caused some functional changes to the oocytes [30]. As previously mentioned, elevated pressure would induce parthenogenetic activation in the oocyte during ovum retrieval, implying that pressure could alter the physiological functions of the ovum. Moreover, repeated pressure on the oocytes may promote sterile oocyte formation, but the cumulus cells are crucial for *in vitro* maturation, especially cytoplasm maturation in oocytes [31]. Oocytes without cumulus cells have minimal developmental potential after fertilization despite nuclear maturation, since cytoplasm maturation was greatly affected. These embryos develop hardly into blastocysts, resulting in very low clinical pregnancy rate [18,32]. On the other hand, oocytes retrieval difficulty may imply that the patient seems to have more abnormal oocytes than the control group, some abnormal oocytes may represent genetic abnormalities and the development potential of these oocytes were reduced [33]. As seen in this article, the difficulty group had drastically decreased oocyte utilization rate compared with controls. The retrieval difficulty group reported reduced embryo implantation, cycles having embryos to transfer and clinical pregnancy rates compared with controls. It would be great to know the cumulative delivery rate

across all transfers per initiated cycle to evaluate the overall quality of the oocytes retrieved, but not all the patients having their frozen embryo transfer until now. So, we did not demonstrate this result in this study. Overall, in patients having retrieval difficulty, how to increase the number of oocytes collected and particularly increase the quality of the oocytes shall remain a challenge worth more pervasive investigation.

## Conclusion

High-quality ovum is the essential and primary necessity in assisted reproduction for successful IVF [29]. Increasing the number of oocytes retrieved is an excellent method to boost the number of embryos that can be transplanted or also of high quality. Repeated flushing and prolonged time needed for oocyte recovery during the process of oocyte retrieval, drastically decreased oocyte and embryo development potential.

## Bibliography

1. Edwards RG. "Maturation *In Vitro* of Human Ovarian Oocytes". *The Lancet* 286.7419 (1965): 926-929.
2. Steptoe PC and Edwards RG. "Laparoscopic recovering of pre-ovulatory human oocytes after priming of ovaries with gonadotrophins". *Lancet* (1970): 683-689.
3. Lopata A., et al. "Collection of human oocytes at laparoscopy and laparotomy". *Fertility and Sterility* 25 (1974): 1030.
4. Renou P., et al. "The collection of human oocytes for *in vitro* fertilization. I. An instrument for maximising oocyte recovering rate". *Fertility and Sterility* 35 (1981): 409-412.
5. Feichtinger W and Kemeter P. "Transvaginal sector scansonography for needle guided transvaginal follicle aspiration and other applications in gynecologic routine and research". *Fertility and Sterility* 45 (1986): 722-725.
6. Cohen J., et al. "Follicular aspiration using a syringe suction system may damage zona pellucida". *Journal of In Vitro Fertilization and Embryo Transfer* 4 (1986): 224-226.
7. Horne R., et al. "Aspiration of oocytes for *In vitro* fertilization". *Human Reproduction Update* 2 (1996): 77-85.
8. Soussis I., et al. "Follicular fluid levels of midazolam, fentanyl and alfentanil during transvaginal oocyte retrieval". *Fertility and Sterility* 64 (1995): 1003.



9. Coetsier T., *et al.* "Propofol anaesthesia for ultrasound guided oocyte retrieval: accumulation of the anaesthetic agent in follicular fluid". *Human Reproduction* 7 (1992): 1422.
10. Waterstone JJ and Parsons JH. "A prospective study to investigate the value of flushing follicles during transvaginal ultrasound-directed follicle aspiration". *Fertility and Sterility* 57.1 (1992): 221-223.
11. Tan SL., *et al.* "A prospective randomized study comparing aspiration only with aspiration and flushing for transvaginal ultrasound-directed oocyte recovery". *Fertility and Sterility* 58 (1992): 356-360.
12. El Hussein E., *et al.* "A prospective study comparing the outcome of oocytes retrieved in the aspirate with those retrieved in the flush during transvaginal ultrasound directed oocyte recovery for *In vitro* fertilization". *British Journal of Obstetrics and Gynaecology* 99 (1992): 841.
13. Biljan MM., *et al.* "Prospective randomized trial of the effect of two flushing media on oocyte collection and fertilization rates after *in vitro* fertilization". *Fertility and Sterility* 68 (1997): 1132-1134.
14. Bennett S.J., *et al.* "Complications of transvaginal ultrasound-directed follicle aspiration: A review of 2670 consecutive procedures". *The Journal of Assisted Reproduction and Genetics* 10 (1993): 72.
15. Ho JR and Paulson RJ. "Modified natural cycle in *In vitro* fertilization". *Fertility and Sterility* 108.4 (2017): 572-576.
16. Simoni MK., *et al.* "Women's career priority is associated with attitudes towards family planning and ethical acceptance of reproductive technologies". *Human Reproduction* 32.10 (2017): 2069-2075.
17. Chambers GM., *et al.* "Assisted reproductive technology in Australia and New Zealand: cumulative live birth rates as measures of success". *Medical Journal of Australia* 207.3 (2017): 114-118.
18. Haas J., *et al.* "Coadministration of GnRH-agonist and hCG for final oocyte maturation(double trigger) in patients with low number of oocytes retrieved per number of preovulatory follicles--a preliminary report". *Journal of Ovarian Research* 7 (2014): 77.
19. Awonuga A., *et al.* "A prospective randomized study comparing needles of different diameters for transvaginal ultrasound-directed follicle aspiration". *Fertility and Sterility* 65.1 (1996): 109-113.
20. Stanger JD and Yovich JL. "Follicle recruitment determines IVF productivity rate via the number of embryos frozen and subsequent transfers". *Reproduction Biomedicine Online* 27.3 (2013): 286-296.
21. Nakamura M., *et al.* "Analyzing the risk factors for a diminished oocyte retrieval rate under controlled ovarian stimulation". *Reproductive Medicine and Biology* 16.1 (2017): 40-44.
22. Palmsten K., *et al.* "*In vitro* fertilization, interpregnancy interval, and risk of adverse perinatal outcomes". *Fertility and Sterility* 109.5 (2018): 840-848.
23. James E and Jenkins TG. "Epigenetics, infertility, and cancer: future directions". *Fertility and Sterility* 109.1 (2018): 27-32.
24. Calhaz-Jorge C., *et al.* "Assisted reproductive technology in Europe, 2013: results generated from European registers by ES-HRE". *Human Reproduction* 32.10 (2017): 1957-1973.
25. Cai Q., *et al.* "Does the number of oocytes retrieved influence pregnancy after fresh embryo transfer?" *PLOS ONE*. 8.2 (2013): e56189.
26. Huo X., *et al.* "Bisphenol-A and Female Infertility: A Possible Role of Gene-Environment Interactions". *International Journal of Environmental Research and Public Health* 12.9 (2015):11101-11116.
27. Ji J., *et al.* "The optimum number of oocytes in IVF treatment: an analysis of 2455 cycles in China". *Human Reproduction* 28.10 (2013): 2728-2734.
28. Magnusson A., *et al.* "The number of oocytes retrieved during IVF: a balance between efficacy and safety". *Human Reproduction* 33.1 (2018): 58-64.
29. Steward RG., *et al.* "Oocyte number as a predictor for ovarian hyperstimulation syndrome and live birth: an analysis of 256,381 *In vitro* fertilization cycles". *Fertility and Sterility* 101.4 (2014): 967-973.
30. Pelinck MJ., *et al.* "Embryo quality and impact of specific embryo characteristics on ongoing implantation in unselected embryos derived from modified natural cycle *In vitro* fertilization". *Fertility and Sterility* 94.2 (2010): 527-534.
31. Artini PG., *et al.* "Cumulus cells surrounding oocytes with high developmental competence exhibit down-regulation of phosphoinositol 1,3 kinase/protein kinase B(PI3K/AKT) signalling genes involved in proliferation and survival". *Human Reproduction* 32.12 (2017): 2474-2484.

32. Ko DS, *et al.* "Pregnancy and fertilization potential of immature oocytes retrieved in intracytoplasmic sperm injection cycles". *Clinical and Experimental Reproductive Medicine* 42.3 (2015):118-125.
33. Rienzi L, *et al.* "The oocyte". *Human Reproduction* 27.S1 (2012): i2-i21.

**Assets from publication with us**

- Prompt Acknowledgement after receiving the article
- Thorough Double blinded peer review
- Rapid Publication
- Issue of Publication Certificate
- High visibility of your Published work

**Website:** [www.actascientific.com/](http://www.actascientific.com/)

**Submit Article:** [www.actascientific.com/submission.php](http://www.actascientific.com/submission.php)

**Email us:** [editor@actascientific.com](mailto:editor@actascientific.com)

**Contact us:** +91 9182824667