



Imaging Techniques in the Diagnosis of Gastric Problems in Special Context to Gastritis: Mini Review

Hamid Shah^{1*}, Burhan Nabi², Sanober Rasool³ and Peerzada Rouf Ahmed⁴

¹Crown Vet Hospital, Lajpat Nagar, Delhi, India

²Division of Veterinary Medicine, Faculty of Veterinary Sciences and Animal Husbandry, Sher-e-Kashmir University of Agricultural Sciences and Technology, Jammu, India

³Division of Veterinary and Animal Husbandry Extension, Faculty of Veterinary Sciences and Animal Husbandry, Sher-i-Kashmir University of Agricultural Sciences and Technology, Kashmir, India

⁴Division of Veterinary Public Health and Epidemiology, Faculty of Veterinary Sciences and Animal Husbandry, Sher-e-Kashmir University of Agricultural Sciences and Technology, Jammu, India

*Corresponding Author: Hamid Shah, Crown Vet Hospital, Lajpat Nagar, Delhi, India.

Received: February 14, 2022

Published:

© All rights are reserved by **Hamid Shah, et al.**

Abstract

Gastric mucosal injury is very common in veterinary patients because of injudicious use of drugs which can hamper the normal mucosal defense mechanism, among such injuries gastritis is a common issue encountered in routine small animal practice. Over centuries several approaches have been used to diagnose the gastric disorders and among those radiography imaging techniques are supporting diagnostic steps which are needed to determine diagnosis towards a case. So this paper gives a brief importance of those imaging techniques in various gastric problems especially gastritis and associated limitations.

Keywords: Diagnostic; Gastritis; Injudicious; Mucosal; Radiography

Introduction

The term "gastritis" was first used by Georg Ernst Stahl in order to define the inflammation of inner lining of the stomach. In the past many considered it a useful histological finding, but not a disease. Gastric mucosal injury is very common in veterinary patients because of injudicious use of drugs which can hamper the normal mucosal defense mechanism. Gastritis is defined as the inflammation of gastric mucosa which occurs as a result of loss of integrity of gastric mucosal barrier resulting in increased permeability, erosions and in some cases ulcerations of the mucosa [19]. Several approaches can be used in the diagnosis of gastric disorders such as signalment, anamneses, clinical signs, and physical examination and hematology and blood chemistry, radiography imaging diagnosis are supporting diagnostic steps which are needed to determine diagnosis towards a case such as radiography, ultrasonography and endoscopy [25]. For determining the possible origin

of abdominal disturbances (gastric foreign bodies) the plain and contrast radiographs are useful but may be unsatisfactory in smart verification of gastric ulceration [7]. Radiographic survey is less sensitive than ultrasonography for identification of gastric lesions such as gastric ulcer and gastritis in dogs [17]. Abdominal ultrasonography provides a valuable information that helps in the definitive diagnosis or curtail the list of differential diagnosis obtained with other diagnostic techniques [5]. Ultrasound is a noninvasive imaging technique which provides real time data of functions of abdominal organs [15]. Ultrasound can be used to examine gastric emptying, antral contractibility, transpyloric flow, gastric configuration and accommodation, and strain measurement of the gastric wall. Furthermore, it can also be used to detect foreign bodies and masses, gastrointestinal perforation, and drug-induced gastric mucosal changes [3]. Ultrasonographic examination of the GI tract is often challenged by the presence of gas in the stomach, to over-

come that endoscopy is a minimally invasive technique which acts as a diagnostic and as well as therapeutic tool. It can be used to see mucosa of the digestive tract when radiography and ultrasound imaging cannot confirm diagnosis of such a case. Endoscopic examination is imperative for the diagnosis since it allows for direct stomach mucosal visualization, biopsy collection, prognosis determination, and therapy effects [21].

Radiography as diagnostic aid

Radiography is commonly used diagnostic tool for chronic gastritis associated with foreign body obstructions furthermore plain and contrast radiographs are useful for determining possible origin of abdominal disturbances such as gastric foreign bodies (Figure 1) but may be unsatisfactory for diagnosing gastric ulcers [7,13]. Radiographic examination is effective for diagnosing disease of gastrointestinal tract related to digestive tract motility, however it has limitation in diagnosing hyperemia, erosion and ulcers on digestive tract mucosa [9]. Radiography is beneficial in diagnosing foreign bodies but is unrewarding in determining the evidence of gastric ulceration [18]. The plain radiography is helpful in the detection of radio-opaque foreign bodies viz., granite stone, arachnut, cotton pad, plastic cover, fecoliths, sewing needle and mango kernels [10].

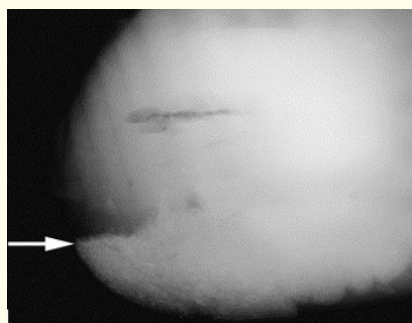


Figure 1: The radiopaque accumulation of sand (arrow) in the sternal flexure of the ventral colon is notable.

Source: (<https://www.ncbi.nlm.nih.gov/pmc/articles/PMC7158198/figure/f1/?report=objectonly>).

Advantage of radiographic investigation can be seen regurgitation and esophagitis due to such as hernias, tumors, foreign bodies (Figure 2), megaesophagus, or vascular ring anomalies which often can be confused with the physiologic or chemical induced ones but for confirmation of the cause of the regurgitation or esophagitis, survey radiographs are needed [12].

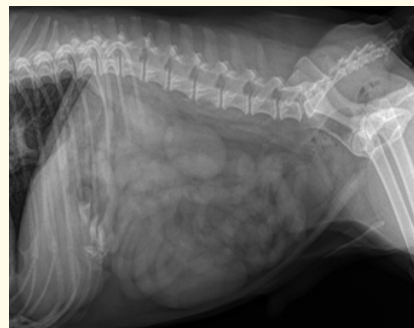

Figure 2: Radiopaque gastric material.

Source: (<https://www.cliniciansbrief.com/article/case-gastroenteritis-or-something-else>).

Various radiographic examination findings in normal stomach wall appears smooth and homogeneous and is a few mm thick on full distention, while in a non-distended stomach, rugal folds are more convoluted, but as distension grows, they become more uniform and parallel to the gastric curve but in case of hypertrophic gastritis in dogs there is loss of serosal detail consistent with increased soft tissue within the lumen of stomach [25,26]. The limitation of radiography in the case of patient's lean body condition or the presence of peritoneal effusion or peritonitis decreases the abdominal serosal details, potentially hindering the ability to identify dilated fluid filled intestinal segments on radiograph [4], there are a number of differential diagnosis for upper gastrointestinal tract disorders that radiography could not confirm such as gastric tumor and gastric outflow obstruction [16] when survey abdominal radiographs are inconclusive for the diagnosis of gastrointestinal mechanical obstruction, as there is lack of significant increase in diagnostic accuracy using follow-up radiographs in cases of occult gastrointestinal mechanical obstruction abdominal ultrasonography should be explored [4].

Ultrasonography in the diagnosis of gastric issues

In case of gastric ulcers there is presence of gastric wall thickening, gastric fluid accumulation, and reduced motility which can be easily detected by ultrasonography and gastritis occurs commonly in the dogs with chronic uremia and ultrasonographic features include moderately thickened gastric wall with prominent rugal folds and a hyperechoic line at the mucosal luminal interface secondary to mineralization of the mucosa [6,22].

Ultrasonography is much more sensitive than radiography for the identification of gastric lesions in different conditions viz., gastric ulcer and gastritis in dogs. On the basis of diagnostic utility scores, abdominal ultrasonography is beneficial for diagnosis of chronic vomiting in 22.5% cases [14]. Ultrasonography can be a very useful complementary imaging technique in cases of gastritis due to radiolucent foreign bodies which are difficult to detect via radiography [1].

Endoscopy as tool for evaluating gastric problems

Endoscopy is the most reliable and cost effective tool for evaluating vomiting in animals with an easy access for direct examination of stomach and for mucosal sample collection [24]. Flexible endoscopy has revolutionized the approach of diagnosis for chronic gastritis. The endoscopic examination includes the assessment of intraluminal contents (fluids, foreign body, bezoars, feces), mucosal conditions such as (color, thickness, ulcers, erosions, tumors), and the wall elasticity as an indicator for intramural changes (tumor and inflammation) (Figure 3 and 4) [23].

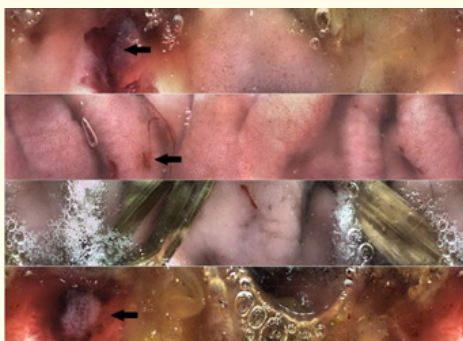


Figure 3: Duodenum ulceration, capsule endoscopy, dog.
Source: msdvetmanual.




Figure 4: Endoscopic view of a large, stomach-filling grass phytobezoar in a Springer Spaniel
Source: (<https://www.vetpracticesupport.com/gastric-phytobezoars-as-a-cause-of-vomiting-in-dogs>).

Endoscopic examination is of great significance for the diagnosis of mucosal lesions by direct visualization of gastric mucosa, biopsy collection, prognosis and therapeutic benefits [21]. Endoscopy can be used to diagnose cases such as esophagitis, stomach ulcer, and chronic gastritis [2].

Endoscopic removal is usually the preferred method of foreign body removal because it is minimally invasive and results in a lower rate of complications, and faster recovery [20] and has been used effectively in retrieval of foreign body without surgical intervention [8].

The plain radiography has limited diagnostic value and contrast radiography is laborious and time-consuming but with higher sensitivity therefore ultrasonography and endoscopy are the most appropriate modalities for diagnosing gastric tumors and for taking adequate biopsies [25]. Therefore, endoscopic characterization of mucosal changes in the upper gastrointestinal (GI) tract is the gold standard that enables visualization of the pit pattern and vascular changes.

Conclusion

Plain radiographic examination is helpful in diagnosing the radiopaque gastric foreign bodies and ultrasonography is a reliable technique in the diagnosis of gastric ulcers and assessing the gastric wall thickness, renal, hepatic, and splenic involvement. Endoscopy acts as a prognostic tool for early evaluation of gastric mucosal lesions and foreign bodies.

Conflict of Interest

The authors declare no conflict of interest.

Bibliography

1. Agthe Petra. "Imaging diagnosis of gastrointestinal foreign bodies in dogs and cats: Part 2". *UK Vet Companion Animal* 16.5 (2011): 19-25.
2. Banerjee Rupa and D Nageshwar Reddy. "Advances in endoscopic imaging: Advantages and limitations". *Journal of Digestive Endoscopy* 3.S 05 (2012): 007-012.
3. Boysen Soren R., et al. "Ultrasonographic findings in dogs and cats with gastrointestinal perforation". *Veterinary Radiology and Ultrasound* 44.5 (2003): 556-564.

4. Elser Emily B., *et al.* "Serial abdominal radiographs do not significantly increase accuracy of diagnosis of gastrointestinal mechanical obstruction due to occult foreign bodies in dogs and cats". *Veterinary Radiology and Ultrasound* 61.4 (2020): 399-408.
5. Gomaa, Mohamed., *et al.* "Ultrasonographic findings of most common surgical disorders of gastrointestinal tract in dogs and cats". *Iranian Journal of Veterinary Surgery* 7.1-2 (2012): 23-38.
6. Grooters AM., *et al.* "Sonographic appearance of uremic gastropathy in four dogs". *Veterinary Radiology and Ultrasound* 35.1 (1994): 35-40.
7. Guarino Alfredo. "Foreword: ESPGHAN/ESPID evidence-based guidelines for the management of acute gastroenteritis in children in Europe". *Journal of Pediatric Gastroenterology and Nutrition* 46 (2008): 7-8.
8. Hall Ed. "Endoscopy of the gastrointestinal tract in dogs and cats". *In Practice* 37.4 (2015): 155-168.
9. Han Eveline. "Diagnosis and management of reflux esophagitis". *Clinical Techniques in Small Animal Practice* 18.4 (2003): 231-238.
10. Jaikumar Vishnu Sunil., *et al.* "Radiography: a tool for the diagnosis of gastrointestinal affections in chronic vomiting dogs". *Indian Journal of Canine Practice* 5.1 (2013): 181.
11. Kleine Lawrence J. "Radiologic examination of the esophagus in dogs and cats". *The Veterinary Clinics of North America* 4.4 (1974): 663-686.
12. Kleine Lawrence J and Christopher R Lamb. "Comparative organ imaging: the gastrointestinal tract". *Veterinary Radiology* 30.3 (1989): 133-141.
13. Leib MS. "Chronic vomiting in dogs and cats: The roles of ultrasonography in diagnosis and *Helicobacter* in treatment. In: Consultations in Feline Internal Medicine". August, J. R (ed.) Philadelphia, W. B. Saunders Company (2005): 403-407.
14. Leib MS., *et al.* "Diagnostic utility of abdominal ultrasonography in dogs with chronic vomiting". *Journal of Veterinary Internal Medicine* 24.4 (2010): 803-808.
15. Malancus RN and CM Malancus. "Assessment of ultrasonographic and endoscopic changes in dogs with gastrointestinal disorders". *Arquivo Brasileiro De Medicina Veterinaria E Zootecnia* 69 (2017): 1451-1455.
16. Noviana Deni., *et al.* "Diagnostic imaging and endoscopy of the schnauzer dog with upper gastrointestinal tract disorders". *Jurnal Kedokteran Hewan-Indonesian Journal of Veterinary Sciences* 11.1 (2017): 1-5.
17. Pal Madan., *et al.* "A comparative study of two-dimensional and three-dimensional ultrasonography in evaluation of gastric affections in dogs". *Veterinary World* 8.6 (2015): 707.
18. Parrah JD., *et al.* "Gastric ulceration in dog: A review". *Veterinary World* 6.7 (2013): 449-454.
19. Rugge Massimo., *et al.* "Gastritis: the histology report". *Digestive and Liver Disease* 43 (2011): S373-S384.
20. Sale Charles SH and John M Williams. "Results of transthoracic esophagotomy retrieval of esophageal foreign body obstructions in dogs: 14 cases (2000-2004)". *Journal of the American Animal Hospital Association* 42.6 (2006): 450-456.
21. Shaheen M., *et al.* "Clinical, endoscopic and therapeutic studies on canine gastritis". *Intas Polivet* 11.2 (2010): 293-296.
22. Smithuis RH and JO Op den Orth. "Gastric fluid detected by sonography in fasting patients: relation to duodenal ulcer disease and gastric-outlet obstruction". *American Journal of Roentgenology* 153.4 (1989): 731-733.
23. Spillmann Thomas. "Esophageal diseases: diagnostic and therapeutic approach". *World Small Animal Veterinary Association Congress* (2007).
24. Tams TR. "A diagnostic approach to vomiting in dogs and cats". *Veterinary Medicine (USA)* 87.8 (1992): 785-793.
25. Terragni R., *et al.* "Diagnostic imaging and endoscopic finding in dogs and cats with gastric tumors: a review". *Schweizer Archiv für Tierheilkunde* 156.12 (2014): 569-576.
26. Vaughn Denty P., *et al.* "Canine giant hypertrophic gastritis treated successfully with partial gastrectomy". *Journal of the American Animal Hospital Association* 50.1 (2014): 62-66.

Assets from publication with us

- Prompt Acknowledgement after receiving the article
- Thorough Double blinded peer review
- Rapid Publication
- Issue of Publication Certificate
- High visibility of your Published work

Website: www.actascientific.com/

Submit Article: www.actascientific.com/submission.php

Email us: editor@actascientific.com

Contact us: +91 9182824667