

## Case Study Manny Ring Worm

**Shaurat Lalwani\***

*K.N.P College of Veterinary Science, UAE*

**\*Corresponding Author:** Shaurat Lalwani, K.N.P College of Veterinary Science, UAE.

**Received:** April 25, 2020

**Published:** September 30, 2020

© All rights are reserved by **Shaurat Lalwani**.

**Figure**

**Figure 1:** Lesion on the neck.

**Client name:** Manny.

**Breed:** Mixed breed.

**Colour:** White and grey tabby.

**Sex:** Male castrated.

**Age:** 3 years.

### History

- Manny was scratching and he had alopecia.
- He was taken to a previous vet and was advised an antifungal ointment.
- His fur parent stated that there was only 1 lesion on the neck but it has spread and another lesion has come.

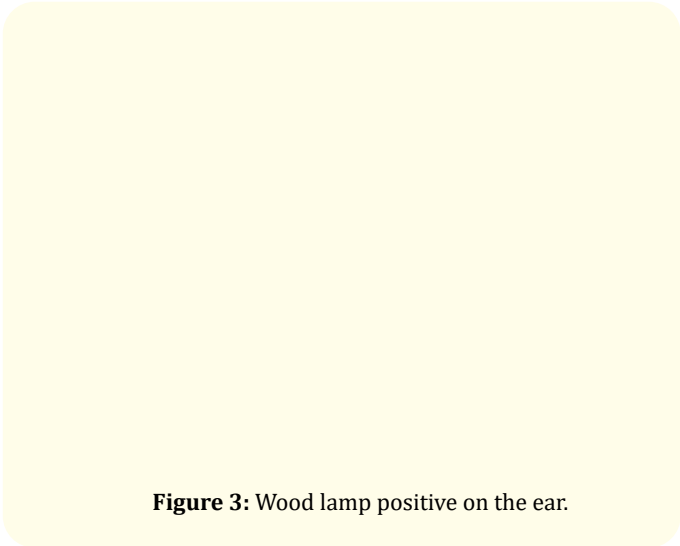
### Examination

- On examination he was bright active.
- TRP normal.
- He had raised circular lesion with erythema on the neck.
- Wood lamp test and skin cytology was suggested.


### Diagnostic procedure

- The woods lamp test was positive there was lesion on the neck, ear pinna and another near the nose.
- Skin cytology showed fungal spores and no cocci or neutrophils.

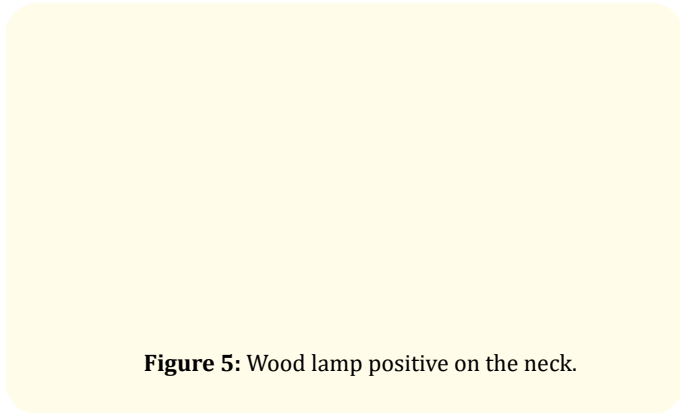
**Figure 2:** Wood lamp positive on the neck.



**Figure 3:** Wood lamp positive on the ear.



**Figure 4:** Wood lamp positive.



**Figure 5:** Wood lamp positive on the neck.

### Treatment

- The affected areas were shaved and he was given a shower with antifungal shampoo.
- Fungafite ointment was prescribed to apply on affected areas twice a day for 1 month.
- Syrup Itraconazole orally once a day for alternate weeks.
- Liver supplement syrup was also given to protect the liver.
- Owner was advised to put on the e collar for Manny.
- Also was asked to come back for a Follow up in 7 days.
- Owner was advised to wash all the bedding blankets with bleach.
- And other managerial practice was suggested.
- His fur parent was advised to wash hand regularly after petting the cat as the fungal infection is zoonotic.
- Avoid getting another animal in the house.

### Follow up

- Manny was much better on follow up advised to stop the syrup but continue the ointment and the liver supplement.
- Follow up again in 7 days to start the medication.

### Assets from publication with us

- Prompt Acknowledgement after receiving the article
- Thorough Double blinded peer review
- Rapid Publication
- Issue of Publication Certificate
- High visibility of your Published work

**Website:** [www.actascientific.com/](http://www.actascientific.com/)

**Submit Article:** [www.actascientific.com/submission.php](http://www.actascientific.com/submission.php)

**Email us:** [editor@actascientific.com](mailto:editor@actascientific.com)

**Contact us:** +91 9182824667