Acta Scientific Veterinary Sciences (ISSN: 2582-3183)

Volume 2 Issue 4 April 2020

Mini Review

Radiographic Characterization of Bone Lesions in Small Animals

Kiran Vasudeva*, Dominique Hemmings, Lauren Rowe and Ruby L Perry

Department of Small Animal Clinical Sciences, Tuskegee University, USA

***Corresponding Author:** Kiran Vasudeva, Department of Small Animal Clinical Sciences, Tuskegee University College of Veterinary Medicine, Tuskegee, Alabama, USA.

Received: February 19, 2020

Published: March 12, 2020

Abstract

Bone lesions are frequently encountered in small animal clinical practice and plain radiography is vital to characterize bone lesions for quick assessment and further management of the case. The characterization primarily involves the identification of roentgen signs (radiographic features) that can be utilized to distinguish between aggressive and non-aggressive/benign bone lesions. In this minireview, a clinical case of feline chondrosarcoma, a rare feline primary bone neoplasia is presented to review the radiographic characterization of bone lesions and the significance of plain radiography in small animal practice.

Keywords: Chondrosarcoma; Radiograph; Feline; Lameness; Bone

Introduction

Radiographic characterization of any bone lesion is necessary to reach at the appropriate radiographic assessment. Bone lesions are characterized as aggressive or non-aggressive in appearance. A typical aggressive bone lesion has at least one or all of the following three features (1) presence of an irregular periosteal reaction (2) cortical bone lysis and (3) indistinct transition zone between the affected and unaffected region of the bone [1]. A periosteal reaction can be broadly classified into smooth or irregular periosteal reaction. A smooth periosteal reaction is usually indicative of a benign/non-aggressive bone lesion and an irregular periosteal reaction usually indicates an aggressive bone lesion. Irregular periosteal reactions can be further classified as spiculated, columnar/palisade or sunburst, based upon their appearance on the radiographs [2]. Cortical bone lysis is destruction of the bone cortex [1]. A transition zone represents the junction between the normal and abnormal bone. A distinct transition zone has clear demarcation between normal and abnormal bone, whereas an indistinct transition zone has a gradual transition between normal and abnormal bone [1]. To reach a definitive diagnosis, a biopsy of an aggressive bone lesion is required, however, radiographic features may serve as a guide to reach the most likely diagnosis. Age of the pet should also be considered for reaching a radiographic diagnosis. Developmental bone lesions such as osteochondrosis and panosteitis are usually seen in juvenile/growing pets whereas neoplasia is typically seen in older adults [1]. Another factor to consider is the number of bones affected by the lesion i.e. one bone affected (monostotic lesion) vs multiple bones affected (polyostotic lesion). Metastatic bone tumors are usually seen in older pets, are polyostotic due to hematogenous spread of the primary neoplastic cells and typically produce osteolytic changes in the affected bones [1]. Fungal or bacterial osteomyelitis is also typically associated with osteolytic changes and is polyostotic in nature except in the cases of trauma or puncture wounds where the lesions are usually localized to the affected region and are monostotic [1]. A primary bone neoplasia may have osteoproliferation, osteolysis or a combination of both, in the affected bone [1]. The characterization of the bone lesions is exemplified below utilizing the feline clinical case presented to Tuskegee University Veterinary Medical Teaching Hospital.

A 10-year and 9-month-old, 7.7-kg (17-lb) male-neutered, indoor domestic shorthair cat was presented for right forelimb swelling and lameness for five days. As per the owner, the cat was being treated with diphenhydramine for allergies, was heartworm negative (tested within a year at the time of presentation) and was current on FVRCP and Rabies vaccines. Upon physical examination, the cat was bright, alert and responsive with normal vital signs. The cat was obese with a BCS of 8/9 and was mildly dehydrated. There was a firm, non-fluctuant, non-painful, walnut size mass on the medial aspect of the distal right forelimb. Occasional coughing and sneezing were also noted. CBC revealed a borderline leukocytosis (17.86 K/µL; reference range, 2.87-17.02 K/ µL), characterized by mild

neutrophilia (13.54 K/μL; reference range, 1.48 - 10.29 K/μL) and marked basophilia (0.51 K/μL; reference range, 0.01 - 0.26 K/μL). Follow-up blood smear evaluation revealed moderate eosinophilia (5.3%) and basophilia (2.9%), consistent with an allergic response. No significant abnormalities were detected with serum biochemical analysis and urinalysis. Orthogonal radiographs of the right forelimb were obtained (Figure 1).

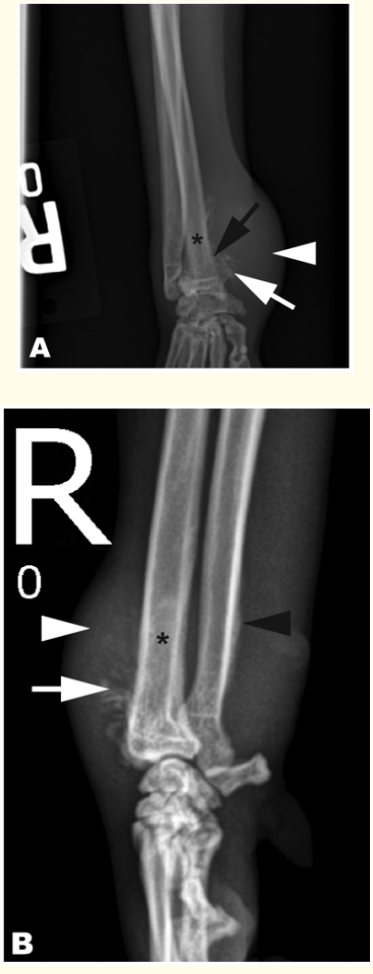

Figure 1: Notice soft tissue swelling (white arrowhead) on the cranio-caudal (A) and lateral (B) views, at the cranial and medial aspect of the radius. Also notice the irregular spiculated periosteal response (white arrows) on both the views. Mild cortical thinning is noted at the distal metaphysis of the radius (black arrow) on the cranio-caudal view. An increased opacity in distal medullary cavity of the radius is visualized (asterisk) on both the views. Note the smooth periosteal response on the caudal cortex of the distal ulna (black arrowhead) on the lateral view.

Results and Discussion

Two orthogonal views of the distal antebrachium and carpus of the right forelimb were obtained (Figure 1). A spiculated periosteal response and adjacent homogeneous soft tissue swelling are present at the cranial and medial aspect of the distal radius. Most of the periosteal response is located near the distal metaphysis of the radius and has an indistinct transition zone. On the cranio-caudal view, there is mild cortical thinning and irregularity at the distal metaphysis of the radius on the medial aspect. Also, an increase in opacity is visualized in the distal medullary cavity of the radius. On the lateral view, a smooth periosteal response with a distinct transition zone is noted on the caudal cortical margin of the distal ulna.

Based upon the radiographic findings, the radiographic assessment is an aggressive, metaphyseal lesion in the distal radius with adjacent soft tissue swelling. Most likely differentials to consider are primary bone neoplasia or an aggressive soft tissue tumor invading the bone. Other less likely differentials to consider are fungal or foreign body granuloma with associated osteomyelitis, bacterial abscess with associated osteomyelitis. The radiographic finding in the ulna is likely due to a benign process such as a reaction to previous trauma, however, an aggressive lesion can-not be ruled out.

After obtaining the forelimb radiographs, fine needle aspirates (FNA) were obtained from the mass. FNA results revealed presence of mesenchymal cells with neoplastic features. Based upon the radiographic appearance and the FNA results, an aggressive neoplasm of mesenchymal cell origin was suspected. However, the tissue of origin (bone vs soft tissue) could not be determined. There was no evidence of pulmonary metastasis in the three view thoracic radiographs (radiographs not included). The bone biopsy was recommended for further diagnostics, however, due to financial constraints, the owner opted for the forelimb amputation instead. The right forelimb amputation was performed after owner approval. Histopathologic analysis revealed the mass to be a chondrosarcoma. During a recent follow up on the phone, the cat is leading a good quality of life at home and no concerns were reported by the owner. The owner was advised to return with the patient within 3 to 6 months after surgery for radiographic re-examination of the thorax for any evidence of metastasis, however, due to owner's non-compliance, the follow-up thoracic radiography could not be performed.

In this study, the presence of an irregular, spiculated periosteal reaction, bone lysis and indistinct transition zone at the distal radius, classifies it as an aggressive bone lesion. Some of the

common aggressive bone lesions are osteomyelitis, primary bone neoplasia and metastatic bone neoplasia. In the present study, due to the monostotic nature of the aggressive lesion and absence of trauma, osteomyelitis and metastatic neoplasia are considered less likely. In an older cat with a monostotic aggressive lesion, a primary bone neoplasia is the most likely differential, however, due to the presence of a soft tissue swelling adjacent to the affected bone, a malignant soft tissue neoplasm invading the bone must also be considered. The increased opacity in the medullary cavity of distal radius could be due to bone infarction or cellular infiltration secondary to the aggressive disease process in the distal radius. A histopathologic sampling of the affected tissue/biopsy is required for a definitive diagnosis.

Common feline soft tissue tumors associated with bone invasion are squamous cell carcinoma and fibrosarcoma [3]. Primary bone neoplasia is extremely rare in cats (0.5% of all feline tumors) [4,5]. A few examples of primary bone tumors in cats are osteosarcoma, chondrosarcoma and fibrosarcoma [6]. The definitive diagnosis in this case was a chondrosarcoma affecting the distal radius. Mean age of occurrence of chondrosarcoma in cats is 9.6 years and males are 1.9 times more likely to get affected by chondrosarcoma relative to female cats [7]. Chondrosarcoma is the third most common primary bone tumor in cats after osteosarcoma and fibrosarcoma [5]. It is a slow growing and locally invasive tumor in cats with lower rates of metastasis as compared to osteosarcoma [5,7,8]. Aggressive surgical excision of the tumor with clean margins or amputation alone of the affected limb has an excellent prognosis for the treatment of chondrosarcoma in cats [7]. On histopathology, no evidence of neoplasia was reported in the distal ulna and the radiographic appearance of smooth periosteal reaction in the distal ulna is likely a benign lesion in this cat. On the histopathology report, the increased medullary cavity opacity in the distal radius is due to cellular and fibrous stroma infiltration in the bone associated with chondrosarcoma.

Conclusion

In conclusion, plain radiography of the affected forelimb and radiographic characterization of the bone lesion were pivotal in the radiographic diagnosis of an aggressive lesion of the distal radius and in further case management. This minireview has emphasized the relevance of plain radiography in imaging the musculoskeletal system and its role in characterization of the bone lesions in small animal practice.

Conflict of Interest

There is no conflict of interest.

Bibliography

1. Donald E Thrall. "Principles of Radiographic Interpretation of the Appendicular Skeleton". In: Thrall Textbook of Veterinary Diagnostic Radiology. 6th ed. St. Louis: Saunders, Elsevier (2013): 252-266.
2. Ragsdale BD., *et al*. "Radiologic and pathologic analysis of solitary bone lesions. Part II: Periosteal reactions". *Radiologic Clinics of North America* 19 (1981): 749-783.
3. Quigley PJ and Leedale AH. "Tumors Involving Bone in the Domestic Cat: A Review of Fifty-eight Cases". *Veterinary Pathology* 20 (1983): 670-686.
4. Dernell WS., *et al*. "Tumors of the Skeletal System". In: Withrow SJ, Vail DM, eds. Withrow and MacEwen's Small Animal Clinical Oncology. 4th ed. St. Louis: Saunders, Elsevier (2007): 540-582.
5. Susan North and Tania Banks. "Tumours of the skeletal system". In: Small Animal Oncology An Introduction. 1st ed. Saunders, Elsevier (2009): 209-224.
6. Turrel JM and Pool RR. "Primary Bone Tumors in the Cat: A Retrospective Study of 15 Cats and A Literature Review". *Veterinary Radiology* 23.4 (1982): 152-166.
7. Durham AC., *et al*. "Feline Chondrosarcoma: A Retrospective Study of 67 Cats (1987-2005)". *Journal of the American Animal Hospital Association* 44 (2008): 124-130.
8. Olson EJ and Carlson CS. "Bones, Joints, Tendons, and Ligaments". In: Zachary JF ed. Pathologic Basis of Veterinary Disease. 6th ed. St. Louis: Elsevier (2017): 954- 1008.