



## Spontaneous Spinal Epidural Haematoma on Apixaban: An Updated Review

Harumi Ramanayake<sup>1,2\*</sup>, Eoin Minnock<sup>1</sup> and David O'Brien<sup>1</sup>

<sup>1</sup>Beaumont Hospital, Beaumont Road, Beaumont, Dublin 9, Ireland

<sup>2</sup>Royal College of Surgeons in Ireland, St. Stephen's Green, Dublin 2, Ireland

\*Corresponding Author: Harumi Ramanayake, Beaumont Hospital, Beaumont Road, Beaumont, Dublin 9, Ireland.

Received: June 19, 2025

Published: July 31, 2025

© All rights are reserved by Harumi Ramanayake., et al.

### Abstract

Over the last decade, prevention of thromboembolism from nonvalvular atrial fibrillation has become more reliant on newly developed oral anticoagulants such as apixaban, an example of a direct oral anticoagulant (DOAC) [1]. One of the major benefits of apixaban is that not only this drug is fast acting but it also avoids the requirement of regular therapeutic monitoring, as is required with warfarin [1]. Apixaban is also known to have decreased risk of bleeding in comparison to warfarin [1]. Apixaban is now being increasingly prescribed due to its superiority in the prevention of stroke or systemic embolism in comparison to historical anticoagulation therapy [1].

Here, we report a case of spontaneous spinal epidural haematoma with long-term apixaban use, which has not been described as a potential side effect in the product monograph [2] nor in any other previous case report identified in the literature.

The aim of this report is to help clinicians appreciate the relevance of spinal haematoma in the context of DOAC use. This review includes studies sourced from several databases including Pubmed, Google Scholar and Medline for collating evidence-based studies. It prudent as clinicians to be aware of this potential complication and exercise caution particularly as frequency of prescribing apixaban continues to rise globally.

**Keywords:** Apixaban; Spinal Stroke; Spontaneous Spinal Epidural Haematoma; Neurosurgery

### Introduction

Over the last decade, prevention of thromboembolism from nonvalvular atrial fibrillation has become more reliant on newly developed oral anticoagulants such as apixaban, an example of a direct oral anticoagulant (DOAC) [1]. One of the major benefits of apixaban is that not only this drug is fast acting but it also avoids the requirement of regular therapeutic monitoring, as is required with warfarin. Apixaban is also known to have decreased risk of bleeding in comparison to warfarin [1]. Apixaban is now being increasingly prescribed due to its superiority in the prevention of stroke or systemic embolism in comparison to traditional anticoagulation therapy [1].

Here we report the first case of apixaban-induced spontaneous spinal epidural haematoma, which has not been described as a potential side effect in the product monograph [2] and no other previous case report have been identified in the literature.

### Background

Spinal hematomas are considered a neurosurgical emergency. If left untreated or misdiagnosed they can result in detrimental outcomes.

In Table 1, the authors summarise previously reported cases of hematomas in the spine in the presence of NOAC use (Table 1). Through this updated review we examine the type of hematomas, strength of various NOAC used and treatment they were offered with its relevant outcomes. Due to the rarity of the cases there has been no available guidelines on treating these cases. Each published reports have been managed on a case-by-case basis.

The information is sourced from several databases, namely Pubmed, Google Scholar and Medline when collating evidentiary information. Search method consisted of key words including spontaneous spinal haematoma and apixaban or anticoagulants (rivaroxaban, dabigatran, and edoxaban); spontaneous spinal epidural hematoma and rivaroxaban, NOAC or DOAC; spontaneous

subdural haematoma and apixaban, NOAC or DOAC; spinal hematomas and DOAC or NOAC. There were no restriction to language or year of publication made in order to include all possible data set in to this literature review. All references were individually studied and were manually reviewed.

**Case Report**

A 76-year-old gentleman presented to our institution’s ED with complete paralysis and sensory loss in bilateral lower limbs on a background history of apixaban use for atrial fibrillation. Apixaban was started 2 years prior to his presentation. On admission, he was hypertensive and bradycardic but orientated to person, place and time.

Type of NOAC and dose	Indication for NOAC	Age & gender	Types of spinal hematoma	Treatment and outcome	References
Rivaroxaban 20 mg OD	Atrial Fibrillation	69 years (Male)	Thoracic-lumbar(subdural)	Surgery; No improvement	Castillo., <i>et al.</i> [3]
Rivaroxaban 20 mg OD	Atrial Fibrillation	72 years (Male)	Thoracic(subdural)	Prothrombin complex, surgery; No improvement	Dargazanli., <i>et al.</i> [4]
Rivaroxaban 20 mg OD	Atrial Fibrillation	58 years (Female)	Cervicothoracic(subdural)	Steroids, surgery; partial improvement	Zaarour., <i>et al.</i> [5]
Apixaban 2.5 mg BD	Atrial Fibrillation	75 years (Female)	Cervical-dorsal-lumbar-sacral(subdural)	Steroids, two surgeries; partial improvement	Collel., <i>et al.</i> [6]
Apixaban 5 mg OD	Atrial Fibrillation	67 years (Female)	Thoracic (subdural)	Surgery; Full recovery	Ardebol., <i>et al.</i> [7]
Apixaban 5 mg OD	Atrial Fibrillation	68 years (Male)	Lumbar sacral(subdural)	Conservative; Partial recovery	McHaourab., <i>et al.</i> [8]
Apixaban 5 mg BD	Atrial Fibrillation	84 years (Male)	Thoracic-lumbar- sacral-cauda equina(subdural)	Pre-op and exanet alfa, surgery; Partial recovery	Faiek., <i>et al.</i> [9]
Apixaban 5 mg BD	Atrial Fibrillation	76 years (Female)	Cervical(epidural)	Conservative (2 days), Surgery; Partial recovery	El Alayli., <i>et al.</i> [10]
Rivaroxaban, Aspirin (dose N/A)	Atrial Fibrillation, coronary artery disease	72 years (Male)	Thoracic – lumbar(epidural)	Fresh frozen plasma, Surgery; full recovery	Ismail., <i>et al.</i> [11]
Rivaroxaban 10 mg OD	Prophylactic VTE post-orthopaedic surgery	61 years (Female)	Cervical-thoracic(epidural)	Nil intervention; Full spontaneous recovery	Jaeger., <i>et al.</i> [12]
Dabigatran 150 mg BD	Atrial Fibrillation	70 years (Male)	Cervical(epidural)	Prothrombin complex, Surgery; full recovery	Bamps., <i>et al.</i> [13]
Rivaroxaban 10 mg OD	Prophylactic VTE post-orthopaedic surgery	69 years (Female)	Cervical (epidural)	Nil intervention; full spontaneous recovery	Ozel., <i>et al.</i> [14]
Rivaroxaban (dose N/A)	Atrial Fibrillation	74 years (Male)	Foramen magnum -Cervical (epidural)	Surgery; recovery status not discussed	Goldfine., <i>et al.</i> [15]
Warfarin and enoxaparin 20 mg OD switched to Rivaroxaban 10 mg OD	Prophylactic VTE post-orthopaedic surgery	53 years (Female)	Lumbar(epidural)	Surgery; full recovery	Radcliff., <i>et al.</i> [16]
Apixaban 5 mg BD	Atrial Fibrillation	76 years (Male)	Cervical-Thoracic(epidural)	Surgery; Partial recovery	This case

**Table 1:** Review of spontaneous spinal haematomas in the context of NOAC use.

Onset of the paralysis and sensory loss was sudden in nature while lying down on his bed at home. He did not have any palpitations, chest pain, loss of consciousness or visual changes before, during or after the incident. He also denied any trauma. He reported pain and reduced sensation in T8 dermatome for both soft and sharp touch. Past medical history is significant for atrial fibrillation, hypertension, dyslipidaemia, COPD, shingles and glaucoma. Atrial fibrillation was being treated with 3 previous cardioversions and then apixaban for 2 years. Physical examination showed bilateral lower limb paralysis with manual muscle testing (MMT) of 0/5 in all limbs with palpable peripheral pulses. He did not suffer from any facial palsy, dysarthria and aphasia. Deep tendon reflexes were hypoactive with upgoing plantar reflex. Sensory exam showed complete loss of sensation to fine touch as well as loss of sensation to pain and temperature in both lower limbs. He did not complain of any incontinence, perianal or perineal paraesthesia.

Upon admission he subsequently underwent CT brain and whole spine MRI. CT brain was normal however the MRI spine showed acute dorsal epidural haemorrhage extending from C6-T3, measuring 9cm in maximal craniocaudal dimension (Figure 1). Unfortunately, the scan showed complete effacement of the dorsal thecal sac at C6-T3 with mass effect on the adjacent cervicothoracic cord segment (Figure 2). He was admitted to HDU for pre-operative management.

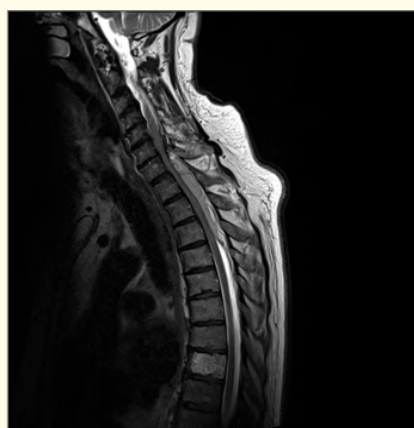Neurosurgery was consulted for emergency spinal decompression and C6-T3 haematoma evacuation. During his admission apixaban was stopped and switched to LMWH after the surgery. Post-operative MRI spine confirmed an extensive posterior laminectomy from C6-T4. A residual epidural haemorrhage was seen inferiorly below the laminectomy from C6-T3. This may have been present on pre-operative imaging however it was masked by the large hematoma. The picture was consistent with significant cord oedema and it was not clear at this point whether there was any gliosis or infarction present.

Post-operatively the patient's sensation in T8 dermatome improved however unfortunately remained MMT 0/5 in his lower limbs with no further sensory improvements. He required a 13 day stay in HDU before discharge to the ward due to hyponatremia post-operatively secondary to hypovolemia. This was corrected as per endocrinology team. Moreover, his post-operative course was further complicated by provoked bilateral below knee DVT. Risk factors for this included apixaban being on hold and prolonged immobility. Although he was put on prophylactic LMWH post-operatively as per haematology team, bilateral lower limb doppler confirmed for non-occlusive thrombus and right and left posterior

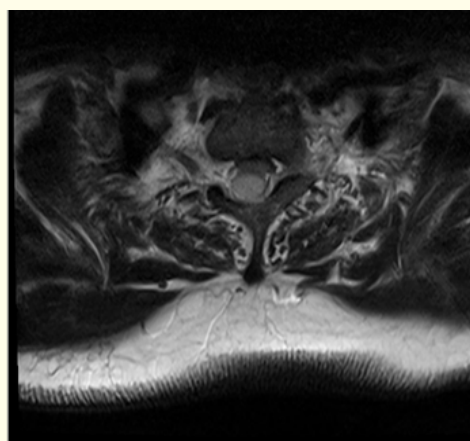
tibial veins. With careful considerations to avoid DVT recurrence this gentleman is planned to complete 3 months course of therapeutic LMWH.

He was then transferred to the National Rehabilitation Hospital in Ireland for continued multidisciplinary input and physiotherapy. His case was extensively discussed in haematology, neurosurgery and cardiology multi-disciplinary team meeting. Consultant-led decision was made to restart apixaban 5mg BD after the completion of therapeutic LMWH.

Over two years later this gentleman did not make any progress in his mobility or sensation regardless of extensive rehabilitation.



**Figure 1:** An acute dorsal epidural collection at C6-T3. It is both central and slightly eccentric to the right. It is multiloculated with septations and heterogeneity. It is hypointense on T1, slightly hyperintense on T2 and avidly hyperintense on STIR sequence.



**Figure 2:** There is complete effacement of the dorsal thecal sac and compression of the spinal cord at C6-T3. No oedema demonstrated within the spinal cord segment at this time.

## Discussion

Spinal haematomas are a devastating complication of apixaban use. It is an uncommon clinical manifestation that can cause significant irreversible neurological impairment or fatality without early diagnosis, urgent medical management and immediate surgical intervention. Spinal hematomas in general are frequently subclassified according to the anatomical location; epidural (>75% of cases), subdural, subarachnoid, or intramedullary.

Interestingly, there have been previous reports of various spinal hematoma formation with the use of other NOACs, most notably with Rivaroxaban use (Table 1). Our case is specific to apixaban resulting in spontaneous epidural hematoma, which make it more unique. One similar case report published by El Alayli et al. whom described spinal epidural haematoma with apixaban [10]. However, in this case the patient was on short term apixaban course of 1 month. Collet et al described a case of spinal haematoma in the context of NOAC switch [6]. However, in our case presented here, there was no change in NOACs regime, trauma or any other predisposing risk apart from long term apixaban use. This is a rare case of spinal epidural haematoma that has been associated with the sole use of long term apixaban.

Although this was a complex clinical case, the most challenging part was the decision for this gentleman's anticoagulation therapy in the coming future. Given that he suffered from multiple DVT promptly after apixaban has been held which indicates the difficult nature of maintaining the best therapeutic window for thromboprophylaxis. This patient scored 6 on CHA2DS2-VASc and score of 3 on HAS-BLED indicating the need for adequate anticoagulation despite the complication caused by apixaban use. With his history of long-standing cardioversion-resistant atrial fibrillation and as per the previous published reports on dangers in NOACs switch, a consultant-led decision was made to continue anticoagulation with apixaban. No case published in the literature included long-term anticoagulation treatment after the incident of spinal haematomas upon which to base further guidance.

According to our review, 57% of spinal haematoma was caused by rivaroxaban mostly epidural in nature [3-5,11-16]. Within this group 37.5% resulted in complete recovery which included urgent surgical haematoma evacuation (<24hrs). Apixaban ranked the second highest NOAC to cause spinal hematomas at 42.9% and majority of haematomas were subdural in anatomical location [6-10]. Only 1 out of 5 cases resulted in full recovery with apixaban use [7]. Dabigatran showed only 1 complicated case of epidural haematoma which resulted in partial recovery [13]. There have been no case reports published on edoxaban as a cause for spinal haematoma as of yet.

It is important to note that 5 out of 14 patients (36%) resulted in complete recovery. These cases were specific to patients who received early clinical diagnosis and immediate surgical intervention with a reported mean age of 65. Exceptional cases were notably the spontaneous full recovery with no interventions [12,14]. Furthermore, as described in Bamps et al and Ismail et al, utilization of prothrombin complex concentrate and fresh frozen plasma have reported positive outcomes [11,13]. Some previous studies have confirmed effective reversal method for factor Xa inhibitors [17]. Most importantly to note, none of the cases above have reported excessive perioperative bleeding therefore early surgical evacuation (<24 hours) should be considered for best outcomes.

Lastly, the exact mechanism and cause for spinal epidural haematoma in the context of apixaban use still remains controversial. Due to the rarity of this condition medical professionals will face significant difficulty in establishing adequate and effective management for their patients' substantial recovery. In a case like this it is essential to take careful decisions on a case-by-case basis with experienced health care professionals to learn from these published reports in order to avoid disastrous complications.

## Conclusion

Apixaban remains to be one of the most commonly prescribed medications for the prevention of stroke and systemic embolic events worldwide. As it is still a relatively new medication compared to traditional anticoagulant like warfarin we have a lot more to explore and learn. As there is a global increase in apixaban use the rate of adverse drug reactions will continue to rise. Without clear awareness of potential drug reactions and side effects, clinician will face difficulties in managing unexplained illness and considering other potential diagnosis. It has not been reported in clinical trials that apixaban may be associated with the complication of spontaneous epidural haematoma. Adequate guidelines on continuation, discontinuation of the drug itself or switching to another NOACs is yet to be established. It is still a possibility that the spontaneous spinal haematoma was completely unrelated to the apixaban; however, it is essential to note that this drug remains to be relatively new, reporting uncommon side effects and complications is essential in determining accuracy and true incidence of apixaban-induced spontaneous spinal haematoma globally.

## Summery

Apixaban is a newly established anti-coagulant drug developed as an alternative to traditional anticoagulants such as warfarin. Although apixaban may seem superior among many available drugs, an uncommon life-altering side effect of this is spontaneous epi-

dural haematoma. We discuss this here. To our knowledge there has been no previously published case reports. It is prudent that we as clinicians are aware of this rare presentation, particularly as frequency of prescribing apixaban continues to rise globally.

### Learning points

- Apixaban is a newly established anti-coagulant drug prescribed globally.
- An uncommon life-altering side effect of this is spontaneous epidural haematoma is documented here.
- It is essential that clinicians are aware of this rare clinical presentation.
- If there is a suspicion for such complications it is critical that patients receive relative investigations and operative management as soon as possible.

### Patient perspectives

I would like to thank the authors of this paper for putting together my story and raising awareness of what has happened to me. Prior to this incident I led a relatively healthy life as a marathon runner. I was a strong father figure to two of my beloved children.

Now since the accident I live my life from a wheel chair. It has been one of the hardest 2 years of my life trying to adopt to my new body. My life is physically and mentally challenging every single day.

Regardless of how difficult my life is I try to keep a positive mind and move forward. On a daily basis I try to keep myself more focus on adapting to my new body and re-learning how to move by strengthening my core body with physiotherapy. I am now able to move from wheel chair to bed which is a big achievement for me.

My hope is that this case report will reach out as many people as possible and make people aware of what has happening to me. I pray that in future there will be a protocol or a clinical guideline in place to prevent such incident from happening again.

### Bibliography

1. Guimarães PO, *et al.* "Efficacy and safety of apixaban vs warfarin in patients with atrial fibrillation and prior bioprosthetic valve replacement or valve repair: Insights from the ARISTOTLE trial". *Clinical Cardiology* 42.5 (2019): 568-571.
2. ULC, P.C. PRODUCT MONOGRAPH ELIQUIS. 07 October (2019).
3. Castillo JM, *et al.* "Non-Traumatic Spontaneous Spinal Subdural Hematoma in a Patient with Non-Valvular Atrial Fibrillation During Treatment with Rivaroxaban". *The American Journal of Case Reports* 16 (2015): 377-381.
4. Dargazanli C, *et al.* "Nontraumatic spinal subdural hematoma complicating direct factor Xa inhibitor treatment (rivaroxaban): a challenging management". *European Spine Journal* 25.1 (2016): 100-103.
5. Zaarour M, *et al.* "Rivaroxaban-Induced Nontraumatic Spinal Subdural Hematoma: An Uncommon Yet Life-Threatening Complication". *Case Reports in Hematology* 2015 (2015): 275380-275380.
6. Colell A, *et al.* "Iatrogenic Spinal Subdural Hematoma due to Apixaban: A Case Report and Review of the Literature". *Case Reports in Hematology* 2018 (2018): 4507638-4507638.
7. Ardebol J, *et al.* "Spontaneous thoracic spinal subdural hematoma associated with apixaban therapy". *Journal of Surgical Case Reports* 2019 (2019): rjz115-rjz115.
8. McHaourab A, *et al.* "Spontaneous spinal subdural haematoma in a patient on apixaban". *BMJ Case Reports* 12.1 (2019): e227311.
9. Faiek S, *et al.* "A Rare Case Presentation of Apixaban-induced Nontraumatic Spinal Subdural Hematoma". *Cureus* 12.1 (2020): e6743-e6743.
10. El Alayli A, *et al.* "Spontaneous Spinal Epidural Hematoma in a Patient on Apixaban for Nonvalvular Atrial Fibrillation". *Case Reports in Hematology* 2020 (2020): 7419050-7419050.
11. Ismail R, *et al.* "Spontaneous Spinal Epidural Hematoma in a Patient on Rivaroxaban: Case Report and Literature Review". *Journal of Emergency Medicine* 53.4 (2017): 536-539.
12. Jaeger M, *et al.* "Spontaneous spinal epidural haematoma during Factor Xa inhibitor treatment (Rivaroxaban)". *European Spine Journal* 21.2 (2012): S433-S435.
13. Bamps S, *et al.* "Dabigatran-associated spontaneous acute cervical epidural hematoma". *World Neurosurgery* 83.2 (2015): 257-258.
14. Ozel O, *et al.* "Atypical Presentation of an Epidural Hematoma in a Patient Receiving Rivaroxaban After Total Hip Arthroplasty". *Orthopedics* 39.3 (2016): e558-560.

15. Goldfine C., *et al.* "Spontaneous Spinal Epidural Hematoma from Rivaroxaban". *Clinical Practice and Cases in Emergency Medicine* 2.2 (2018): 151-154.
16. Radcliff KE., *et al.* "Rivaroxaban-induced epidural hematoma and cauda equina syndrome after total knee arthroplasty: a case report". *Orthopaedic Surgery* 6.1 (2014): 69-71.
17. Smith MN., *et al.* "Safety, efficacy, and cost of four-factor prothrombin complex concentrate (4F-PCC) in patients with factor Xa inhibitor-related bleeding: a retrospective study". *Journal of Thrombosis and Thrombolysis* 48.2 (2019): 250-255.