



## Back Bench Preparation of Pancreas: Principles and Techniques

Asuri Krishna<sup>1\*</sup>, Raman Dhanda<sup>2</sup> and Virinder Kumar Bansal<sup>3</sup>

<sup>1</sup>Additional Professor, Department of Surgical Disciplines, AIIMS, New Delhi, India

<sup>2</sup>Manchester Royal Infirmary, Manchester, UK

<sup>3</sup>Professor, Department of Surgical Disciplines, AIIMS, New Delhi, India

**\*Corresponding Author:** Asuri Krishna, Additional Professor, Department of Surgical Disciplines, AIIMS, New Delhi, India.

**Received:** November 17, 2022

**Published:** August 21, 2023

© All rights are reserved by **Asuri Krishna, et al.**

A careful and meticulous back bench preparation of pancreas is the single most important factor towards a successful pancreas transplant. The foundation of technical complications/losses after transplantation are laid at the time of back bench preparation. Therefore, back bench preparation demands attention to every detail. It requires patience as a good preparation takes 2-3 hours, unhurried approach, skills, meticulous techniques and a meticulous stepwise approach. It is preferable that back bench preparation is done by a separate team as it prevents rushing through the procedure as there is a second team ready to take care of the implantation.

Back bench preparation consists of the following components:

- Setting up
- Assessment of pancreas
- Procedure of back benching

Each step is crucial for an ultimate good outcome. It is a multi-step process and it is imperative to have a sequence. Certain steps are flexible in terms of sequence adopted although others are not, e.g. vascular reconstruction.

### Setting up

One should have a trolley, which is large enough and has wheel brakes and a foot rest. A 4'x3' trolley is adequate for benching. A good light source is required. An LED white Light source is preferred as it emits cold light, which does not warm the organs. One requires a rectangular plastic basin, which can contain 1-15 sterile ice slush and a smaller metal tray to set in the plastic basin

surrounded by slush. It is important to note that one must avoid getting the pancreas in direct contact with the slush and at the same time, maintaining the temperature.

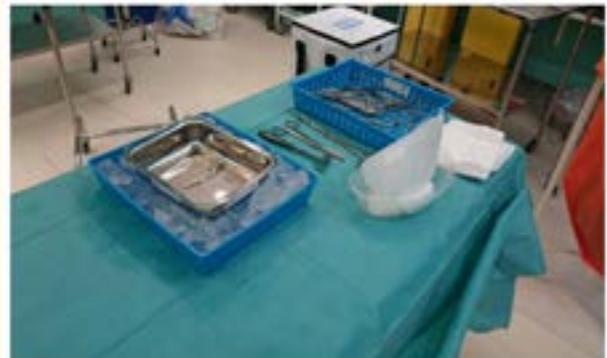

Figure 1

### Instruments

The essential instruments required for back bench preparation should be as per the centre preference. However, following instruments should be a part of the set:

- Baby Mixtar 140mm
- 6 inch vascular probe

- Fine needle holder, medium size
- Castroviejo needle holder medium size with a ... lock
- Angled deBakey forceps medium size, at least two
- Spence wells straight and curved, medium size
- Mosquito forceps
- GIA/TA – 30 staples




Figure 2

Traditionally, back bench preparation was done using only sutures. However, newer devices like Ligasure, Harmonic can be used with advantage of reducing time as well as better hemostasis. A combination of sutures, hemostatic devices and clips is the preferred method.

Before one starts with the procedure, replace the UW solution of the organ bag if it appears oily, turbid or bloody. Here one can take the opportunity to collect the UW fluid for culture. It is imperative that the pancreas stays immersed in the perfusion fluid all the time. The pancreas should be handled as less as possible. Always place the pancreas in anatomical position with duodenum to the left and spleen to the right. Use the spleen as a handle and always log roll the pancreas to avoid any twist. By log roll one means that the entire pancreas with duodenum and spleen should be turned as a unit as one rolls a log.

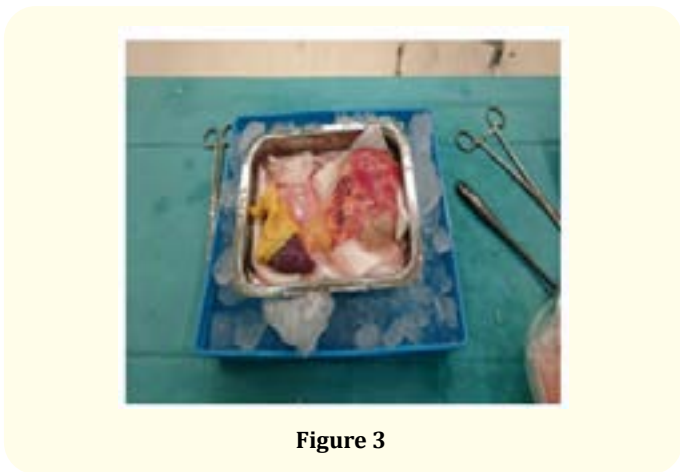
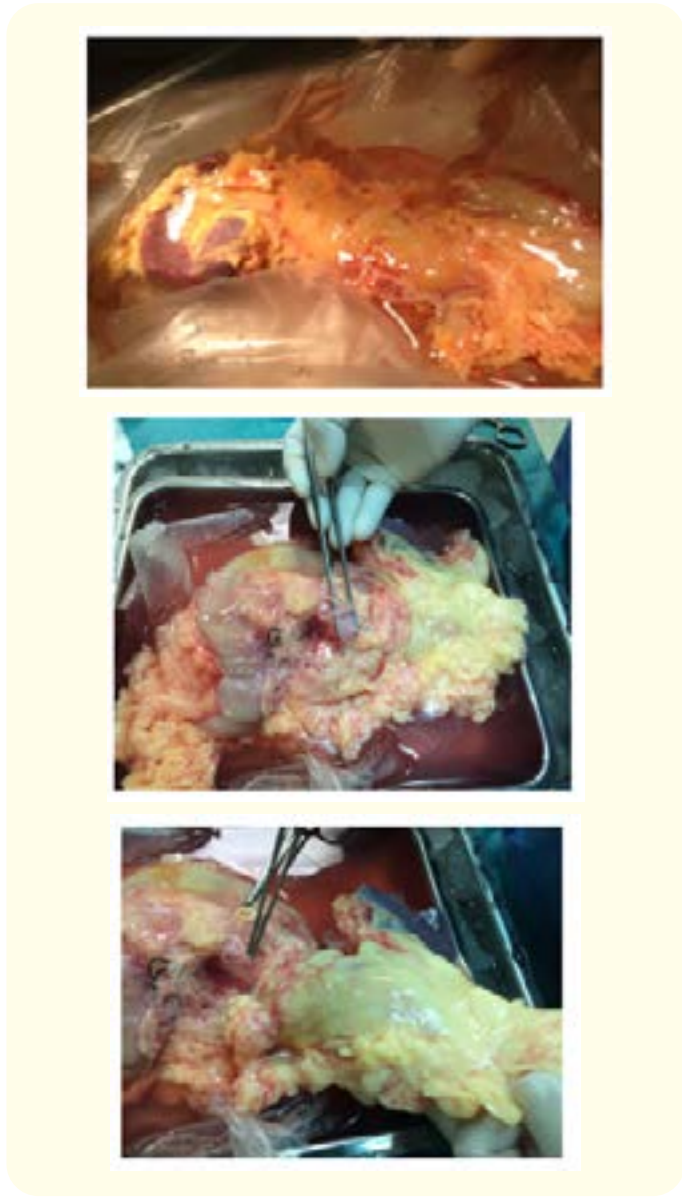
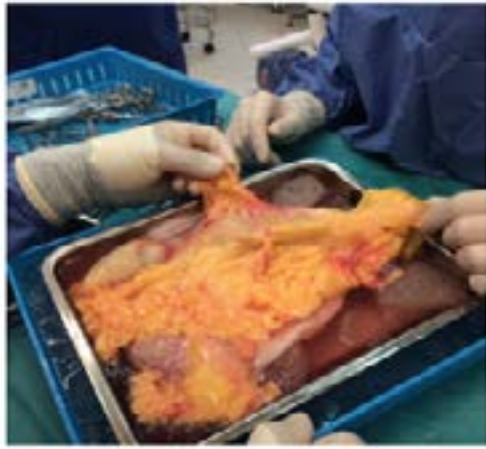
Figure 3

### Assessment of pancreas

Inspection by experienced eye is a key factor in assessing an deciding the suitability. This initial inspection is the best opportunity for careful qualitative assessment of graft before transplantation. If there is any doubt always seek a second opinion and reassess after complete benching. The decision to transplant an organ is dictated not only by the condition of the organ but also in the predicted cold ischaemia time (should be ideally less than 12 hours), health of recipient and urgency of transplant.





**Figure 4**

A simple way to assess the suitability of pancreas is using the ABCDE approach.

- Arterial/venous conduit – Whether the conduits are present of adequate length. There should be no atheroma or intimal dissection/damage present.
- Blood vessels – One must examine the SMA to look for any atheroma, damage or thrombus. Presence of plaque in the wall of SMA invariably is associated with a fatty pancreas. Splenic artery should also be examined for the course (sometimes it has a tortuous course away from pancreas), any damage, aneurysm or thrombus. Portal vein should be assessed for any damage and adequacy of length. At least 10 cm of portal vein length above the pancreatic pit is required for a tension free anastomosis. Splenic vein should also be assessed for the presence of any thrombus.
- Capsular parenchyma – One must gently and carefully examine the pancreas for any capsular tear, parenchymal damage, any hematoma or mass lesions. Small capsular tears do not contraindicate transplantation. They can be repaired using a peritoneal patch from the recipient or reinforced with omentum at the end of the surgery. Any significant parenchymal damage, hematoma or mass lesion precludes the use of the organ.
- Duodenum – It should be examined for any tears, perforation, diverticula, ulcer, intramural hematoma. The stapled lie

should be examined for any bile staining, which, if present, indicates leak and will require to be reinforced at the time of benching.

- Ensure collateral flow – The presence of collateral circulation between pancreas and duodenum is the key to a whole organ transplant. The intactness of their collateral circulation should always be checked. It can be done by gently flushing the SMA with UW solution. If the arcade is patent one will see return of the fluid from the GDA as well as the portal vein. one can flush through the GDA also in case the SPDA is close to the margin of SMA.
- Fattiness and fibrosis – An ideal pancreas should be non-fatty and soft. It is important to assess the subcapsular fat between the acini. A good pancreas looks fleshy with minimal inter-acinar fat. The head of the pancreas should also be inspected for the fattiness. Healthy extracapsular fat is also a good indicator of fattiness of pancreas. Healthy extracapsular fat is indicative of a healthy pancreas whereas a pale fat indicates an unsuitable organ. Minimal fatty pancreas (less than 30% fatty) can also be transplanted provided the CIT is short. Excess fat increases the incidence of pancreatitis as well as collection as these are poorly perfused and also indicates low islet cell volume.

### Procedure

It is important to have a set practice and a methodical sequence of steps so that one avoids making mistakes. One preferred sequence is:

- Inferior border of pancreas/mesocolon
- Superior border of pancreas
- Ligation of splenic artery/splenic vein and splenectomy
- Dissection of mesenteric root and reinforcement
- Preparing the duodenal C loop
- Splanchnic ganglionectomy around SMA
- Portal vein dissection
- Y graft reconstruction
- Collateral circulation reassessment and check if leak
- Transfixation of GDA and CBD.



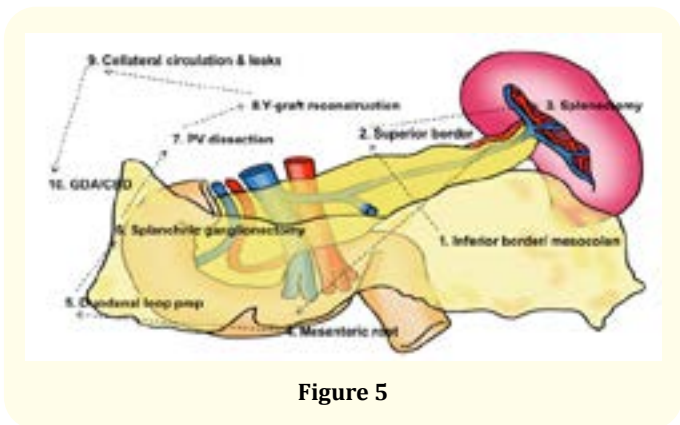


Figure 5

Inferior border and mesocolon – Artery forceps are applied to the edges of the mesocolon to spread it. The mesocolon is then sequentially ligated and divided or divided using energy device. It is best to start from the tail of pancreas and follow the line of attachment of mesocolon. One will encounter the inferior mesenteric vein, which should be double ligated close to the pancreas. The middle colic vessels should also be identified and ligated separately. It is very essential to keep the dissection 4-5 mm away from the pancreas. It prevents the vessels from retraction under the capsule. Also, if ligated very close to the pancreas, it causes tightening of the pancreatic capsule. As at reperfusion there is invariably some oedema of the pancreas, a tight capsule can act as a constriction, which can lead to microvascular thrombosis.

Superior border – the superior border is more challenging than the inferior border because of the presence of the splenic artery, which can sometimes be very tortuous in course as well as may be well away from the pancreas. One method of preventing damage o splenic artery is to gently pass an infant feeding tube into the splenic artery. This allows the splenic artery to be palpated and one can thus, stay away from the splenic artery.

Splenic hilar dissection and splenectomy – Splenectomy should be done as a rule. One must always beware of a thrombus in the splenic artery and vein, especially in case of recent splenectomy for trauma. One has to be careful about not injuring the tail of pancreas. The best method is to gently palpate the tail of the pancreas and dissect towards the spleen. The distal splenic artery and proximal splenic vein should be dissected individually and double ligated separately because of the possibility of AVF in case of mass ligation. Try to keep the bench as short as possible to prevent thrombosis due to stasis. The sutures should be left long so that they can be used as a 'handle' for the pancreas during implantation by no touch technique.

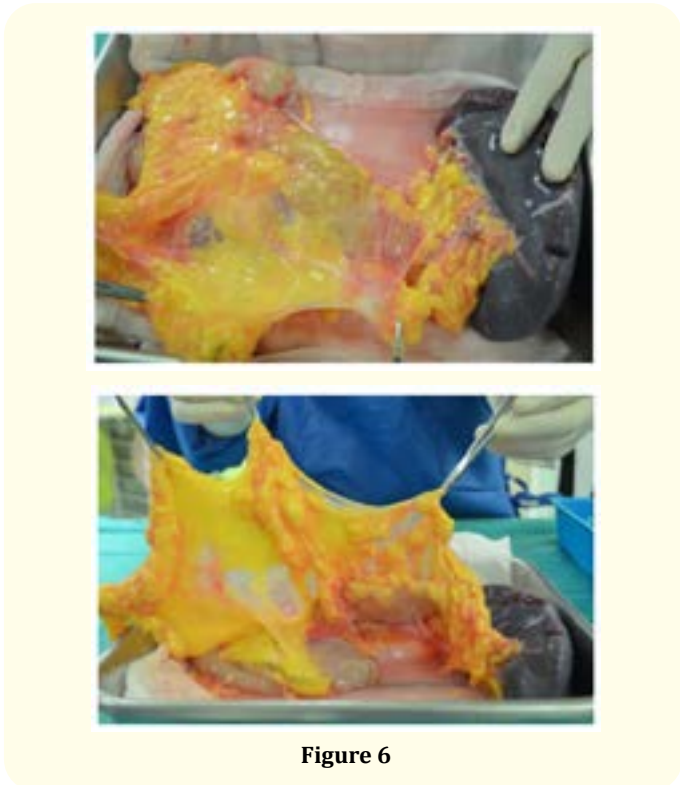


Figure 6

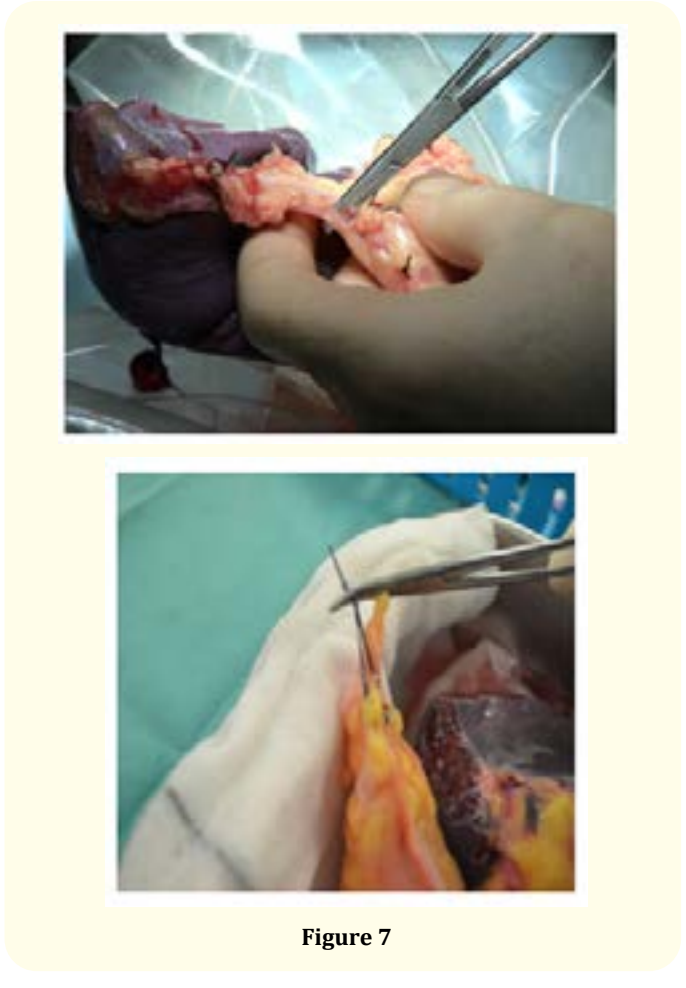


Figure 7

Mesenteric root reinforcement – the main purpose of this is to ensure perfect haemostasis within the root containing the superior mesenteric vessels and has to be done cautiously as one may risk damage in the pancreatic-duodenal arcade. The steps that need to be taken to prevent damage to the pancreatic-duodenal arcade is to staple the small bowel mesentery at least 2 cm away from the head of the pancreas and uncinate process during the retrieval surgery. At back bench, one must carefully separate the stapled root from the duodenum. The SMA can be gently probed to assess the revised stapled line to avoid inadvertent inclusion of IPDA. While revising the stapled line one must ensure that the root is not lifted too much with the stapler. Before firing the stapler the flow through the GDA should be once again checked. The stapled root is then oversewn with 3-0 prolene horizontal mattress sutures followed by a running over and over stitch. Always recheck collateral flow after completion.

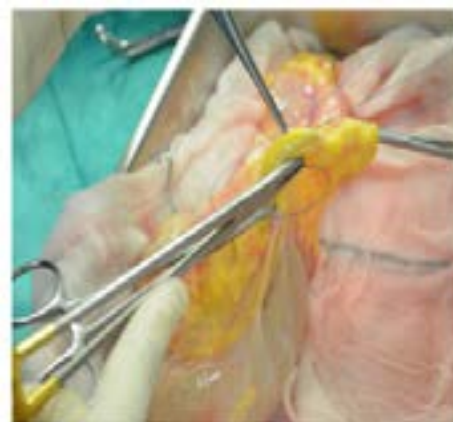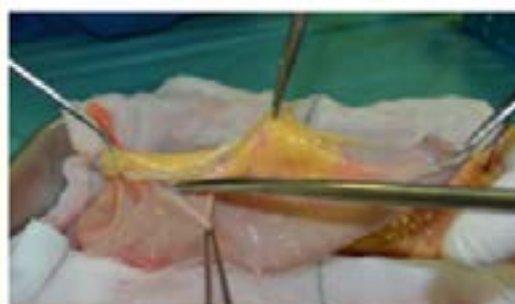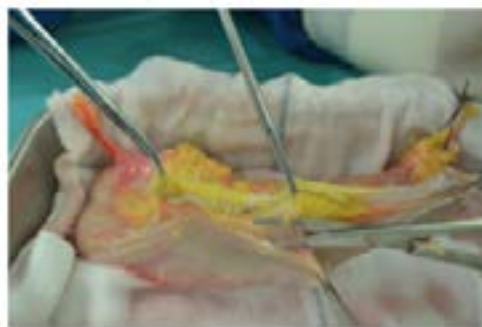
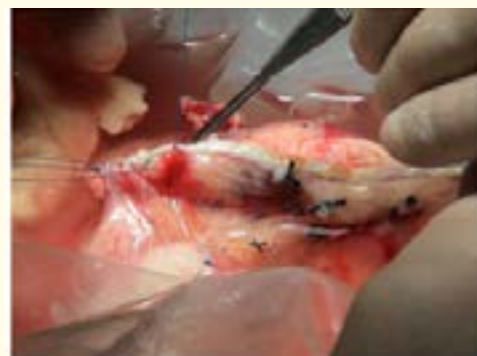


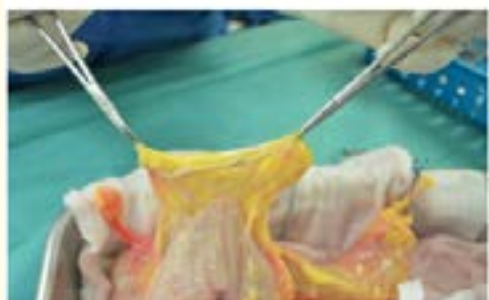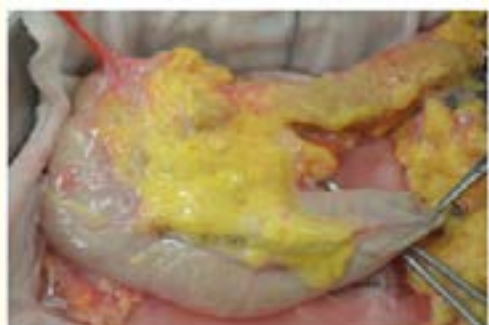Figure 8

Preparation of duodenal segment – During retrieval the duodenum is typically stapled at D1 and D4 including proximal jejunum. At back bench one should recheck the staple line for any bile staining, which is indicative of loose staples. In this situation if the duodenum cannot be stapled again then the staple line should be reinforced with prolene sutures. Remove the duodenum until it is “easy”. Always aim to keep the segment length to about 10 cm for enteric drainage and 4-6 cm for bladder drainage. The GIA stapler should be applied at 45 degree to the mesenteric border. Always allow 8-10 seconds before firing. One can do a gentle milking of the luminal contents towards jejunal end before firing but caution



should be to not cause mucosal injury. The stapler should be fired such that at least 1 cm of the stapled end is free for easy inversion, especially at the juxtapancreatic corner. The staple line is then inverted using 3-0 PDS/prolene starting from the juxtapancreatic corner. One can use either interrupted or continuous Lembert seromuscular sutures. The CBD is then identified, transfixed and ligated with non-absorbable sutures.

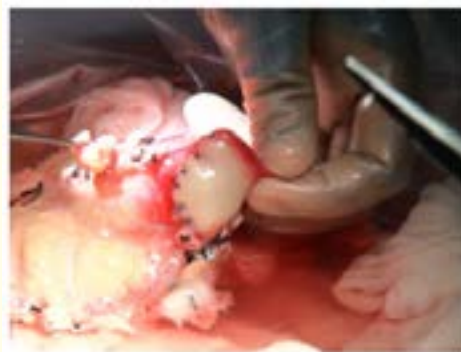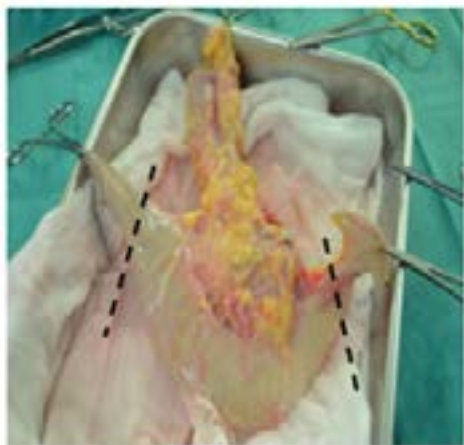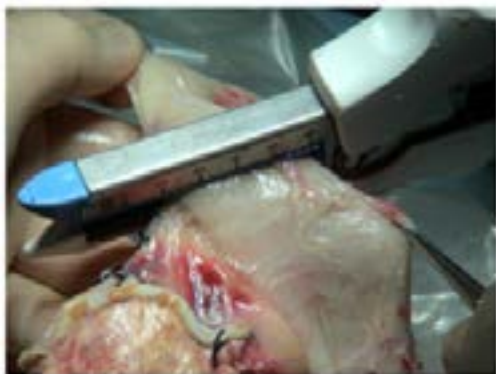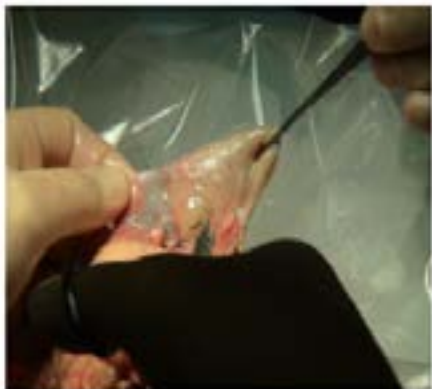


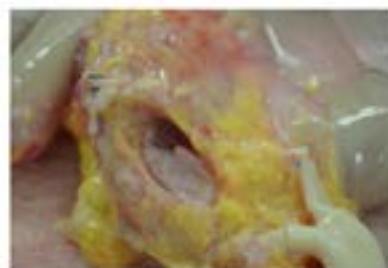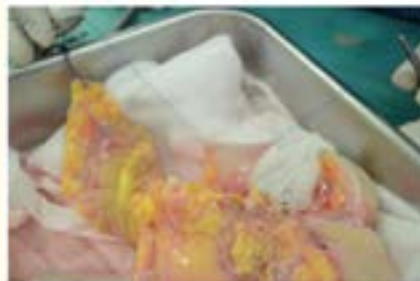Figure 9

Vascular dissection and reconstruction – This comprises of 3 steps: (A) Portal vein dissection – It is better to place two 5-0 prolene stay sutures on the corners of the portal vein o minimize instrument handling of the vein. This also facilitates the circumferential dissection of the portal vein. Stay close to the portal vein. Small tributaries should be ligated meticulously. This gives an additional 5-7 mm of portal vein length. The ideal portal vein length should be 5-10 mm above the crater edge in an unstretched position. If portal vein is more than 3 cm it may need shortening. Venous extension is rarely required and should be avoided as it adds another suture line and can predispose to stasis and thrombosis. The veins always shrink longitudinally as the compliance increases horizontally on reperfusion.



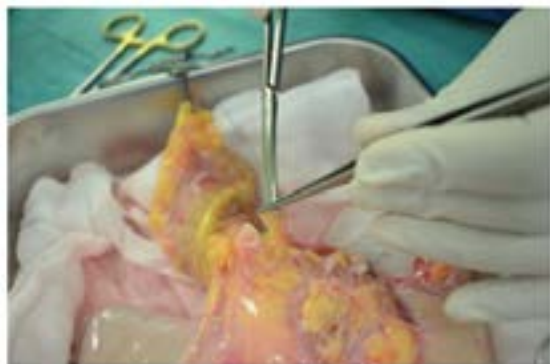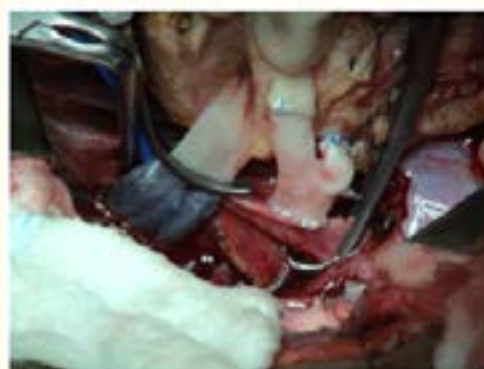


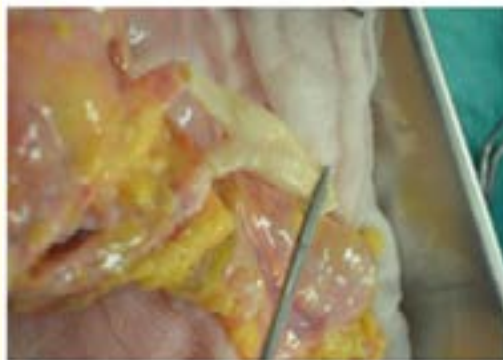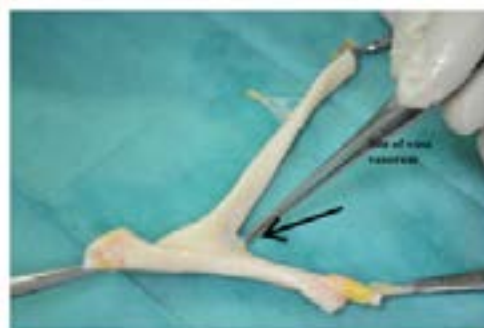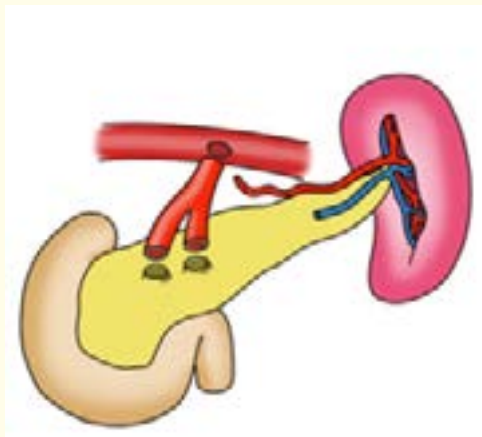
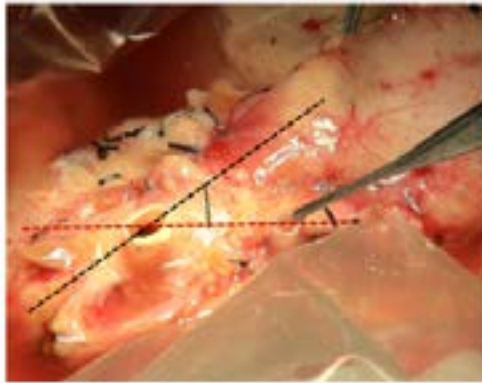


Figure 10

Splanchnic ganglioneurectomy with dissection around SMA and splenic artery – The SMA is surrounded by the splanchnic ganglion and lymphatics. It is essential to dissect this tissue to increase the distensibility of the artery, prevent a constriction band, which may increase due to oedema, to prevent bleeding and lymphatic leakage. However, one must avoid too deep dissection of SMA to avoid damage to the collateral branches. Careful circumferential dissection should be performed staying right on the surface of SMA. The best way to do this is to divide the tissue longitudinally in to 3-4 columns and seal with energy device like Ligasure. (C) Y graft reconstruction - After the vascular dissection the collateral flow is reassessed. Is the GDA looks dominant it might also need reconstruction. An accessory right hepatic artery is not always a contraindication for safe pancreas retrieval and transplant provided it is not coursing through the pancreatic parenchyma. The SMA stump should be kept short (approx. 1 cm). One should always look inside the lumen before dividing. If a branch is seen then SMA should be divided at least 3 mm above the tributary to prevent it from getting included in the suture line. Both SMA and splenic artery should be at the same level. The splenic artery usually needs only trimmed on the edges. The options for the Y graft conduit include brachiocephalic trunk, common carotid artery bifurcation, aortic bifurcation, but the most commonly used is the donor common iliac with the external and internal iliac artery. The conduit should be carefully dissected to remove all the periadventitial tissue. The conduit is checked for any leaks especially a vasa vasorum, which is invariably present at the angle of bifurcation. This needs to be ligated. The external iliac artery is anastomosed to SMA and internal iliac artery to the splenic artery. The most essential thing in Y graft reconstruction is

the appropriate length of Y limbs and the orientation of the graft. If the Y limbs are too short, it may cause tension at the suture line and if too long it can lead to kinking and extrinsic compression. The conduit is laid at 60 degree to the pancreas before dividing. Ideally, the external iliac artery stump should be longer than the internal iliac artery stump. The appropriate alignment has to be ensured and torsion of the limbs and tension on the anastomosis should be avoided. One can use either interrupted or continuous suture 5-0 prolene for SMA and 6-0 prolene for splenic artery. One can pass an infant test catheter especially for splenic artery anastomosis to prevent narrowing of the anastomosis.



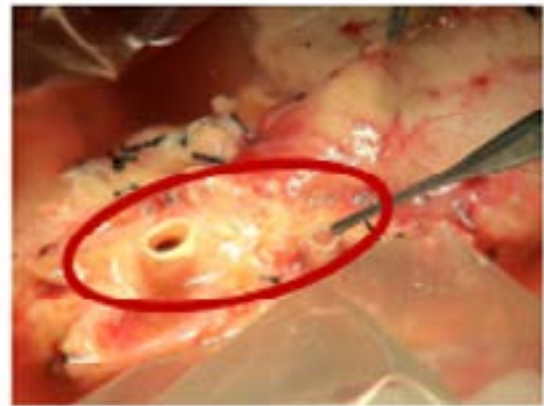


**Figure 11**

Checking for potential bleeding – this step is of paramount importance as time spent here avoids significant post reperfusion blood loss and repercussions. There are 7 areas, which should be looked for bleeding (flooding). These include:

- Two reconstruction sites on Y graft
- Tail of pancreas
- IMV, middle colic vessels
- Root of mesentery
- Peri SMA and portal vein area – these are the most important areas.

The Y graft should be gently flushed to check for bleeds and also to once again ensure the integrity of the arterial arcade. The GDA should be transfixed and ligated with a prolene suture. The above 7 plus two anastomoses on implantation make up 9 points to look for post reperfusion bleeding.



**Figure 12**

In summary, enough time should be spent on the back bench. A methodical approach should be used with attention to details. Minimal handling of pancreas. One must be aware of pitfalls in collateral circulation and vascular reconstruction.