Acta Scientific Pharmaceutical Sciences (ISSN: 2581-5423)

Volume 9 Issue 11 November 2025

Editorial

Elemental and Ingrained-Enchondroma

Anubha Bajaj*

Department of Histopathology, Panjab University/A.B. Diagnostics, India

***Corresponding Author:** Anubha Bajaj, Department of Histopathology, Panjab University/A.B. Diagnostics, India.

Received: August 11, 2025

Published: October 15, 2025

© All rights are reserved by **Anubha Bajaj.**

Enchondroma configures as a benign, hyaline cartilaginous tumour arising within medullary cavity of bone. Neoplasm demonstrates an indolent clinical course and is comprised of an abundant cartilaginous matrix. However, the alternative terminology of chondroma is not recommended.

Classically, a morphological pattern of deposition of bone encasing neoplastic lobules is observed. Foci of tumour infiltration of bony cortex and soft tissue extension appear absent. Tumefaction appears devoid of cytological atypia or discernible mitotic figures.

Neoplasms confined to small bones or configuring as a component of enchondromatosis appear cellular and may display cellular and nuclear atypia.

Enchondroma configures ~20% of cartilaginous tumours and follows osteochondroma (~30%) in frequency. Generally, individuals between 20 years to 50 years delineate the lesion. An equivalent gender predisposition is encountered [1,2].

Lesions are confined to miniature phalangeal bones and neoplasm may appear as a component of enchondromatosis.

Enchondromatosis manifests with multiple enchondromas and commonly configures as a component of Ollier's disease and Maffucci's syndrome [1,2].

Ollier disease demonstrates an asymmetric disposition of multiple enchondromas confined to the appendicular skeleton. Typically, short and long bones of upper and lower extremities are implicated. Tumours confined to epiphyses may prohibit evolution of normal bone, especially within young subjects [1,2].

Maffucci's syndrome expounds multiple enchondromas in concurrence with soft tissue and visceral haemangiomas or lymphangiomas [1,2].

Generally, enchondroma emerges as a solitary lesion. Neoplasm is confined to centric and metaphyseal region of tubular bones, preferentially small bones of hand and feet followed in frequency by femur and humerus. Lesion is uncommonly confined to flat bones. Enchondroma configures as a frequently discerned primary bone tumour arising upon the hand.

Neoplasms arising within the hands are commonly confined to the proximal phalanges [2,3].

Neoplasm depicts elevated levels of D-2-hydroxyglutarate (D-2-HG), a feature which is expounded within diverse cartilaginous tumours delineating IDH1 or IDH2 chromosomal mutations.

D-2-hydroxyglutatrate enhances chondrogenic differentiation and prohibits osteogenic differentiation of mesenchymal stem cells during skeletal genesis [2,3].

Enchondroma depicts heterozygous somatic mutations within IDH1 and IDH2 genes. Around ~40% of sporadic enchondromas and ~80% of enchondromas configuring as a component of Ollier's disease and Maffucci's syndrome display aforesaid genomic mutations. Exceptionally, mutant PTH or PTHrP type I receptor may be encountered within lesions of enchondromatosis [2,3].

Molecular assessment of enchondroma appears superfluous and is exceptionally employed. Nevertheless, hotspot genetic mutations are singularly encountered within IDH1 p.Arg132 and IDH2 p. Arg172 chromosomal positions. Singular genomic mutation analysis appears inadequate in demarcating enchondroma from atypical cartilaginous tumour/chondrosarcoma grade I [2,3].

Common clinical manifestations appear as pain, swelling and skeletal deformity. Up to 60% subjects depict pathological fractures upon initial disease representation. Notwithstanding, several neoplasms are discovered incidentally upon cogent radiographic imaging [3,4].

Grossly, tissue samples obtained from tumour curettage are comprised of fragmented, bluish white, glistening, cartilaginous tissue commingled with fragments of medullary bone. Comprehensive surgical resection of the neoplasm is infrequent wherein tissue samples demonstrate a well circumscribed, multinodular, whitish/blue or whitish/yellow neoplasm confined to medullary cavity of the bone along with an intact superimposed bone cortex [3,4].

Upon microscopy, the hypo-cellular enchondroma demonstrates an abundant, hyaline cartilaginous matrix with multinodular or confluent tumour architecture. Neoplastic cells are uniformly disseminated and appear enmeshed within lacunar spaces. Tumour cells are imbued with eosinophilic cytoplasm, miniature, spherical, lymphocyte-like nuclei and condensed nuclear chromatin [3,4].

Neoplasm represents as diverse cellular cartilaginous nodules circumscribed by bone, a phenomenon designated as 'encasement', which is indicative of gradual tumour progression. Fragments of normal bone marrow appear disseminated between cartilaginous nodules.

Tumefaction appears devoid of cytological atypia and mitotic figures. However, degenerative alterations as ischemic necrosis or calcification appear predominant [3,4].

Occasionally, tumour cells delineate open nuclear chromatin and miniature nucleoli. Binuclear cells may be observed.

Enchondroma appears to lack the capacity to invade and decimate bony cortex, enmesh pre-existent lamellar bone or display tumour extension into circumscribing soft tissue [3,4].

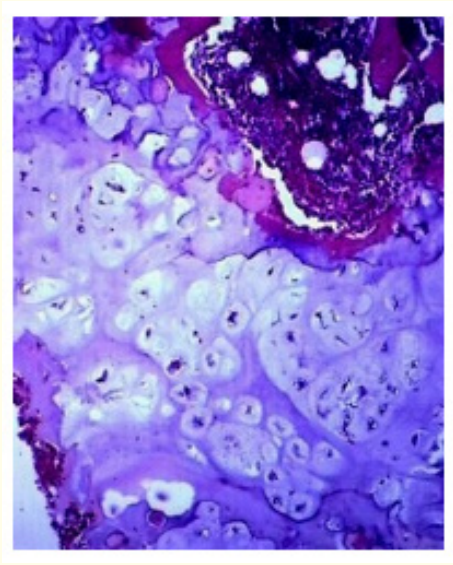

Figure 1: Enchondroma delineating as a lobular neoplasm composed of fragments of cartilaginous matrix devoid of cytological atypia. Foci of calcification are discerned [7].

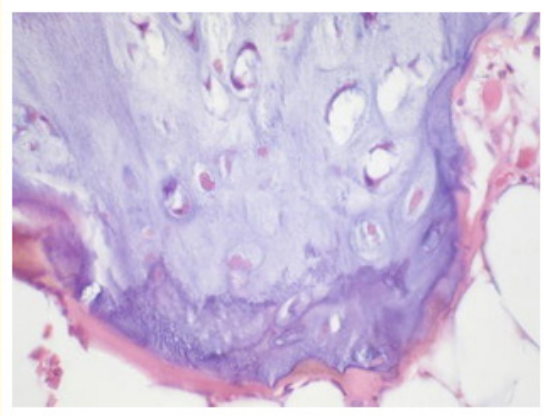

Figure 2: Enchondroma expounding as a lobular tumour constituted of cartilaginous fragments lacking cytological atypia. Circumscribing bone and fragments of fibro-connective tissue are observed [8].

Grade I
Low grade central osteosarcoma
Clear cell chondrosarcoma
Grade I chondrosarcoma
Parosteal osteosarcoma
Adamantinoma
Grade II
Periosteal osteosarcoma
Grade II chondrosarcoma
Grade III
Conventional osteosarcoma
Telangiectatic osteosarcoma
Small cell osteosarcoma
Secondary osteosarcoma
High grade surface osteosarcoma
Malignant giant cell tumour
Ewing sarcoma
Grade III chondrosarcoma
Mesenchymal chondrosarcoma
Dedifferentiated chondrosarcoma

Table 1: Grading of bone tumours [4,5].

Enchondroma appears immune reactive to S100 protein, β oestrogen receptor and GADD45β.

Tumour cells appear immune non reactive to brachyury [4,5].

Enchondroma requires segregation from neoplasms as central atypical cartilaginous tumour/chondrosarcoma grade I, bone infarct, intraosseous ganglion, various benign bone neoplasms associated with osteolytic lesions, distant metastasis into bone with configuration of osteolytic lesions, granulomatous inflammation, skeletal sarcoidosis and tuberculosis of skeletal system [4,5].

Enchondroma may be appropriately discerned with concurrence of clinical symptoms, radiographic features and morphological assessment [5,6].

Enchondroma necessitates precise differentiation from atypical cartilaginous tumour/chondrosarcoma grade I (ACT/CS1). Characteristically, enchondroma delineates non aggressive radiographic and histological features along with indolent tumour progression and absence of bone permeation [5,6].

Upon imaging, enchondroma typically appears as a well defined, solitary defect confined to metaphyseal region of bones, especially long bones. Radiographic countenance is contingent to tumour location and extent of calcification [5,6].

Tumour calcification appears as fine, punctate stippling which may be appropriately discerned upon cogent radiographic imaging.

Enlarged lesions may induce endosteal scalloping along with expansion and attenuation of bony cortex [5,6].

Significantly calcified lesions may simulate bone infarct or bone islands whereas a non calcified lesion may emerge as an osteolytic lesion. Computerized tomography (CT) appears beneficial in enunciating mineralization of bony matrix and integrity of bony cortex [5,6].

Magnetic resonance imaging (MRI) appears advantageous in delineating features of tumour aggression and bone destruction.

Manifestations as progressive destruction of chondrite matrix due to an expansible, non mineralized tumour component, an enlarging lesion associated with pain or an expansible soft tissue mass appears indicative of malignant metamorphosis of an enchondroma [5,6].

MRI appears beneficial in precisely evaluating the neoplasm and emergence of soft tissue tumour extension.

Enchondroma configures as a well circumscribed, lobulated tumour mass replacing the bone marrow.

T1 weighted imaging depicts minimal to intermediate signal intensity. Internal foci of decimated signal delineating 'rings' and 'arcs' appear characteristic of a chondroid matrix [5,6].

T2 weighted imaging preponderantly expounds hyper-intense and well defined sequences as constituent cartilage configures as hydrophilic tissue with significant water content.

Internal foci of minimal signal intensity comprised of 'rings' and 'arcs' are pathognomonic of chondroid matrix. Bone marrow or soft tissue oedema appears absent [5,6].

T1 weighted imaging with gadolinium contrast delineates image enhancement with scalloped margins and curvilinear trans-lesional fibrous tissue septa, a feature designated as "rings' and 'arcs' image enhancement.

However, an identical pattern of image enhancement may be encountered within chondrosarcoma. Therefore, distinction of enchondroma from morphologically identical low grade chondrosarcoma may be challenging [5,6].

Enhanced uptake of radiotracer may be observed upon bone scan of enchondroma wherein intense uptake is engendered due to concordant pathological fracture or cortical expansion of lesions confined to small bones [5,6].

Asymptomatic enchondroma may be subjected to watchful observation. Asymptomatic enchondroma may be subjected to meticulous monitoring and active therapy appears superfluous [5,6].

Characteristically, symptomatic enchondroma may be managed with diverse surgical procedures as simple curettage with bone grafting.

Enchondroma of extended duration as discerned upon cogent radiography may demonstrate tumour progression. Malignant metamorphosis appears exceptional and emerges in non syndromic lesions as observed within < 1% tumours [5,6].

Malignant metamorphosis into a chondrosarcoma configures as a preponderant complication of enchondromatosis as encountered with conditions as Ollier's disease and Maffucci's syndrome.

Possible malignant metamorphosis occurs in up to 45.8% subjects with Ollier's disease and ~57% individuals with Maffucci's syndrome [5,6].

Bibliography

1. Biondi NL., *et al*. "Enchondroma". Stat Pearls International. Treasure Island, Florida (2025).
2. Prahm C., *et al*. "Long-term Follow-up Study for Fractured and Non-Fractured Hand Enchondromas Treated by Sole Curettage". *Archives of Plastic Surgery* 52.3 (2025): 137-144.
3. Pietramala S., *et al*. "Surgical Treatment of Enchondromas of the Hand: Our Experience in Curettage Only and Early Mobilization". *Diseases* 13.3 (2025): 84.
4. Ha C., *et al*. "Early Single-Stage Curettage and Autogenous Bone Grafting for Enchondroma in the Hand with Minimally Displaced Pathologic Fracture". *Clinics in Orthopedic Surgery* 17.1 (2025): 174-180.
5. Jeys LM., *et al*. "Controversies in orthopaedic oncology". *Bone Jt. Journal* 106 (2024): 425-429.
6. Hewitt C., *et al*. "Case Report of a Distal Phalanx Interosseous Epidermoid Inclusion Cyst Presenting as an Enchondroma". *Journal of Orthopaedic Case Reports* 12 (2022): 62-65.
7. Image 1 Courtesy: Orthobullets.com.
8. Image 2 Courtesy: Springer link.