

Hypothesis on Cadaveric Urinary Bladder Transplantation in a Radical Cystectomy, An Alternative Option of Ileal Conduit

Dattatreya Mukherjee*

MBBS Student at Jinan University, P.R China

*Corresponding Author: Dattatreya Mukherjee, MBBS Student at Jinan University, P.R China.

Received: November 30, 2020

Published: January 02, 2020

© All rights are reserved by **Dattatreya Mukherjee.**

Abstract

In Radical Cystectomy the urinary bladder is fully resected and in ileal conduit the ureter is joined with a ileal part and drained outside the abdominal wall. It's a technique of urinary diversion. This procedure has many adverse effects and its also tough for the patients to drain the urine through abdominal wall. So my hypothesis is to use a cadaveric bladder as a transplantation. Now the challenge will arise how to control urge of urination. For that artificial urinary bladder sphincter can be used with the neural regeneration procedure which is under research work. WNT/Beta pathway and Tissue genetic techniques have shown the peripheral neural regeneration.

Keywords: Radical Cystectomy; Urinary Bladder; Ileal Conduit

Introduction

Radical Cystectomy is a procedure where the urinary bladder is totally resected. Along with urinary bladder, prostate and seminal vesicles are also resected [1]. In ileal conduit the two ureter are joined with a small ileal part and drained out from the abdominal bladder.

Urinary Bladder are a part of excretory system. It a hollow muscular organ with detrusor muscles. It present behind the pubic symphysis. The urinary bladder has a normal capacity of 400-600 ml. Thoraco-lumber (T10-L2) and sacral(S2-S4) nerves controls the urinations.

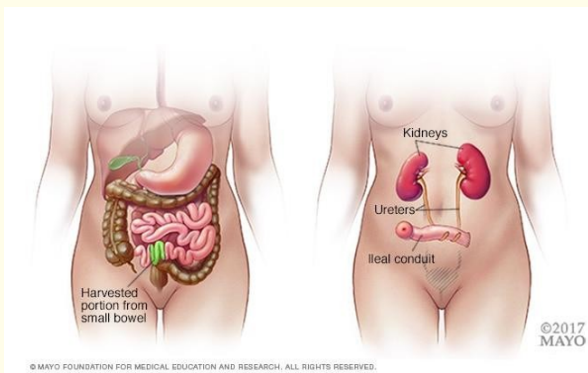


Figure 1: Taken from Ileal Conduit article from Mayo Clinic [2].

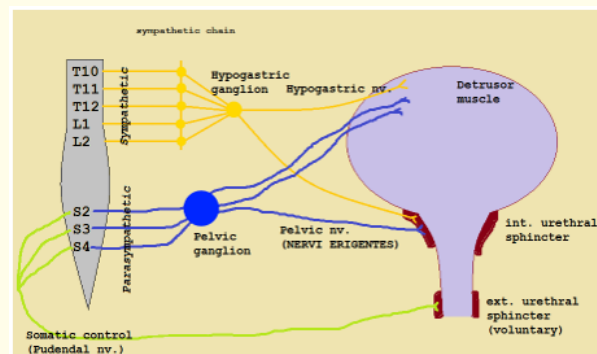


Figure 2: Nerve innervation in Bladder, Sakuntala PGME notes, Google Image [3].

Hypothesis

In this hypothesis I want to state an alternative pathway of ileal conduit, that is cadaveric urinary bladder transplantation. Here from the cadaver the urinary bladder will be taken, then all the matching process will be done like MHC 1 and MHC 2 factors. After that the ureter will be placed with the urinary bladder and urinary bladder will be placed in the normal position. For the sphincter activity the artificial sphincter will be placed. Robot assisted implantation of an artificial urinary sphincter, AMS 800 can be placed via posterior approach in the neck of the urinary bladder [4].

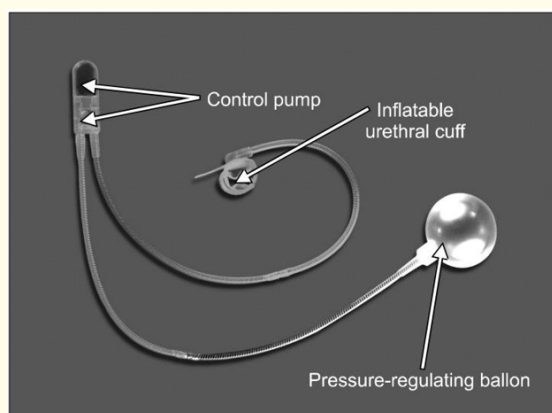


Figure 3: The Artificial Urinary sphincter made by American medical System [5].

A paper of Xiaosong Gu., *et al.* stated that, “Tissue engineered nerve grafts (TENGS) have emerged as a potential alternative to autologous nerve grafts, the gold standard for peripheral nerve repair. Typically, TENGs are composed of a biomaterial-based template that incorporates biochemical cues. A number of TENGs have been used experimentally to bridge long peripheral nerve gaps in various animal models, where the desired outcome is nerve tissue regeneration and functional recovery” [6].

So the Sphincter activity and neural regeneration are possible although this needs many many researches. Ileal Conduit has a complication [5] like stricture, reflux of urine, resorption of solutes and risk of malignancy. Apart from this Ileal Conduit can show absorption malfunction, diarrhea as a ileal part is resected.

Discussion

In future urinary bladder transplantation will be possible and it can an alternative of ileal conduit in the radical cystectomy surgery.

More researches are needed in sphincter activity and neural regeneration techniques. DNA nanotechnology based urinary nerve de-generation may be possible in future. This will also some adverse effect like organ rejections. For that immune matching should be done. In the bladder platinum can be used to hide it from the immune system and immune-compressive drugs will be prescribed.

Conclusion

This hypothesis will be true in future and for this more and more research is needed so we have to work together. If it is possible then it will be a possible alternative in Ileal conduit surgery in radical cystectomy case.

Bibliography

1. Bladder removal Surgery. Mayo Clinic.
2. Ileal Conduit. Mayo Clinic.
3. Sakuntala PGME notes, Google Images.
4. Gondran-Tellier B., *et al.* “Robot-assisted implantation of an artificial urinary sphincter, the AMS-800, via a posterior approach to the bladder neck in women with intrinsic sphincter deficiency”. *BJU International* 124.6 (2019): 1077-1080.
5. Beilly and Love. A short Practice of Surgery, Short practice of surgery, Edition 27, part 2, page 1431.
6. Gu X., *et al.* “Neural tissue engineering options for peripheral nerve regeneration”. *Biomaterials* 35.24 (2014): 6143-6156.

Assets from publication with us

- Prompt Acknowledgement after receiving the article
- Thorough Double blinded peer review
- Rapid Publication
- Issue of Publication Certificate
- High visibility of your Published work

Website: www.actascientific.com/

Submit Article: www.actascientific.com/submission.php

Email us: editor@actascientific.com

Contact us: +91 9182824667