



Iatrogenic Hyponatremia Following Levetiracetam, About a Case

Yassine Smiti*, Abdelilah Ghannam, Oussama Chakib, Fatima Ouchkat, Brahim El Ahmadi, Abdelmjid Moussaoui and Mustapha Alilou

Anaesthesiology and Care Unit Department, Mohamed V University, Rabat, Morocco

*Corresponding Author: Yassine Smiti, Anaesthesiology and Care Unit Department, Mohamed V University, Rabat, Morocco

Received: September 17, 2019; Published: September 23, 2019

DOI: 10.31080/ASPS.2019.03.0402

Abstract

Introduction: Hyponatraemia (plasma sodium less than 136 mmol/L) is the most common electrolytic disorder in hospitalized patients, occurring in almost 30% of them and affecting the elderly more frequently.

Case: We report the case of a hospitalized patient with meningeal haemorrhage of aneurysmal origin, having undergone clipping, and who presented during her hospitalization a hyponatremia refractory despite the correction.

Discussion: In the literature, we found that the hyponatremia can complicate meningeal hemorrhage, due either to inappropriate secretion of antidiuretic hormone (SIADH) or to salt loss syndrome.

In our case we supposed that the cause of the hyponatremia was not the meningeal hemorrhage but the use or the association of some drugs because we found that Nearly three quarters of hyponatraemic drugs are used for the nervous or cardiovascular system, antineoplastics or immunomodulants.

Levetiracetam use has many side effects, but hyponatremia is very rarely seen. In the literature, only 3 cases of levetiracetam-induced hyponatremia have been described. The authors attributed hyponatremia to levetiracetam-induced SIADH, and recovery was observed as soon as the drug was discontinued.

In SIADH, there is hyponatremia and hypoosmolality with urinary osmolality of 100 mosm/kg, resulting from inappropriate secretion of antidiuretic hormone, resulting in impaired water excretion. Increasing age, female gender and low body weight are risk factors for the development of SIADH.

The management of hyponatremia consist on the treatment of etiology with the correction of the disturbance of serum sodium. In our case, once the drug was stopped, the resulting SIADH recovers.

Conclusion: The present case draws attention to LEV as a possible cause of SIADH. Vigilance is necessary because the recognition of this situation allows a correct management and the prevention of possible serious adverse events.

Keywords: Hemorrhage; SIADH; Hyponatraemia

Introduction

Hyponatraemia (plasma sodium less than 136 mmol/L) is the most common electrolytic disorder in hospitalized patients, occurring in almost 30% of them and affecting the elderly more frequently [1].

We report the case of a hospitalized patient with meningeal hemorrhage of aneurysmal origin, having undergone clipping, and who presented during her hospitalization a hyponatremia refractory despite the correction.

Observation

Ms. X patient aged 53, without medical or surgical history, no known allergy, admitted to the emergency room for acute headache complicated with nausea and vomiting.

At admission, the examination found an afebrile patient, sleepy, without deficit, equal and reactive pupils

glasgow score at 13, no notion of convulsion. A blood pressure at 159/99 mmHg, a heart rate of 108 bpm, a FR at 22 c/min and a SpO₂ at 92% in the ambient air, without particularities in the cardiothoracic auscultation. The rest of the exam was without particularities.

A cerebral CT scan was performed urgently and revealed a subarachnoid hemorrhage leading to aneurysm rupture of the left anterior communicating. CT angiography revealed the rupture of the aneurysm and proposed the patient to endovascular treatment.

Preoperative biological assessment was normal, as well as the chest X-ray and the electrocardiogram.

Embolization was performed without incident the day after the appearance of the symptomatology.

Within 24 hours after the neuroradiological intervention, the patient presented a neurological aggravation with generalized tonic-clonic convulsions, controlled by midazolam. A cerebral CT scan revealed rebleeding.

The patient was sedated for 48 hours and put under levetiracetam at a dose of 10 mg/kg in addition to basic resuscitation treatments (parenteral then enteral feeding, basal diet, gastric protection, prophylactic anticoagulation after stabilization of bleeding) and nursing.

The patient presented a pneumopathy acquired by mechanical ventilation, in the culture presence of *Pseudomonas aeruginosa*, for which it was put under imipenem (3 g every 8 hours for 10 days) and amikacin (1g per day for 3 days).

At the 6th day of her hospitalization, the patient installed a hypoosmolar hyponatremia at 129 mmol/l for which a hydroelectrolytic supplementation was set up without improvement. Then the sodium was administered by the autopoussée syringe at the dose of 10 g/day in addition to the nutritional contributions, but without improvement.

At the 11th day, the sodium level was 118 mmol/l. It has been decided to replace levetiracetam with sodium valproate. The sodium level returned to normal 2 days later as it is specified on the kinetic curve of natremia.

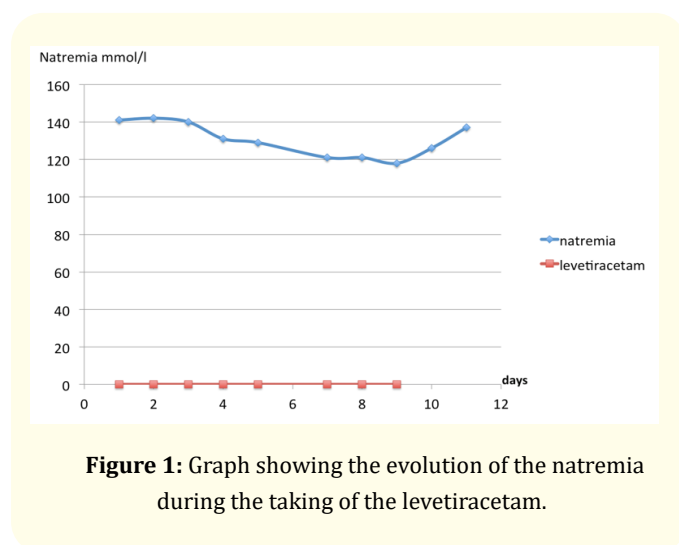


Figure 1: Graph showing the evolution of the natremia during the taking of the levetiracetam.

Discussion

Hypotonic hyponatremia is the most frequent electrolyte disorder encountered in general hospitals. Its mean prevalence at admission is approximately 2% to 4%, increasing to approximately 5% among inpatients. The causes of hypotonic hyponatremia are extremely varied and frequently iatrogenic.

Symptoms depend chiefly on the magnitude and rapidity of onset of the hyponatremia. Acute (i.e. occurring within a period of 24-48 hours), severe hyponatremia induces a dramatic condition as the result of cranial hypertension [2].

Hyponatremia has been associated with increased mortality [3].

Meningeal hemorrhage and Hyponatremia

In the literature, we found that the hyponatremia can complicate meningeal hemorrhage. It is usually deferred between the fourth and the tenth day. In cases of hyponatremia, hypovolemia is sought, as well as an increase in natriuresis. Hyponatremia in meningeal hemorrhage is due either to inappropriate secretion of antidiuretic hormone (SIADH) or to salt loss syndrome [4].

The majority of convulsions during meningeal hemorrhage are early by cerebral hypoperfusion and are associated with poor neurologic prognosis. The incidence of late epilepsy (more than two weeks after securing the aneurysm) is not well defined, but appears to be around 4.9% [5]. Patients who have a high WFNS score at entry have a higher risk of having seizures. No formal data are available to rule on antiepileptic prophylaxis [6].

Hyponatremia and antiepileptic drugs

Nearly three quarters of hyponatraemic drugs are used for the nervous or cardiovascular system, antineoplastics or immunomodulants.

Three general mechanisms have been proposed to explain this syndrome, mainly by the SIADH (inappropriate secretion of the antidiuretic hormone ADH), by the potentiation of the effect of ADH in the renal medullaries or by reinitialization of the osmosensor of the extracellular fluid with decrease of the secretion threshold of ADH.

The drugs that are commonly associated with the occurrence of SIADH are antidepressants (tricyclics, MAOIs, venlafaxine), antipsychotics (phenothiazines, haloperidol), antiepileptics, anti-cancer drugs (vincristine, vinblastine, cisplatin, carboplatin, cyclophosphamide, ifosfamide) [7].

Levetiracetam (LEV) is a novel AED that is used to treat adults and children over 4 years old with partial seizures [8].

Levetiracetam use has many side effects, but hyponatremia is very rarely seen. In the literature, only 3 cases of levetiracetam-induced hyponatremia have been described. The authors attributed hyponatremia to levetiracetam-induced SIADH, and recovery was observed as soon as the drug was discontinued. When hyponatremia is diagnosed in patients with chronic diseases, especially in multidrug users, we should therefore carefully investigate and

dismiss other underlying causes that may reverse the condition before correcting blood Na [9].

however the association LEV - hyponatremia was rarely reported. In SIADH, there is hyponatremia and hypoosmolality with urinary osmolality of 100 mOsm/kg, resulting from inappropriate secretion of antidiuretic hormone, resulting in impaired water excretion. Increasing age, female gender and low body weight are risk factors for the development of SIADH [10].

Management of hyponatremia

The management of hyponatremia consist on the treatment of etiology with the correction of the disturbance of serum sodium.

In the case of hypovolemic hyponatremia, the administration of an iso-osmolar saline solution is necessary. If it's an euvoletic hyponatraemia, fluid restriction is recommended. and for the hypervolemic hyponatraemia, must initiate water and sodium restriction [6,11].

In case of acute hyponatremia, a 3% NaCl hyperosmolar solution can be administered intravenously at a flow rate of 100 ml/h, in order to increase the sodium concentration by 2 mmol/L/h [6]. However, the correction speed must be adapted mainly to the speed of onset of the disease [12]. Ideally, serum sodium should not increase more than 9 mmol/L in 24 hours and maximum 10 to 12 mmol/L in 24 hours, to avoid the onset of centropontine myelinolysis [11,12].

We shouldn't forget that hyponatremia may simply be a side effect of a drug. The biological assessment, in particular with the calculation of the plasma osmolality, makes it possible to orient the diagnosis towards the drug [13].

Once the drug is stopped, the resulting SIADH recovers. The present case draws attention to LEV as a possible cause of SIADH. Vigilance is necessary because the recognition of this situation allows a correct management and the prevention of possible serious adverse events [10].

Conclusion

Hyponatremia is common and its etiology may simply be a side effect of a drug. The biological assessment, in particular with the calculation of the plasma osmolality, makes it possible to orient the diagnosis towards the drug.

The present case draws attention to LEV as a possible cause of SIADH. Vigilance is necessary because the recognition of this situation allows a correct management and the prevention of possible serious adverse events.

Consent Statement

Written informed consent was obtained from the patient for publication of this article.

Conflict of Interest

Authors declare no conflict of interest.

Bibliography

1. Upadhyay A., *et al.* "Incidence and prevalence of hyponatremia". *The American journal of medicine* 119 (2006): S30-S35.
2. Renneboog B., *et al.* "Mild chronic hyponatremia is associated with falls, unsteadiness, and attention deficits". *The American Journal of Medicine* 119 (2006): 71.e1.
3. Elhassan E A and Schrier R. W. "Hyponatremia: diagnosis, complications, and management including V2 receptor antagonists". *Current opinion in nephrology and hypertension* 20 (2011): 161- 168.
4. Mori T., *et al.* "Improved efficiency of hypervolemic therapy with inhibition of natriuresis by fludrocortisone in patients with aneurysmal subarachnoid hemorrhage". *Journal of Neurosurgery* 91 (1999): 947-952.
5. Buczacki SJ., *et al.* "Late epilepsy following open surgery for aneurysmal subarachnoid haemorrhage". *Journal of Neurology, Neurosurgery, and Psychiatry* 75 (2004): 1620-1622.
6. Severe subarachnoid hemorrhage. Expert Conference; Paris, France (2004).
7. Liamis G., *et al.* "A review of drug-induced hyponatremia". *American Journal of Kidney Diseases* 52 (2008): 144-153.
8. Xi Lu and Xuefeng Wang. "Hyponatremia induced by antiepileptic drugs in patients with epilepsy". *Expert Opinion on Drug Safety* (2016).
9. Hatem Arı MD., *et al.* "The first case of levetiracetam-induced and tolvaptan-resistant hyponatremia". *Turkish Society of Cardiology* 43.3 (2015): 284-287.
10. Elena Cecilia Rosca. "Mihaela Simu : Levetiracetam-induced hyponatremia". *Acta Neurologica Belgica* (2018): 123 - 124.
11. Cherpillod A and Vollenweider P. "Differential diagnosis and management of hyponatremia.Revue médicale Suisse". 294 (2011): 1054-1055.
12. Diane Lévy-Chavagnat. "New-generation antiepileptics, the imperative tolerance; Actualité pharmaceutique (2018): 17-21.
13. Ivan Fenoglio., *et al.* Hyponatraemia of medicinal origin, About a series of 54 cases reported in the Regional Pharmacovigilance Center of Saint-Etienne: *Thérapie* 66 (2011): 139-148.

Volume 3 Issue 10 October 2019

© All rights are reserved by Yassine Smiti., *et al.*