



An Updated Review on Types of Brain Tumor

D Varshith^{1*}, K Prasanna Lakshmi¹, K Maniraju¹, G Chandu Priya¹, B Venkateswara Reddy² and A Padma³

¹B.Pharmacy, Sankar Reddy Institute of Pharmaceutical Sciences, AP, India

²Professor, Department of Pharmaceutics, Sankar Reddy Institute of Pharmaceutical Sciences, AP, India

³Assistant Professor, Department of Pharmaceutical analysis, Sankar Reddy Institute of Pharmaceutical Sciences, AP, India

***Corresponding Author:** D Varshith, B.Pharmacy, Sankar Reddy Institute of Pharmaceutical Sciences, AP, India.

Received: June 05, 2020

Published: December 30, 2020

© All rights are reserved by **D Varshith., et al.**

Abstract

Brain tumours represent a group of neoplasms arising from brain tissue each with their own unique biology prognosis and treatment. Included in these groups are neoplasms not arising from brain parenchyma's which encompass meningioma's lymphomas and metastatic disease from other primary sources. Despite the diverse group of neoplasms represented, most intracranial tumours follow similar clinical presentations and diagnostic workups methods. The majority of primary brain tumours fall under the WHO classification scheme of tumours of neuro epithelial tissue. There are over 120 brain tumour classifications defined by the WHO, based on the tumour cell type and location, making this a very complex diagnosis. The present review mainly described that diagnosis and therapeutic advancements of few types of brain tumors.

Keywords: Brain Tumor; Neoplasm; Brain Parenchyma; Lymphoma; Metastatic

Introduction

A brain tumour is a collection of abnormal cells that grows in or around the brain. Tumours can directly destroy healthy brain cells by invading them. They can also indirectly damage healthy cells by crowding other parts of the brain and causing inflammation, brain swelling and pressure within the skull. Brain tumours are either malignant or benign. A malignant tumour, also called brain cancer, usually grows rapidly and often invades or crowds healthy areas of the brain. These tumours also steal the blood supply of a normal brain. Benign brain tumours do not contain cancer cells and are usually slow growing [1]. Malignant brain tumours fall into two different categories: primary or metastatic. Primary brain tumours begin within the brain. A metastatic tumour is formed when cancer cells located elsewhere in the body break away and travel to the brain. Brain tumours are classified based on where the tumour is located, the type of tissue involved, whether the tumour is

benign or malignant, and other factors. If a tumour is determined malignant, the tumour cells are examined under a microscope to determine how malignant they are. Markers that reflect genetic mutations (gene defects) which can predict tumour behaviour and their response to therapy are now tested for routinely. Based on this analysis, tumours are rated, or graded, by their level of malignancy from least to most malignant. Factors that determine the tumour grade include how fast the cells are growing, how much blood is supplying the cells, the presence of dead cells in the middle of the tumour (necrosis), if the cells are confined to a specific area, and how similar the cancerous cells are to normal cells. Many of these tumour characteristics can also be predicted by their appearance on various imaging tests [2]. The cause of primary brain tumours is unknown. Environmental and genetic factors may cause some brain tumours. Prior exposure to radiation therapy as a child seems to be a contributing cause in very few patients.

Tumour grading

The World Health Organization (WHO) has created a standard by which all tumours are classified. There are over 120 brain tumour classifications defined by the WHO, based on the tumour cell type and location, making this a very complex diagnosis. Tumours are given a name based on the cells where they arise, and a number ranging from 1–4, usually represented by Roman numerals I-IV. This number is called the “grade” and it represents how fast the cells can grow and are likely to spread. This is critical information for planning treatment and predicting outcomes [3]. Lower grade tumours (grades I and II) are not very aggressive and are usually associated with long-term survival. Higher grade tumours (grade III and IV) grow more quickly, can cause more damage, and are often more difficult to treat. These are considered malignant or cancerous.

Grade I tumour

- Slow-growing cells
- Almost normal appearance under a microscope
- Usually not cancer
- Can potentially be cured with surgery

Grade II tumour

- Relatively slow-growing cells
- Slightly abnormal appearance under a microscope
- Can invade adjacent normal tissue
- Can recur as a higher grade tumour

Grade III tumour

- Actively reproducing abnormal cells
- Abnormal appearance under a microscope
- Infiltrate adjacent normal brain tissue.

Grade IV tumour

- Abnormal cells which reproduce rapidly
- Very abnormal appearance under a microscope
- Form new blood vessels to maintain rapid growth
- Areas of dead cells (necrosis) in centre.

Tumours can contain several grades of cells; however, the most malignant cell determines the grade for the entire tumour (even if

most of the tumour is a lower grade). Some tumours can change the way they grow and may become malignant over time. Your doctor can tell you if your tumour might have this potential [4].

Primary brain tumors

A tumour that starts in the brain is a primary brain tumour. Glioblastoma multiforme, astrocytoma, medulloblastoma and ependymoma are examples of primary brain tumours. Primary brain tumours are grouped into benign tumours and malignant tumours [5].

Benign brain tumors

A benign brain tumor consists of very slow growing cells, usually has distinct borders and rarely spreads. When viewed under a microscope, these cells have an almost normal appearance. Surgery alone might be an effective treatment for this type of tumor. A brain tumor composed of benign cells, but located in a vital area, can be considered life-threatening although the tumor and its cells would not be classified as malignant [6].

Malignant brain tumour

A malignant brain tumor is usually rapid growing, invasive and life-threatening. Malignant brain tumors are sometimes called brain cancer. However, since primary brain tumors rarely spread outside the brain and spinal cord, they do not exactly fit the general definition of cancer. Malignant brain tumors that are cancerous can spread within the brain and spine. They rarely spread to other parts of the body. They lack distinct borders due to their tendency to send “roots” into nearby normal tissue [7]. They can also shed cells that travel to distant parts of the brain and spine by way of the cerebrospinal fluid. Some malignant tumors, however, do remain localized to a region of the brain or spinal cord.

Metastatic brain tumors

Cancer cells that begin growing elsewhere in the body and then travel to the brain form metastatic brain tumours. For example, cancers of the lung, breast, colon and skin (melanoma) frequently spread to the brain via the bloodstream or a magnetic-like attraction to other organs of the body. All metastatic brain tumours are, by definition, malignant and can truly be called brain cancer [8].

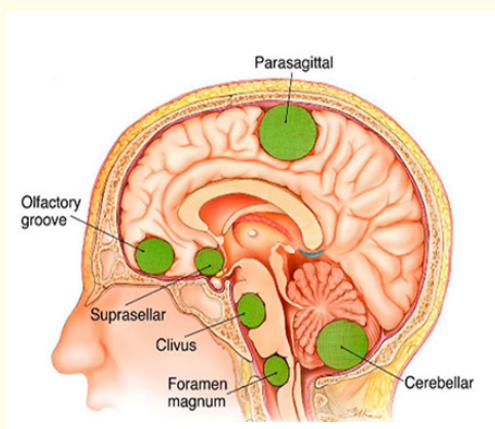


Figure 1: Pictorial representation of Brain tumour.

Symptoms of brain tumour

- Headaches
- Nausea
- Vomiting
- Seizures
- Behaviour changes
- Memory loss Vision or
- Hearing problems.

Types of brain tumour

- Astrocytoma
- Ependymoma
- Medullablastoma
- Neuroblastoma
- Oligodendroglioma and Oligistrocytoma
- Pituitary adenoma

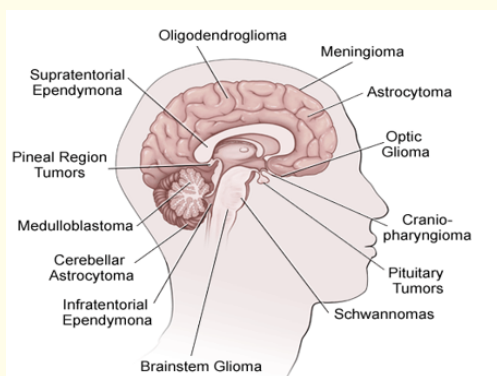


Figure 2: Location of Different types of brain tumours.

Astrocytoma

Astrocytomas are tumours that grow from a type of cell in the brain called an astrocyte. Throughout the brain and spinal cord we all have nerve cells called ‘neurons’, which transmit messages (electrical and chemical signals) to, from and within the brain. Surrounding the neurons are cells called ‘glial cells’, that support and protect the neurons by providing them with oxygen and nutrients and removing dead cells. An astrocyte is a type of glial cell. (There are three main types of glial cells - astrocytes, oligodendrocytes and ependymal cells.) Astrocytes are the most abundant cells in the brain, and as well as supporting and protecting neurons, they also help to pass messages between the neurons and, therefore, are vital in processing information in the brain. Like all cells, astrocytes normally grow in an orderly, controlled manner. However, if this process is upset or disrupted for some reason, they can continue to grow and divide when they shouldn’t, causing a lump (a tumour) to form [9].

Types of astrocytoma

- **Grade 1 Astrocytoma (Pilocytic Astrocytoma):** Grade 1 astrocytomas are called ‘pilocytic astrocytomas’. (Pilocytic means the cells are elongated and look hair-like.) These are slow growing, relatively contained and unlikely to spread to other parts of the brain. They are also unlikely to return after being surgically removed. They are most often found in children and young adults under the age of 20 and are equally common in males and females [10].
- **Grade 2 astrocytoma (Diffuse astrocytoma):** The most common grade 2 astrocytoma is called a ‘diffuse astrocytoma’. (Diffuse means it does not have well-defined edges.) These are slow-growing, but they can sometimes return, following initial treatment, as a higher, grade 3 astrocytoma.
- **Grade 3 astrocytoma (Anaplastic astrocytoma):** A grade 3 astrocytoma is called an ‘anaplastic astrocytoma’. (Anaplastic means the cells divide rapidly and do not resemble normal cells in structure or function.) They are fast-growing and often referred to as malignant or cancerous. They often recur following initial treatment in a more advanced form [11].
- **Grade 4 astrocytoma (Glioblastoma):** Grade 4 astrocytomas are usually referred to by the term glioblastoma. This type of tumors found in glial cells of neurons.

Ependymoma

Any tumor that arises from the glial cells in the brain is called a “glioma.” Glial cells provide support and protection for the nerve cells, or neurons, in the brain. One type of glioma is the ependymoma. Ependymomas arise from ependymal cells that line the ventricles of the brain and the center of the spinal cord. Occasionally, ependymal cells are found within the brain itself. Ependymomas are soft, grayish or red tumours which may contain cysts or mineral calcifications. The words “supratentorial” and “infratentorial” describe the location of the ependymoma within the brain. The tentorium is a thick membrane that separates the top two-thirds of the brain from the bottom third. Supratentorial ependymomas occur above the tentorium [12].

Types of ependymomas

Myxopapillary ependymomas, Subependymomas, Ependymomas and Anaplastic ependymomas. Many pathologists also assign a number “grade” to ependymomas. The grade is based on how much the cells look like normal ependymal cells, although various grading systems exist [13].

- Myxopapillary ependymomas tend to occur in the lower part of the spinal column.
- Subependymomas usually occur near a ventricle. Both are slow growing, and are considered to be low-grade or grade I tumors.
- Ependymomas are the most common of the ependymal tumors, and are considered grade II tumors. These tumors are usually located along, within or adjacent to the ventricular system, often in the posterior fossa or in the spinal cord.
- Anaplastic ependymomas are high-grade tumours (grade III) and tend to be faster growing than low-grade tumors. They most commonly occur in the posterior fossa.

Medulloblastoma

Medulloblastoma is a rapidly-growing tumour of the cerebellum – the lower, rear portion of the brain. Also called the posterior fossa, this area controls balance, posture and complex motor functions such as finer hand movements, speech, and swallowing. Tumours located in the cerebellum are referred to as infratentorial tumours. That means the tumour is located below the tentorium, a

thick membrane that separates the larger, cerebral hemispheres of the brain from the cerebellum [14]. In children, medulloblastoma arises most often near the vermis, the narrow worm-like bridge that connects the cerebellum’s two sides. In adults, this tumour tends to occur in the body of the cerebellum, especially toward the edges. Medulloblastoma is the most common of the embryonal tumours – tumours that arise from “embryonal” or “immature” cells at the earliest stages of their development. Its occurrence was first described in 1925 and its prevalence has largely remained unchanged since its initial description. The anaplastic components often co-exist with large cell components prompting the grouping of such histologic types as Large cell/Anaplastic medulloblastoma. Two other variants, medulloblastoma and melanotic medulloblastoma, are very rare and occur in association with the primary variants described.

Types of medulloblastoma

- **WNT Medulloblastoma:** These tumours often occupy the fourth ventricle; the fluid filled space in the middle of the posterior fossa. At the cellular level these tumours display an accumulation of a protein termed beta- catenin in the nucleus of the cell and frequently delete one copy of chromosome.
- **SHH Medulloblastoma:** SHH medulloblastomas are primarily located in the body of the cerebellum and often seen lateralizing to the sides of the organ. The SHH pathway is crucial for the normal development of the cerebellum, however, in patients with this subgroup of tumour, there is an unrestrained SHH signaling that results in cancer.
- **Group 3 Medulloblastoma:** These tumors are similar to the WNT medulloblastomas the tumour is generally located within the fourth ventricle and may arise from the vermis of the cerebellum. Under the microscope, the cancer cells of this subgroup are most commonly placed in the large cell/anaplastic histologic subtype but classic histology is also seen [15].
- **Group 4 Medulloblastoma:** These tumors are also similar to Group 3 and WNT subgroup tumours these tumours are located in the fourth ventricle. While mostly of the classic histology and not-metastatic, more aggressive, anaplastic, and/or metastatic group 4 tumours are seen in about a third of the patients with this disease.

Oligodendroglioma and oligoastrocytoma

Oligodendroglioma and oligoastrocytoma belong to a group of brain tumours called gliomas. Gliomas are tumors that arise from the glial or supportive cells of the brain. There are several different types of gliomas. Oligodendrogliomas arise from oligodendrocytes are fried egg-shaped cells within the brain. The role of normal oligodendrocytes is to form a covering layer for the nerve fibers in the brain. Oligoastrocytomas are mixed glioma tumours, containing both abnormal oligodendroglioma and astrocytoma cells.

Neuroblastoma

Neuroblastoma is a cancer almost exclusively of childhood. Childhood cancers are usually different from cancers affecting adults. They tend to occur in different parts of the body to adult cancers and look different under the microscope. They also respond differently to treatment. Neuroblastoma is very rare in teenagers, young adults and adults and current treatment is broadly the same as in younger children, but may change in the future. In these patient groups the disease is usually more slow growing. Neuroblastoma is an 'embryonal tumour', a type of cancer that develops from the cells left behind from a baby's development in the womb. Neuroblastoma can occur anywhere in the body. The site of origin is either in one of the two adrenal glands situated in the abdomen (tummy) or in nerve tissue that runs alongside the spinal cord in the neck, chest, abdomen or pelvis [16].

Pituitary tumours

The pituitary gland is a bean-sized organ located in the midline at the base of the brain, just behind the bridge of the nose, in a bony pouch called the sella turcica. The pituitary itself is known as the master gland because it helps to control the secretion of hormones from a number of other glands and target organs in the body. These include the thyroid, adrenals, testes and ovaries. The pituitary gland releases hormones into the blood stream, where they are carried to distant glands or organs in the body. Those distant glands release other hormones which, in turn, feed back to the brain and the pituitary through the bloodstream [17]. The medical term for the most common type of pituitary tumor is pituitary adenoma- adeno means gland, oma means tumor. Most pituitary adenomas develop in the front two-thirds of the pituitary gland. That area is called the adenohypophysis, or the anterior pituitary.

Pituitary tumors rarely develop in the rear one-third of the pituitary gland, called the neurohypophysis or the posterior pituitary. The tumors are almost always benign and most are very successfully treatable.

Diagnosis of brain tumors

Neurological examination

The specialist will ask questions about your health and give you a physical examination. They will also test your nervous system (called a neurological examination). This involves looking at your vision, hearing, alertness, muscle strength, co-ordination, and reflexes. They may also look at the back of your eyes to see if there is any swelling of the optic disc. (The optic disc is where the optic nerve from the brain enters the eye). Any swelling is a sign of raised pressure inside the skull, which could be a sign of a brain tumour.

Scans

You will then have one or more further tests, such as an MRI (magnetic resonance imaging) or CT (computerised tomography) scan to establish whether a brain tumour is present. (For information about these scans, please see the Scans fact sheet). For some people, their first symptom may be a seizure, so they are seen as an emergency. In this case they may be given a scan as their first test, after which their case will be referred to a neuro-oncology 'MDT' (multi-disciplinary team) followed by a consultation with the neurologist/neurosurgeon. Some GPs can refer you for a scan directly, or you may have been admitted to hospital with a problem and a brain scan was arranged to investigate this further. If, following the scan, a tumour is found, you may be given a body scan to establish if your tumour is a primary brain tumour (one which started in the brain) or a secondary tumour and there is a primary tumour elsewhere in the body [18].

Biopsy

If the tumour is a primary tumour and is in an area of the brain which can be operated on, a biopsy (small sample of the tumour) may be taken from your tumour to aid diagnosis of the tumour type. It is important to realise that a biopsy is an operation that takes several hours. Any risks will be explained to you by your surgical team.

Surgery

Alternatively to a biopsy, and if possible, the resection (surgical removal) of the whole tumour, or as much as possible, will be undertaken at the same time. If only part of the tumour can be removed, this is known as 'debulking'.

Bio banking

In both cases of biopsy or surgery, you may like to ask, before your operation, about the possibility of 'biobanking' some of the tissue from your tumour. A key to accelerating research towards improving survival and quality of life for people with brain tumours is for researchers to have access to centralised tissue banks containing patients' tumour samples so they can carry out more research. Currently there is no centralised tissue bank and not all centres are able to take and store samples, as they need to be licenced under the Human Tissue Act, with ethical approvals in place. As a result, routine collection of tissue for research is not yet a reality. The Brain Tumour Charity is committed to establishing a centralised tissue bank with simpler access arrangements. As there are many types of brain tumour, some of which are very rare, we need to ensure that we learn from every patient. This will require systems and cultural changes in the approach to collecting samples. By asking about biobanking some of your tumour, you may help with the move towards this [19]. Speak to us and to your health team if this is something you are interested in doing. Laboratory analysis Following biopsy or surgery, cells from the tumour will be analysed in a laboratory by a neuropathologist. Accurate diagnosis is important as it allows your medical team to give you information about how the tumour could behave in the future, and also to recommend treatment options. This could include a clinical trial.

Biomarker testing

As part of this analysis, you may like to ask about 'biomarker testing'. This is where the doctors look for markers (changes) in certain genes in the tumour cells that may indicate how well you will respond to certain treatments.

Treatment options for brain tumors

Radiation

Radiation therapy is usually recommended for older children (age dependent on the location of the tumour) and adults follow-

ing surgery, even if all visible tumour was removed. The age of the patient, the location of the tumour and whether it has spread are considered in treatment planning [20]. If the tumour is localized, radiation therapy is usually given just to that area of the brain. If the tumour has spread, radiation is usually given to the entire brain and spine, with an extra amount of radiation (called a boost) given to the area of the brain where the tumour started. There are different methods of administering radiation. External beam radiation is given five days a week for six weeks. Conformal beam radiation therapy is a type of external beam radiation that contours the radiation beams to the shape of the tumour. Stereotactic radiosurgery is a way of giving a single or a few high doses of precisely focused radiation to the tumour. This is often used for ependymomas that grow back after conventional radiation. Your doctor will decide which form of radiation is best for you. Because of the long-term side effects of radiating young children, chemotherapy may be used to delay radiation therapy in the very young child. If the tumour grows despite the chemotherapy, radiation therapy may be considered.

Chemotherapy

Chemotherapy uses special drugs to kill tumour cells. Scientists continue to study the role of chemotherapy and when it is best used. It is not clear whether using chemotherapy in the treatment of patients with newly diagnosed ependymomas makes a difference. Some tumours respond to treatment for a while, while others continue to grow. Chemotherapy may also be used to delay radiation for infants and young children, or to treat tumours that have grown back after radiation therapy. It is not clear which chemotherapy drugs are the most effective against ependymomas. Drugs such as cisplatin and carboplatin may cause shrinkage in about half of ependymomas, although not usually for a long time. Either standard chemotherapy, or experimental chemotherapy as part of a clinical trial, are often used for patients whose tumours regrow after radiation [21].

Surgery

Removing as much tumour as possible is an important step in treating brain tumours. The neurosurgeon has three goals for the surgery: to relieve cerebrospinal fluid build-up caused by tumour or swelling; to confirm the diagnosis by obtaining a tissue sample; and to remove as much tumour as possible while causing minimal, or no, neurological damage. In one-third of patients, the tumour grows into the brain stem, making total removal difficult because

of potential neurological damage. If the tumour cannot be totally removed, an operation to resect most of the tumour may still be done to reduce the mass and confirm the diagnosis. Glucocorticosteroids (decadron, dexamethasone) are drugs used before and after surgery to reduce swelling around the tumour. Occasionally, a ventriculostomy (an external drainage device) may be placed to divert excess cerebrospinal fluid from the brain [22].

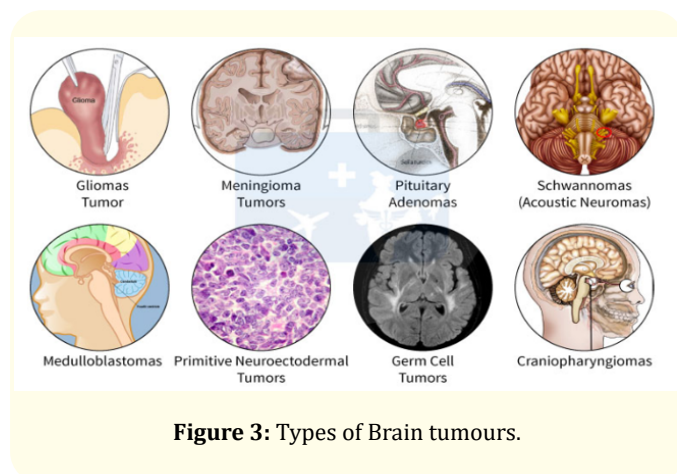


Figure 3: Types of Brain tumours.

Conclusion

A brain tumour is a collection of abnormal cells that grows in or around the brain. It poses a risk to the healthy brain by either invading or destroying normal brain tissue or by compressing and displacing the brain. Approximately 69,720 new cases of primary CNS tumours are expected to be diagnosed in the United States this year. Of these lesions, roughly 24,620 will be malignant. Brain tumors are diagnosed by neurological examination, MRI and CT scans, biopsy and biomarker testing. Early detection of brain tumors can be treated with chemotherapy, surgery, radiation therapy and pharmacological therapy.

Bibliography

- Roux FE., et al. "Methodological and technical issues for integrating functional magnetic resonance imaging data in a neuro-navigational system". *Neurosurgery* 49 (2001): 1145-1156.
- Kim SS., et al. "Awake Craniotomy for Brain Tumors Near Eloquent Cortex: Correlation of Intraoperative Cortical Mapping With Neurological Outcomes in 309 Consecutive Patients". *Neurosurgery* 64 (2009) 836-846.
- Ohgaki H., et al. "Population-Based Studies on Incidence, Survival Rates, and Genetic Alterations in Astrocytic and Oligodendroglial Gliomas". *Journal of Neuropathology and Experimental Neurology* 64 (2005): 479-489.
- Chaichana KL., et al. "Recurrence and malignant degeneration after resection of adult hemispheric low-grade gliomas". *Journal of Neurosurgery* 112 (2010): 10-17.
- Adamson C., et al. "Glioblastoma multiforme: a review of where we have been and where we are going". *Expert Opinion on Investigational Drugs* 18 (2009): 1061-1083.
- Ostrom Q., et al. "Gene markers in brain tumors: what the epileptologist should know". *Epilepsia* 54.9 (2013): 25-29.
- Esteller M., et al. "Inactivation of the DNA-Repair Gene MGMT and the Clinical Response of Gliomas to Alkylating Agents". *The New England Journal of Medicine* 343 (2000): 1350-1354.
- Hegi ME., et al. "Clinical Trial Substantiates the Predictive Value of O-6-MethylguanineDNA Methyltransferase Promoter Methylation in Glioblastoma Patients Treated with Temozolomide". *Clinical Cancer Research* 10 (2004): 1871-1874.
- Hegi ME., et al. "MGMT gene silencing and benefit from temozolomide in glioblastoma". *The New England Journal of Medicine* 352 (2005): 997-1003.
- Mur P., et al. "Codeletion of 1p and 19q determines distinct gene methylation and expression profiles in IDH-mutated oligodendroglial tumors". *Acta Neuropathology* 126 (2013): 277-289.
- Cairncross G., et al. "Phase III Trial of Chemotherapy Plus Radiotherapy Compared With Radiotherapy Alone for Pure and Mixed Anaplastic Oligodendroglioma: Intergroup Radiation Therapy Oncology Group Trial 9402". *Journal of Clinical Oncology* 24 (2006): 2707-2714.
- Van den Bent M., et al. "Adjuvant Procarbazine, Lomustine, and Vincristine Improves Progression-Free Survival but Not Overall Survival in Newly Diagnosed Anaplastic Oligodendrogliomas and Oligoastrocytomas: A Randomized European Organisation for Research and Treatment of Cancer Phase III Trial". *Journal of Clinical Oncology* 24 (2006): 2715-2722.
- Weller M., et al. "Personalized care in neuro-oncology coming of age: why we need MGMT and 1p/19q testing for malignant glioma patients in clinical practice". *Neuro Oncology* 14.4 (2012): iv100-108.
- Yan H., et al. "IDH1 and IDH2 mutations in gliomas". *The New England Journal of Medicine* 360 (2009): 765-773.

15. Parsons DW, *et al.* "An integrated genomic analysis of human glioblastoma multiforme". *Science* 321 (2008): 1807-1812.
16. Dang L., *et al.* "Cancer-associated IDH1 mutations produce 2-hydroxyglutarate". *Nature* 462 (2009): 739-744.
17. Noushmehr H, *et al.* "Identification of a CpG island methylator phenotype that defines a distinct subgroup of glioma". *Cancer Cell* 17 (2010): 510-522.
18. Turcan S., *et al.* "IDH1 mutation is sufficient to establish the glioma hypermethylator phenotype". *Nature* 483 (2012): 479-483.
19. Del Vecchio CA, *et al.* "EGFRIII gene rearrangement is an early event in glioblastoma tumorigenesis and expression defines a hierarchy modulated by epigenetic mechanisms". *Oncogene* 32 (2013): 2670-2681.
20. Batra S., *et al.* "Epidermal growth factor ligand-independent, unregulated, cell transforming potential of a naturally occurring human mutant EGFRvIII gene". *Cell Growth Different* 6 (1995): 1251-1259.
21. Heimberger AB., *et al.* "Prognostic Effect of Epidermal Growth Factor Receptor and EGFRvIII in Glioblastoma Multiforme Patients". *Clinical Cancer Research* 11 (2005): 1462-1466.
22. Ekstrand AJ, *et al.* "Genes for Epidermal Growth Factor Receptor, Transforming Growth Factor α , and Epidermal Growth Factor and Their Expression in Human Gliomas in Vivo". *Cancer Research* 51 (1991): 2164-2172.

Assets from publication with us

- Prompt Acknowledgement after receiving the article
- Thorough Double blinded peer review
- Rapid Publication
- Issue of Publication Certificate
- High visibility of your Published work

Website: <https://www.actascientific.com/>

Submit Article: <https://www.actascientific.com/submission.php>

Email us: editor@actascientific.com

Contact us: +91 9182824667