



Hydrozone Gaseous Arthrodiastesis, EBOO/MAHT, and Low Dose Methotrexate in Ficat Grade 3/4 Avascular Necrosis of Hip Joints in Young Patients

L Prakash^{1*}, Prasham Shah², Aroop Mukharjee³ and Jignesh Patel⁴

¹Orthopaedic Chief, Institute for Special Orthopaedics, Palakkad, Kerala, India

²Consultant Orthopaedic Surgeon, Wokhardt Hospital, Mumbai, India

³Consultant Orthopaedic Surgeon, Max Hospital, New Delhi, India

⁴Professor of Orthopaedics, Government Medical College, Surat, Gujrat, India

*Corresponding Author: L Prakash, Orthopaedic Chief, Institute for Special Orthopaedics, Palakkad, Kerala, India.

DOI: 10.31080/ASOR.2025.08.1051

Received: March 18, 2025

Published: May 27, 2025

© All rights are reserved by L Prakash., et al.

Abstract

The current post COVID era is facing an epidemic of avascular Necrosis of femoral heads [1], largely in younger patients [2], and most patients of FICAT stage 2/3/4 are offered surgical intervention including total hip replacement. This paper is a prospective study of 36 patients with AVN stage 2/3 and 4, treated by the authors' special regimen of Hydrozone gaseous arthrodesis, high ozone dose EBOO (extra corporal blood oxygen ozonisation) or MAHT (Major Auto Haemo Therapy) and a combination of low dose DMARD termed Mukharjee regimen in an attempt to preserve the hip joint and avoid total hip replacement.

Background: Idiopathic avascular necrosis (not related to trauma internal fixation or direct known causes) was 0.4% of the population in 2015 [3], which has now become 6% in 2023 [4,5], a 1500% increase, which is mostly attributed to one of the factors, covid infection, high dose steroids treatment for covid infection or covid vaccination⁴. This prospective study was designed on the premise that if oxygenation to the head could be improved by haematogenous route, decreased joint space could be expanded by gaseous arthrodiastesis, and synovial constrictive proliferative strangulating the vascular supply subdued by methotrexate in very low doses, the progress of AVN could be slowed down and the hip joint could be preserved. This is a prospective study on 36 patients followed up until 18 months.

Methods: 36 patients, 19 males and 17 females between the ages of 21 and 47, with avascular necrosis of their femoral heads, ranging from Ficat grade 2 to 4, were treated with intraarticular Hydrozone injections, Extra corporeal Blood Oxygen Ozonisation, or Major Autohaemotherapy with low dose methotrexate Mukharjee regimen for 18 months. Hydrozone arthrodiastesis and EBOO/ MAHT sessions were repeated every week for three weeks, and then once every four months for four times. The patients were evaluated pre and post treatment of 18 months using VAS scores, Harris Hip score and Oxford Hip score.

Results: The study was a prospective non randomised consecutive analysis of 36 patients, 19 males and 17 females between the ages of 21 and 47. Two patients left the treatment midway through and one patient died due to unrelated reasons. (Accident). Of the remaining 33 patients 29 patients had excellent and 4 patients had good results, with VAS scores coming down from 8-10 to 1-3. The Harris hip score pre therapy was in the range of 60 to 70 improved to 94 to 98. Oxford scores between 15 to 25, became 40 plus after treatment.

Conclusion: Haematogenous ozone, intraarticular hydrozone, and low dose DMARDs are an excellent combination to achieve hip preservation, avoid surgery, and ensure reversal of Hip AVN and produces results superior to core decompression, and Total Hip Replacement, while preserving the patient's natural hip joint.

Keywords: Hydrozone; Hydrogen

Introduction

Molecular hydrogen is the most abundant substance in the universe⁶, but does not exist on our earth in its native molecular form. Experimental, animal models and studies on humans has demonstrated abundant antioxidant activity of the molecule [6].

Ozone is present in the atmosphere in very small quantities, but the ozone layer in the stratosphere is the shield that allows life to exist on the earth [7].

Covid infection, and Covid Vaccination have similar physiological effects producing vascular occlusion and resulting in Avascular Necrosis of organs with precarious blood supply [8].

Low dose Methotrexate, and very low dose steroids, work by inhibiting the rapid cellular proliferation⁹ and will help in opening up closed vascular channels to allow revascularisation of AVN. Bone unlike other tissues is not replaced by fibrous tissue, but is replaced by bone [9].

This new protocol is very effective in grade 2 and 3 of AVN, and acceptably effective in grade 4.

Terminology and procedure details

MAHT is Major Auto Maemo therapy. In a 200 ml of a vacu-utainer borosilicate flint free glass bottle, with anticoagulants, 50

to 60 ml of venous blood blood is collected, and this is ozonised with 50 to 60 cc of 100 micrograms per ml ozone gas produced by a medical ozone generator. The ozonised blood is now transfused back into the patient [10].

EBOO is Extra Corporeal Blood Oxygen ozonisation. Here ve-nous blood is extracted via peristaltic pump, and goes into an EBOO flask. Here the blood is continuously ozonised, and re administered to the patient via a recipient vein. In one EBOO session 3 to 4 litres of blood are ozonised [11,12].

Hydrozone is a mixture 99.999% purity molecular hydrogen gas with 100 micrograms percent Ozone gas and the same is adminis-tered intra-articularly into the hip joint. The hip joint is approached anteriorly and the presence of the needle is visualised under C arm after injecting a radio opaque die. 10 cc hydrogen and 40 cc ozone are now injected through the same needle and the widening of the joint space under C arm can be appreciated [13].

Mukharjee regimen is an essential low dose DMARD regimen, with alternate days 2.5 mg methotrexate, 5 mg alternate days folic acid, 2 mg methylpredisalone daily, with 200 mg of HCQS three days a week [14].

The videos of the procedures in full can be seen by clicking the links Above. All procedures are shown with explanations.

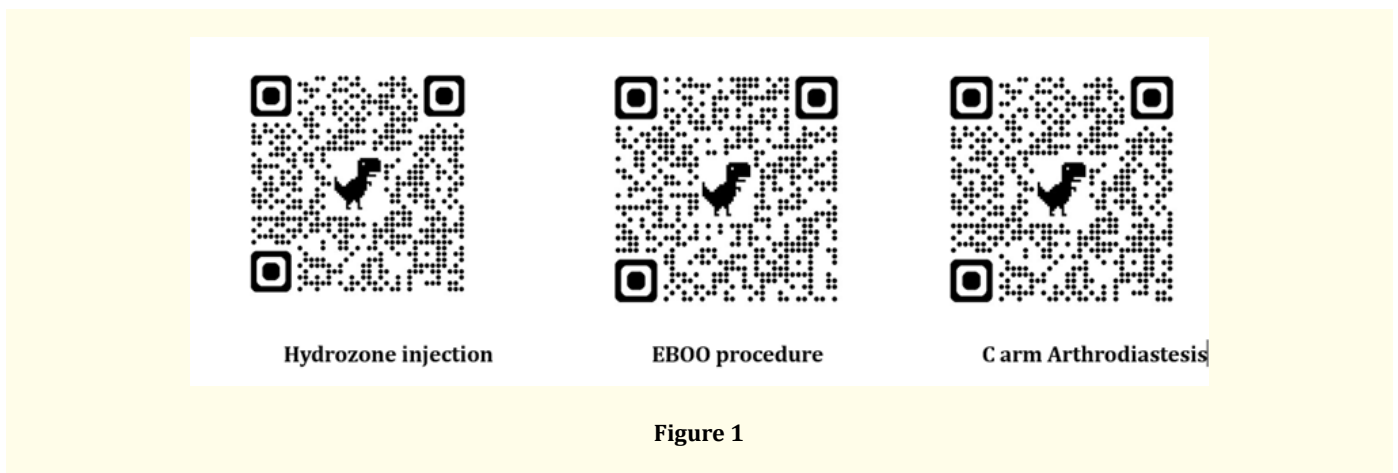


Figure 1

Material and Methods

Avascular necrosis was diagnosed by clinical history, MRI scans and X ray images in 36 patients. The youngest patient was 21 years old and the oldest was 41 years old in our series. All patients first consulted a family physician or a local doctor, who did an X ray or MRI, and reached the diagnosis. The surprising fact was that 27 patients were advised an MRI first even before a plain X-Ray. Only 4 of these 36 patients were direct referrals to the author, while the rest sought multiple consultations with various orthopaedic surgeons and were advised some form of surgery like core decompression, fibular grafting or hip replacement. These patients finally consulted the first author as they wanted to avoid surgery at any cost.

Each patient was counselled and a full explanation of the procedure was given. Videos of patients undergoing the procedure were shown and a written and video consent was taken. The procedure was performed in a special treatment area inside the operating theatre complex. The first six cases were performed under C arm and the arthrodiastesis was visualised. Subsequently with experience the authors began to perform the procedures without C arm.

All the patients experienced an immediate relief in pain and had significant improvement in the range of movements after in-

traarticular hydrozone injections. The intraarticular injection was immediately followed by MAHT or EBOO. The choice between the two procedures depends on the available veins. If good large vein for a 16 g IV cannula is available for the donor site, then an EBOO was performed, and in case the veins are thinner or two sites cannot be obtained, a MAHT was performed.

Subsequently all patients underwent a low dose DMARD therapy for 18 months, and were recalled every three months for MAHT/EBOO. Depending on symptoms, intraarticular Hydrozone was repeated either 3 monthly or 6 monthly. Haematological investigations were monitored to ensure the safety of administered drugs. X rays were taken on start of treatment, at 6 months and 18 months.

All patients were allowed to bear full weight, and were not administered any pain killers or other medications except those detailed above.

Results

This study was a prospective non randomised consecutive analysis of 36 patients, 19 males and 17 females between the ages of 21 and 47. The study was conducted by a single author in a private hospital on outpatient basis. Seven of the thirty-six patients.

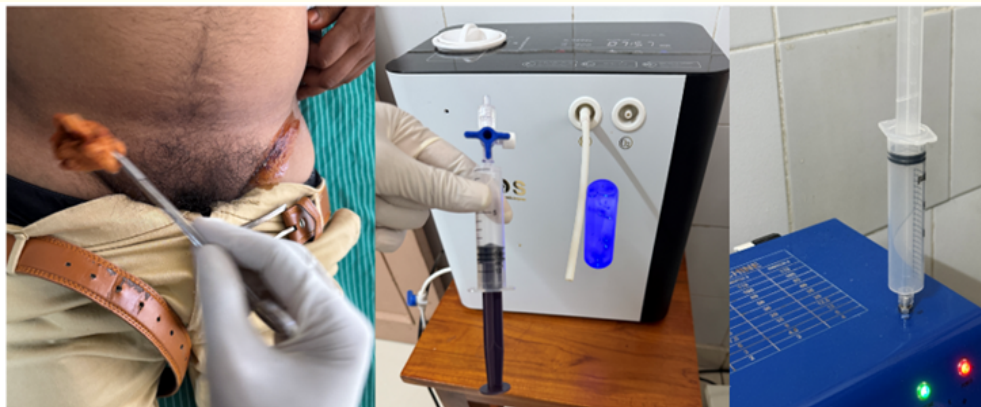

Figure 2: The injection area is cleaned, and Hydrogen/Ozone are drawn in separate syringes. Ozone needs special ozone compatible syringes.

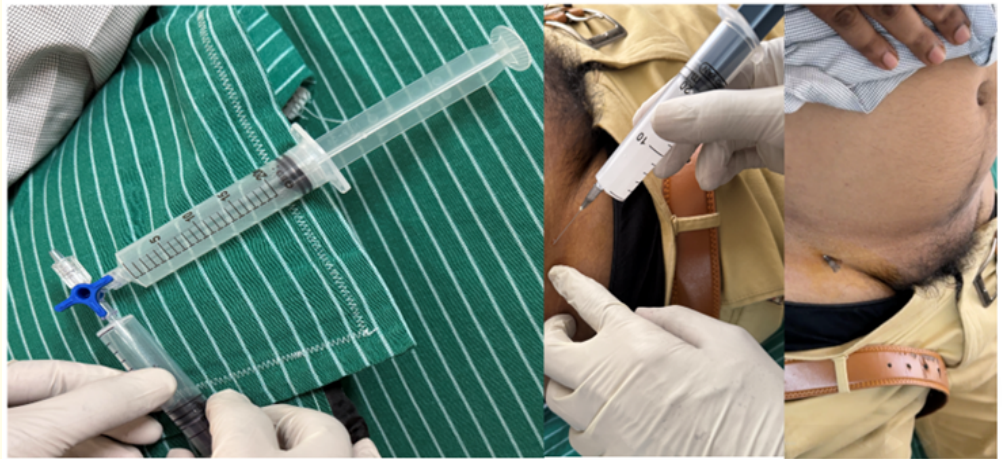


Figure 3: Ozone and hydrogen syringes are connected with a three way. Local aesthetic cocktail is injected into the hip joint and the syringe is removed, leaving the needle in the joint.

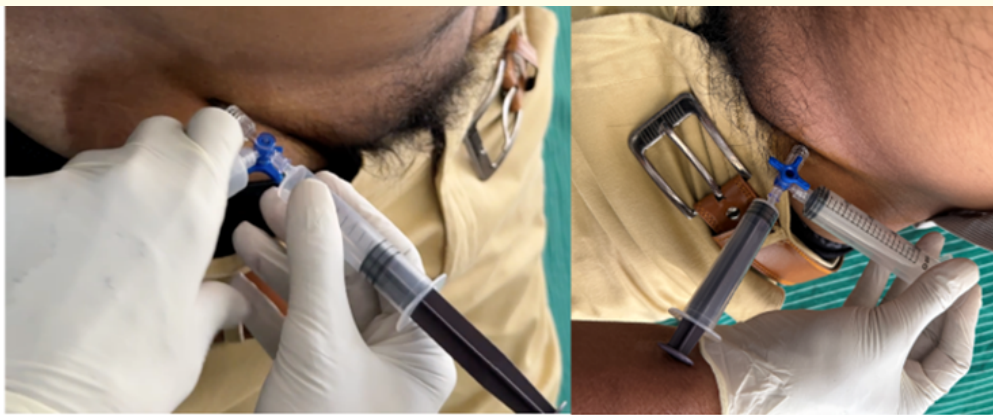

Figure 4: First hydrogen, and then ozone are injected to distend the joint and distract the surfaces.

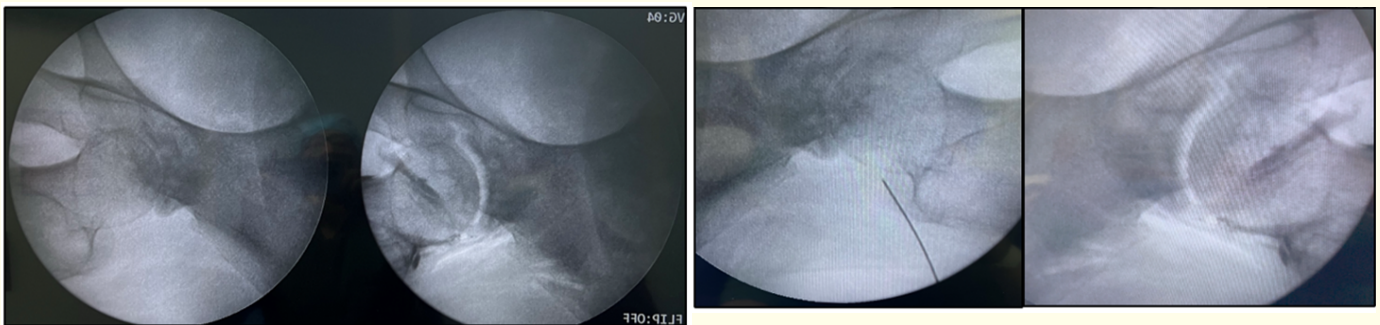


Figure 5: Hydrozone arthrodiastesis as visualised under C arm were doctors and two of them orthopaedic surgeons. The patients were either referred.

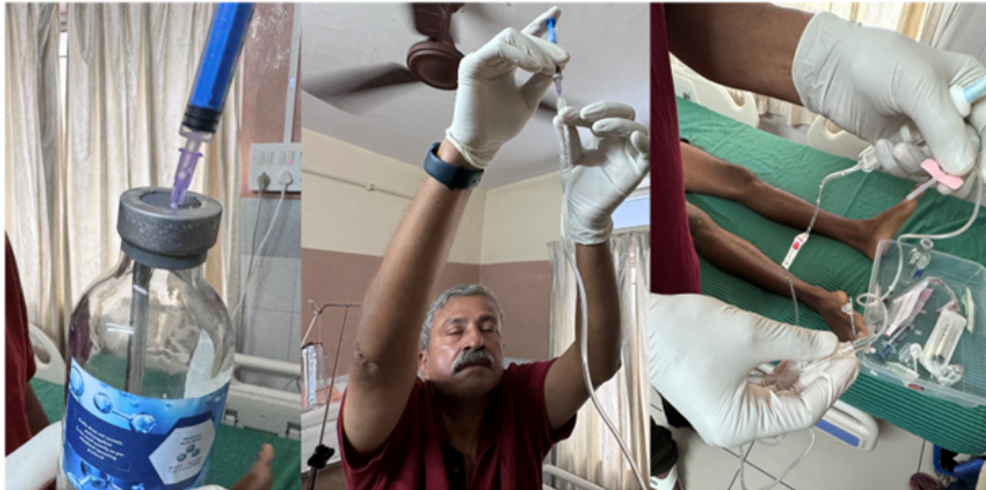

Figure 6: Vacutainer bottle, infusion set and the butterfly cannula are primed with 1000 IU per ml heparin.

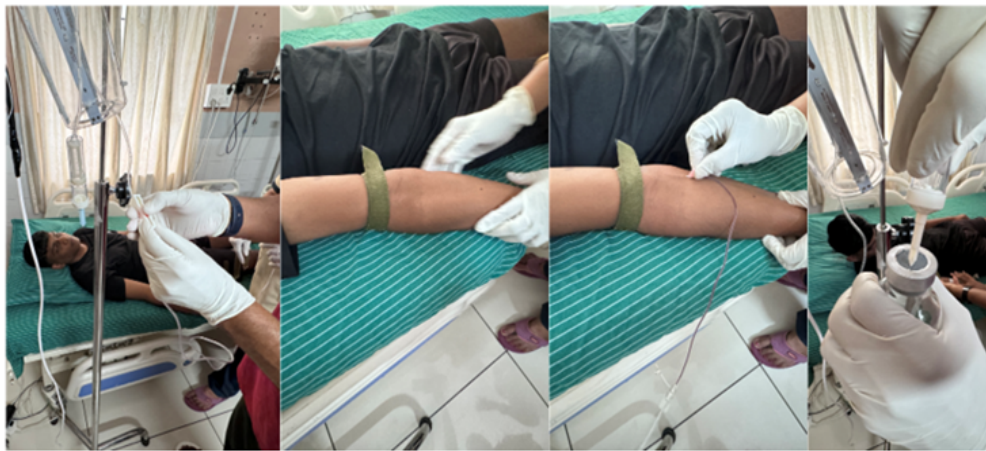

Figure 7: The set is closed, tourniquet applied, vein identified, punctured and the bulb end pushed into the silicone cap of the bottle.

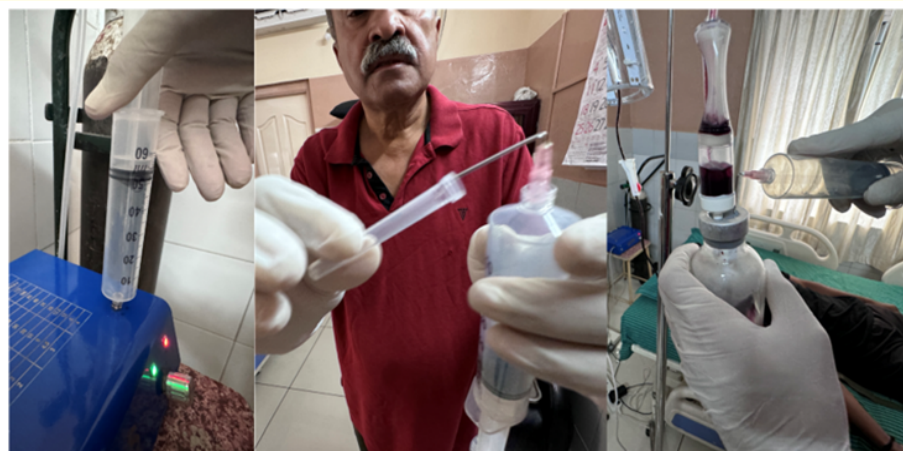


Figure 8: 50 ml of 100 micrograms per ml ozone is drawn, a 16 g needle is bent to 90 degrees, attached to the syringe, and the blood is ozonised.

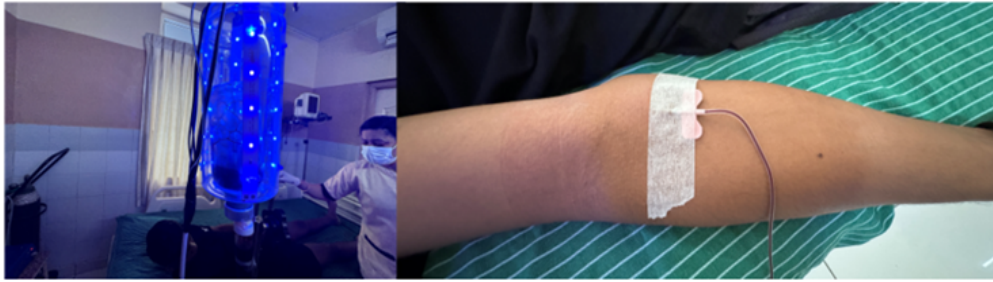

Figure 9: The bottle is inverted and the blood is re transfused into the patient. By their index surgeon, or had consulted the author online.

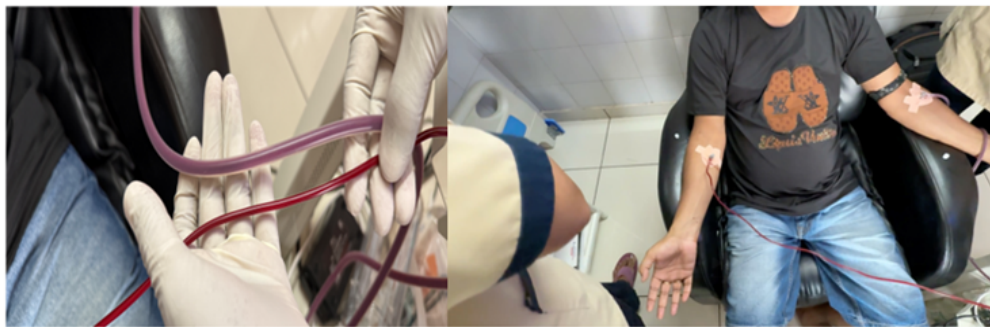

Figure 10: EBOO is an advanced version of MAHT, where donor blood drawn from one vein is continuously ozonised and re infused through a recipient vein.

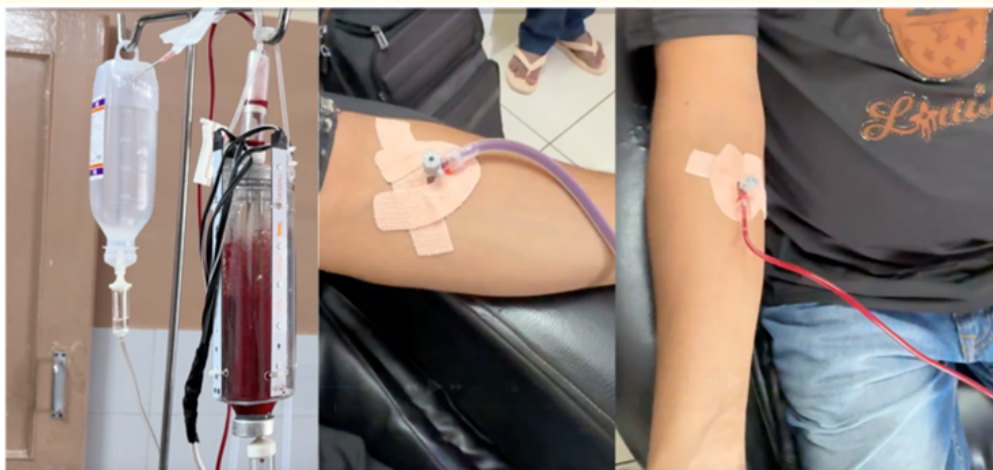

Figure 11: The EBOO system and the comparative difference between the inflow and output blood showing the dramatic change in colour.

Mukharjee Low Dose DMARD regimen

- Tablet Methotrexate 2.5 mg Monday/Wednesday/Friday
- Tablet Folic Acid 5 mg Tuesday/Thursday/Saturday
- Tablet HCQS 200 mg Tuesday/Saturday
- Tablet Methylprednisalone 2 mg daily
- Vitamin D 60,000 units Every Sunday

Two patients left the treatment midway through and one patient died due to unrelated reasons. (Accident). The remaining patients is 33 of 36 were examined at 3, 6, 9, 12, 15 and 18 months, and the following parameters were assessed.

- VAS scores
- Harris Hip Score
- Oxford score

Of these 33 patients 29 patients had excellent and 4 patients had good results, with VAS scores coming down from 8-10 to 1-3. The Harris hip score pre therapy was in the range of 60 to 70 improved to 94 to 98. Oxford scores between 15 to 25, became 40 plus after treatment. None of the patients who completed complete 18 months therapy needed any surgical management nor any pain killers during therapy.

Oxford and Harris Hip scores, pre and post treatment by the regimen.

Examples

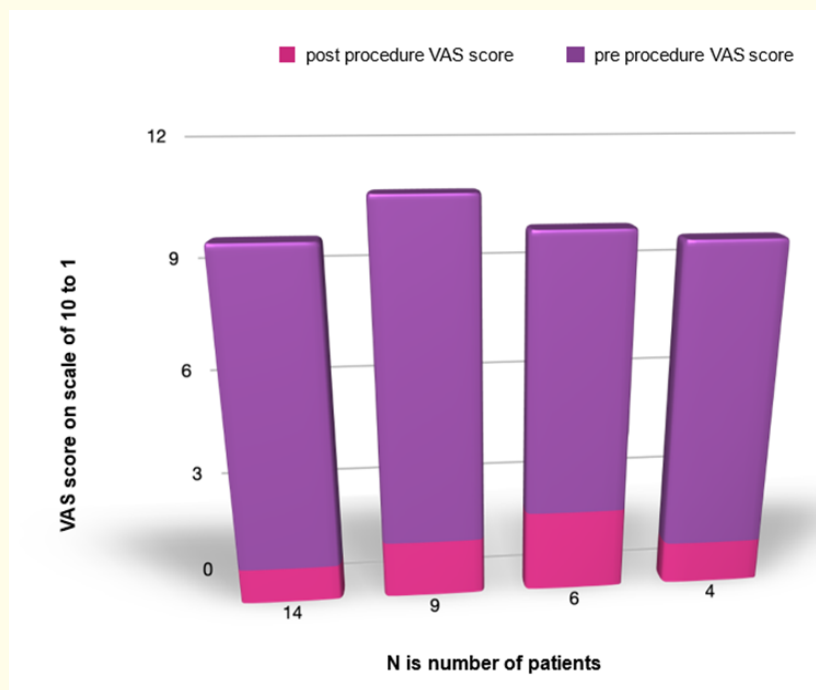


Figure 12

Patient cohort	Pre treatment Harris score average	Post treatment Harris score average	Pre treatment Oxford score average	Post treatment Oxford score average
N = 11	72	98	22	47
N = 9	68	96	21	46
N = 9	62	94	19	44
N = 4	58	89	17	41

Table 1

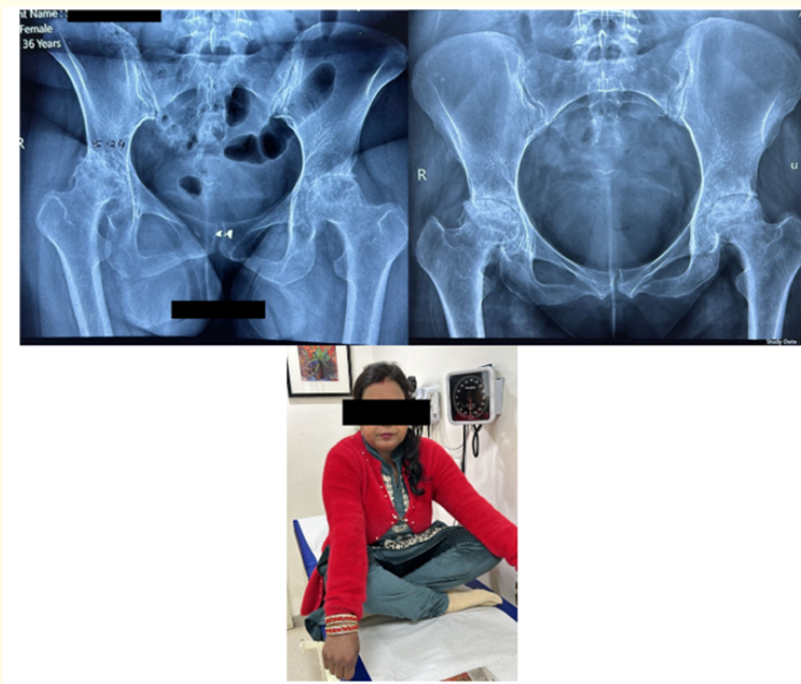


Figure 13: Reappearance of joint space and full function in 18 months.

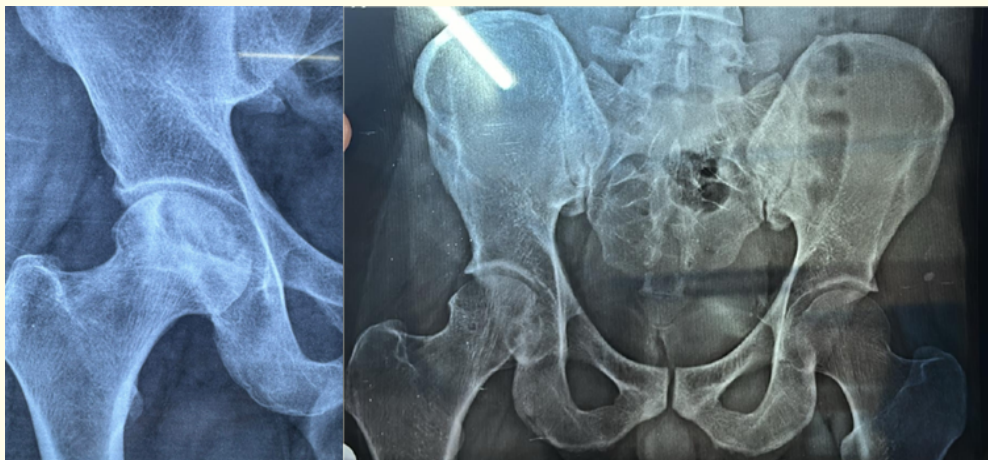


Figure 14: Ficat grade 3 AVN with complete radiological and clinical recovery in 18 months.

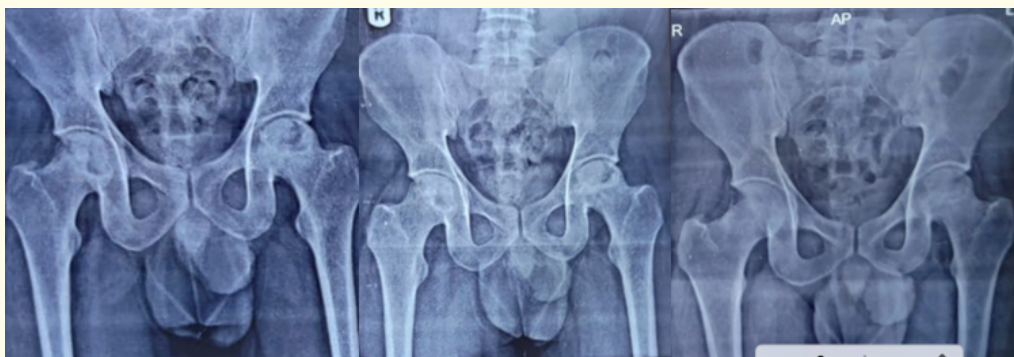

Figure 15: Sequence of recovery in 18 months.

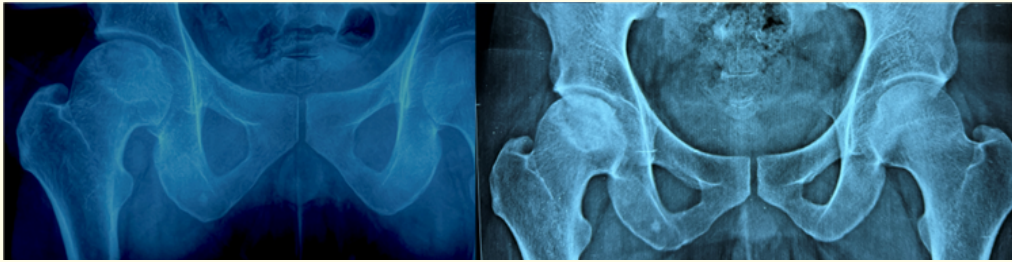


Figure 16: Cysts and holes in head, filling up and consolidating with the therapy, and the radiograph on the right is at 15 months. Patient is asymptomatic.

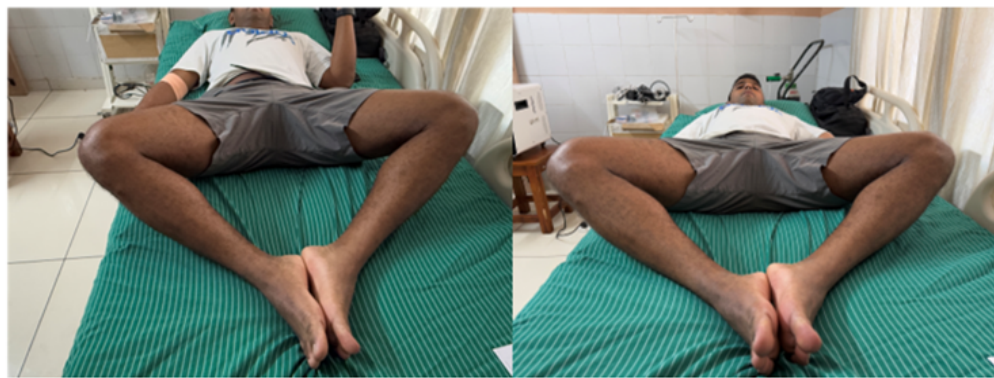

Figure 17: Terminal range of abduction deficit immediately correcting after hydrozone arthrodiastesis.

Discussions

This study presents the results of a combination therapy which stands on a triad of three legs, each of which is well documented in literature [15-17], but a combination of the three has not been deployed together so far. The three pillars which are responsible for the successful outcome of the therapy are gaseous arthrodiastesis, intravenous haematogenous ozone and low dose disease modifying anti rheumatoid drugs (DMARD).

Gaseous arthrodiastesis is a procedure when a gas is introduced into a joint with diminished joint space and the injection with pressure, separates the intraarticular area, producing rapid relief of pain, and measurable improvement in the range of motion [18]. Ozone arthrodiastesis is well documented in literature and the oxidising properties of the gas are known to suppress the proliferative synovial intrusions and oxidise the wear debris in an arthritic joint due to avascular necrosis [18]. This twin action is responsible both for pain relief and increase in range of movements.

The author has for the first time added molecular hydrogen gas to increase the volume of distention, and also take advantage of the antioxidant properties of the inert gas [19].

Haematogenous ozone administration either by MAHT or EBOO have wide range of indications, and ischaemia is one of them [20]. In acute myocardial ischemia, or in non haemorrhagic strokes, EBOO or MAHT have shown rapid reversal of the situation [20]. Unlike cardiac or neuronal tissues, bone never dies, and thus even stage four AVN eventually completely re-vascularise and form dense bone. However, without protection from loading, the unfortunate consequence of collapse and deformation of the head happens [21]. An incongruent ball and socket joint will certainly lead to rapid wear and tear in a small high load bearing joint like hip, and result in severe painful crippling arthritis [22]. Low dose DMARD: It is presently well accepted that avascular necrosis of hip joint has an auto immune content [23-25], and that is the reason not all people contacting Covid infection, or vaccination have exhibited this prob-

lem. It is postulated that anatomical variations in the blood supply of femoral head [26], along with autoimmune modulated vascular intimal damage, causes plaques to disrupt the terminal blood supply to the head of the femur, leading to sectors getting deficient oxygenation.

Methotrexate works by acting on the folic acid metabolism, and slows down the mitosis cell replication in rapidly multiplying cells, which is usually present in these cases [27]. To prevent the toxic effect of methotrexate on normal cell multiplication, alternate day folic acid is administered. In addition the other DMARDS used are in very low doses, and also individually tailored according to the patient. This combination allows the medications to be used for 18 months, without side effects, and this is the average time taken for the joint to re-vascularise and the head become dense again.

The combination of the three therapies as described earlier has not only saved a large number of hips from surgery in the authors clinical practice, but is also being widely practiced in a sizeable number of centres and soon studies will be published. The list of publications on both ozone and hydrogen in therapeutic applications is also downloadable [28,29].

Conclusion

Covid pandemic has been followed by an epidemic of hip AVN [30], mostly in very young patients who are often bread winners or key elements in their families. Conflicting opinions offered by different therapists, and also the prognosis for long term wherein total hip arthroplasty is mentioned as the final and ultimate outcome in future demoralises the patients. Most patients seek a non surgical alternative and want to delay surgery until it becomes inevitable.

The above triad of therapy has proved be produce excellent outcomes in the authors centres, and 33 of the 36 patients (nearly 89%) had excellent results, and all patients have avoided surgical intervention in any form. As the final radiographs have shown near normal radiological appearance of the hips with intact joint space, mechanically and physiologically, the predictive indicators do not anticipate the need for any surgical intervention especially THR in the next 3 decades or more.

Two centre study with a small number of patients, and the need of specialised equipment like hydrogen and ozone generators are the limitations of the study. In addition, the techniques need training and hands on experience before implementing on the patients. Despite the limitations, the authors are of the firm opinion, that this triad of therapies produces much superior result as compared with core decompression, or bisphosphonates, both of which have close to 30% failures leading to eventual total hip replacement.

Declaration of Conflicts of Interests

The first author is the director of a company IAOS technology Private limited, which manufactures ozone and hydrogen generators and equipments. The other three authors do not have any commercial interests.

Funding

No funding has been received from any source for this publication.

Author Contributions

The first author has written the text, and no help from AI was used in either writing or correcting the text.

The cases in this series are from the first authors institution, and the fourth author has provided videos and C arm images of arthrodiastesis.

The second author, a pioneer ozone therapy in India and was the first to introduce ozone hip arthrodiastesis two decades ago, and the third author, the inventor of Mukharjee regimen, have made substantial additions and corrections to the text.

Bibliography

1. Bergman J., *et al.* "Epidemiology of osteonecrosis among older adults in Sweden". *Osteoporosis International* 30.5 (2019): 965-973.
2. Louise Howse Stephen Bendall. "Avascular necrosis of the femoral head: management remains controversial". *Orthopaedics and Trauma* 37.4 (2023).
3. Mankin H J. "Nontraumatic necrosis of bone (osteonecrosis)". *New England Journal of Medicine* 326.22 (1992): 1473-1479.

4. Assad SK, et al. "Avascular necrosis of femoral head following COVID-19 infection". *Annals of Medical Surgery (Lond)*. 85.9 (2023): 4206-4210.
5. Hassan AAA and Khalifa AA. "Femoral head avascular necrosis in COVID-19 survivors: a systematic review". *Rheumatology International* 43 (2023): 1583-1595.
6. *Chemical Review* 107.10 (2007): 3900-3903.
7. Paul Solomon, et al. "Comparison of scientific findings from major ozone field studies in North America and Europe". *Atmospheric Environment* 34.12-14 (2000): 1885-1920.
8. Parikh S, et al. "Avascular Necrosis as a Sequela of COVID-19: A Case Series". *Cureus* 15.2 (2023): e35368.
9. Joel M Kremer. "Toward a Better Understanding of Methotrexate". *Arthritis and Rheumatism* 50.5 (2004): 370-1382.
10. Viebahn-Hänsler R, et al. "Ozone in medicine: clinical evaluation and evidence classification of the systemic ozone applications, major autohemotherapy and rectal insufflation, according to the requirements for evidence-based medicine". *Ozone: Science and Engineering* 38.5 (2016): 322-345.
11. Bocci V and Paolo ND. "Oxygenation-ozonization of blood during extracorporeal circulation (EBOO). Part III: a new medical approach". *Ozone: Science and Engineering* 26.2 (2004): 195-205.
12. Di Paolo N, et al. "Extracorporeal blood oxygenation and ozonation (EBOO) in man". Preliminary report.
13. https://youtu.be/p5Urt_oH0Os
14. <https://drive.google.com/file/d/1I6k248oyscPS6Jwc4P8wrivnzMh7SEP/view?usp=sharing>
15. Tsai HL, et al. "Epidemiology and risk factors associated with avascular necrosis in patients with autoimmune diseases: a nationwide study". *The Korean Journal of Internal Medicine* 37.4 (2022): 864.
16. Eriksson E, et al. "Diagnostic and operative arthroscopy of the hip". *Orthopedics* 9.2 (1986): 169-176.
17. Vezzani G, et al. "Beneficial effect of hyperbaric oxygenation in avascular necrosis of the femoral head". *Gazz. Medica Ital Arch Per Le Sci Mediche* 177 (2018): 72-78.
18. Xin-You Gao MD, et al. "Treatment of Femoral Head Osteonecrosis with ozone therapy: Pilot trial of a new therapeutic Approach". *Pain Physician* 25 (2022): E43-54.
19. <https://www.youtube.com/watch?v=1185RvPgm4A>
20. Di Filippo C, et al. "Acute oxygen-ozone administration to rats protects the heart from ischemia reperfusion infarct". *Inflammation Research* 57 (2008): 445-449.
21. Orban HB, et al. "Avascular necrosis of the femoral head". *Maedica (Buchar)* 4 (2009): 26-34.
22. Cameron HU and Macnab I. "Observations on osteoarthritis of the hip joint". *Clinical Orthopaedics and Related Research (1976-2007)* 108 (1975): 31-40.
23. Tsai HL, et al. "Epidemiology and risk factors associated with avascular necrosis in patients with autoimmune diseases: a nationwide study". *The Korean Journal of Internal Medicine* 37.4 (2022): 864.
24. Al Saleh J, et al. "Predictors of avascular necrosis of the hip in Emiratis patients with systemic lupus erythematosus". *Egyptian Journal of Immunology* 17.1 (2010): 29-40.
25. Rolston VS, et al. "Prevalence and associations of avascular necrosis of the hip in a large wellcharacterized cohort of patients with inflammatory bowel disease". *Journal of Clinical Rheumatology* 25.1 (2019): 45-49.
26. Trueta J and Harrison MH. "The normal vascular anatomy of the femoral head in adult man". *The Journal of Bone and Joint Surgery British Volume* 35.3 (1953): 442-461.
27. Cronstein BN. "The mechanism of action of methotrexate". *Rheumatic Disease Clinics of North America* 23.4 (1997): 739-755.
28. https://drive.google.com/file/d/17vZiqHJcNHe-57AuTQn_PDlyTuqOPYvN/view?usp=sharing
29. <https://drive.google.com/file/d/15vm-6tMPmEFO32PWeuXCWHkrWg1cZbZW/view?usp=sharing>
30. Snowden GT, et al. "Orthopaedic long COVID-the unknown unknowns: are we facing a pandemic of avascular necrosis following COVID-19?". *Bone and Joint Research* 11.1 (2022): 10-11.