



## The Blue Bulge Sign. Arthroscopic Tips to Identify and Decompress an Atypical Hip Paralabral Cyst

Luis Perez-Carro<sup>1\*</sup>, Jegathesan T<sup>2</sup>, Oscar Perez-Fernandez<sup>1</sup>, Mohamed Mahmoud Elghandour<sup>1</sup> and David Gouveia<sup>1</sup>

<sup>1</sup>Orthopedic Surgery Department, Hospital Mompia, Santander, Cantabria, Spain

<sup>2</sup>Department of Orthopaedic Surgery, Tan Tock Seng Hospital, Singapore, Singapore

\*Corresponding Author: Luis Perez Carro, Orthopedic Surgery Department, Hospital Mompia, Santander, Cantabria, Spain.

Received: January 25, 2024

Published: February 05, 2024

© All rights are reserved by Luis Perez-Carro, et al.

### Abstract

We present the case of a 49-year-old woman who developed gradual left hip pain, both mechanically and at rest. She was subsequently evaluated for the presence of a large, atypical, anterior inferomedial paralabral cyst in addition to the conventional features of hip femoroacetabular impingement. Her persistent symptoms were successfully treated via hip arthroscopy. Technical details for identifying and locating this paralabral cyst as well as decompression of its contents are discussed in greater detail in this article, as are intraoperative arthroscopy images.

**Keywords:** Paralabral Cyst; Hip; Arthroscopy; Cyst Decompression

### Introduction

Paralabral cysts are well-documented findings associated with intraarticular hip pathology but the management and treatment of such cysts are still limited in the literature, with the majority of related discussion centered only on radiologic findings by imaging. Cystic lesions around the hip region can be symptomatic due to either compression of nearby structures or irritation of adjacent tissue [1]. Treatment via arthroscopic decompression of parameniscal cysts in both the shoulder and knee has been extensively described and found to be satisfactory. In contrast, treatment for paralabral cysts in the hip is still limited in the literature and restricted by radiographic findings [2]. We report the case of a patient who presented with a large, atypical, anterior inferomedial paralabral cyst in addition to the conventional features of hip femoroacetabular impingement. Her persistent symptoms were successfully treated via hip arthroscopy, and technical details for identifying cysts in this uncommon location and performing paralabral cyst decompression were shared in this article, along with intraoperative arthroscopy images.

### Case Presentation

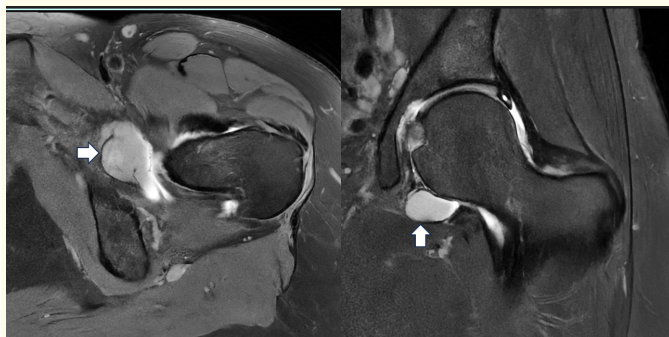A 49-year-old female without a history of developmental dysplasia of the hip or prior hip pathology developed an insidious on-

set of left hip pain over 3 years. The pain was deep seated within her left groin and gluteal area and was present both with mechanical activity and at rest. She had no definite history of trauma or hip injury and did not have any prior hip symptoms during her younger years. An examination of her left hip revealed minimal tenderness in the left groin. There was no pain triggered upon general movement of the hip, but anterior impingement of the hip was positive. She also had an increased range of motion in her left hip, with an internal rotation of 40° and an external rotation of 45° at 90° of hip flexion. Her left hip flexion was 100°. Her Beighton score was normal, and there was no underlying ligamentous laxity. Plain radiographs revealed subtle features of a small femoral CAM lesion and a lateral center edge angle of 27°. There were no other significant abnormalities. MRI revealed an anterosuperior labral tear with chondro-labral separation. A femoral CAM lesion was again observed at the typical anterolateral aspect of the femoral head-neck junction. There was also a separate large intra-articular paralabral cyst measuring 2.0 × 1.5 cm located medially and inferiorly, arising above the zona orbicularis and close to the transverse acetabular ligament (Figure 1). The contents of the cyst exhibited intermediate to low signal intensity on T1-weighted images and high signal intensity on T2-weighted images. After an unsuccessful attempt by the interventional radiologist to aspirate the cyst, surgical inter-

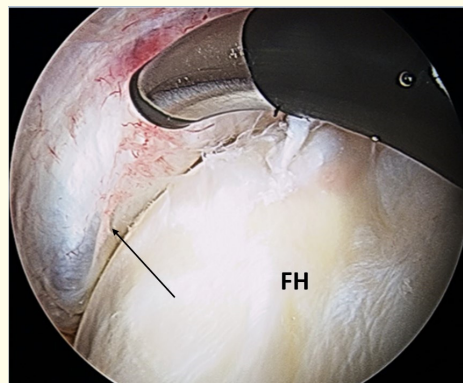
vention was recommended in the form of hip arthroscopy to help alleviate her symptoms. The aim of surgery was to decompress the large medial paralabral cyst and to perform concurrent repair of the torn labrum with femoral osteoplasty. Hip arthroscopy was performed in the supine position with standard anterolateral (AL), modified anteromedial (MAP) and distal anterolateral (DALA) portals. An anterosuperior labral tear was noted, with no tear in the posterior labrum when visualized after performing the interportal capsulotomy. At this juncture, an initial attempt to locate the cyst was made with the left leg under traction, but the cyst could not be visualized. Subspine decompression was then performed before labral repair was completed with three suture anchors. The left hip was reduced with traction released before femoral osteoplasty of the CAM lesion was performed under fluoroscopic guidance. Following this, a second attempt was made to locate the paralabral cyst. Utilizing the modified anteromedial portal as the viewing portal, the arthroscope was maneuvered medially across the inferior aspect of the femoral head in search of the paralabral cyst however, there was no difference between the cyst and the joint identified prior to decompression. Only a distinct blue bulge was observed to arise from the labral tissue medial to the femoral head. It was also noted that the surrounding labral capsule tissue exhibited signs of inflammation and irritation (Figure 2). A curved radiofrequency probe was introduced through the DALA portal to dissect the cyst. Upon direct decompression of the cyst, a visible extrusion of copious amounts of yellow gelatinous fluid was observed (Figure 3). The hip capsule was closed prior to the end of surgery. The postoperative recovery was uneventful, and there were no complications. At 8 weeks following surgical resection of the cyst and labral repair, the patient reported complete resolution of her preoperative pain with no hip discomfort. Physical examination revealed good hip range and gluteal strength, and the anterior impingement sign was negative. One year after surgery, the patient was doing well and had no symptoms.

**Discussion**

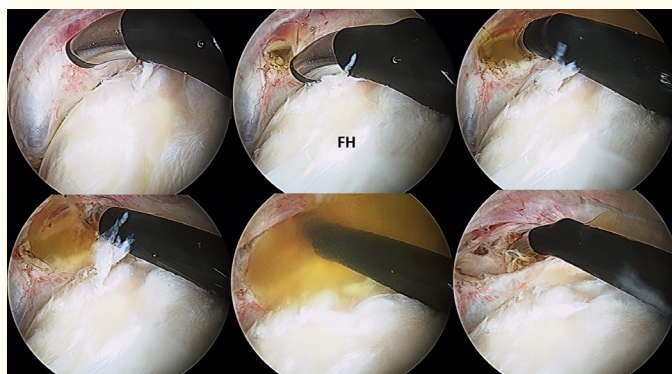
This article describes a 49-year-old female who presented with a large, atypical, anterior inferomedial paralabral cyst in addition to the conventional features of hip femoroacetabular impingement of a torn anterosuperior labral with an associated CAM lesion on the femoral head-neck junction. Utilizing the descriptive features mentioned above during her hip arthroscopy, other symptomatic paralabral cysts of similar location can be reliably located and identified, and appropriate decompression can be performed to drain the cyst. Cystic lesions that occur near the joint may be clas-



**Figure 1:** MR images with axial and coronal cuts showing the anterior, medial and inferior locations of the cyst (solid white arrow). The contents of the cyst exhibited an intermediate high signal density on these T2-weighted images.



**Figure 2:** A distinct blue bulge (Arrow) was observed arising from the labral tissue medial to the femoral head. Note that the surrounding labral capsule tissue exhibited signs of inflammation and irritation. FH (Femoral Head).



**Figure 3:** Decompression of the paralabral cyst under direct arthroscopic visualization. Extrusion of copious amounts of yellow gelatinous fluid was visualized upon decompression. FH (Femoral Head).

sified as either ganglionic or synovial cysts. These 2 entities cannot be distinguished with MRI alone, and they are treated similarly. The term acetabular paralabral cyst is therefore usually used for a cystic lesion that arises adjacent to the acetabular labrum<sup>3</sup>. In a study by Magerkurth, *et al.* [4], more than 80% of paralabral cysts were found to occur in the anterior hip. There was only a single patient (6%) with an anteroinferior paralabral cyst documented in the study population, with anterosuperior paralabral cysts being the most common location (56%). Paralabral cysts are strongly associated with a corresponding labral tear. Differential diagnoses such as atypical synovial or ganglion cysts or atypical synovitis should be considered when there is an absence of a labral tear. Although paralabral cysts are thought to communicate with the joint space via an associated labral tear, how often a paralabral cyst is filled with intra-articular contrast material has not been documented in peer-reviewed literature. In the only other case report of an inferomedial hip cyst described in the literature, a well-defined cyst on the medial synovial fold abutted the zona orbicularis, leading to pectineofoveal impingement and hip symptoms [5]. The cyst in that report was also located anteriorly and inferomedially, but the size of the paralabral cyst in our patient was significantly greater than that previously reported. Through intraoperative arthroscopic images from both patients, the paralabral cyst was identified by the presence of a bluish bulge of labral tissue beyond its normal gentle contour. The attenuated appearance of the bulge indicated that the underlying gelatinous fluid contributed to the mass difference. Surrounding tissue at the base of the bulge also appeared to be more inflamed and irritative, with more capillaries being observed on the surface in both patients. We believe these are useful specific details that may aid in locating paralabral cysts of similar position and composition. There have been cases of paralabral cysts without corresponding labral tears in similar locations reported in the literature. In a separate case report, Scott *et al.* reported the presence of a large posterior paralabral cyst with a separate anterior labral tear [6]. For their patient, the torn labrum was repaired with standard lateral and anterior portals before a separate posterolateral portal was utilized to address the cyst. There was no posterior labrum tear visualized after thorough inspection. Although their relationship with labral tears has been established, paralabral cysts have also been linked to other hip pathologies, including psoas impingement, subtle acetabular or femoral head dysplasia and autoimmune conditions [7-9]. These reports consolidate the concept of paralabral cysts heralding an overall pathologic process within the hip joint, not necessarily located at one location.

## Conclusion

Medial anteroinferior paralabral cysts are rare and may prove a technical challenge to locate and decompress. We report the case of a patient who presented with a large paralabral cyst at this atypical location. Her persistent symptoms were successfully treated via drainage of the cyst under direct arthroscopic visualization, with technical specificities shared in this article on how to identify and decompress the paralabral cyst with excellent clinical outcomes. We recommend the use of the blue bulge sign as a useful clue to help clinicians perform this surgery.

## Patient Consent Disclosure Statement

The author(s) attests that consent has been obtained from any patient(s) appearing in this publication.

## Conflict of Interest Statement

None declared.

## Bibliography

1. Perez-Fernandez O., *et al.* "Teres Ligament Ganglion in the Hip Joint. Case Report". *Acta Scientific Orthopedics* 5.12 (2022): 59-61.
2. Lee KH., *et al.* "Arthroscopic Treatment of Symptomatic Paralabral Cysts in the Hip". *Orthopedics* 36.3 (2013): e373-376.
3. Schnarkowski P., *et al.* "Magnetic Resonance Imaging of Labral Cysts of the Hip". *Skeletal Radiology* 25.8 (1996): 733-737.
4. Magerkurth O., *et al.* "Paralabral Cysts in the Hip Joint: Findings at MR Arthrography". *Skeletal Radiology* 41.10 (2012): 1279-1285.
5. Nakano N and Khanduja V. "Medial Synovial Fold Cyst in the Hip Leading to Pectineofoveal Impingement". *Journal of Hip Preservation Surgery* 4.1 (2017): 93-96.
6. Scott E., *et al.* "A Posterior Labral Cyst Associated with an Anterior Labral Tear of the Hip". *Skeletal Radiology* 47.6 (2018): 849-852.
7. Magee T and Hinson G. "Association of Paralabral Cysts with Acetabular Disorders". *American Journal of Roentgenology* 174.5 (2000): 1381-1384.
8. Yukata K., *et al.* "Cystic Lesion around the Hip Joint". *World Journal of Orthopedics* 6.9 (2015): 688-704.

9. Tey M., *et al.* "Hip labral cyst caused by psoas impingement". *Arthroscopy* 28.8 (2012): 1184-1186.