



## Analysis of Using Bioabsorbable Implants in Orthopedic and Trauma Surgery in a Chilean Children's Hospital

Vergara M<sup>1</sup>, Freire M<sup>2\*</sup>, Riquelme J<sup>3</sup> and Vásquez H<sup>4</sup>

<sup>1</sup>Head of the Trauma and Orthopedics Pediatric Surgery Department, Hospital Exequiel Gonzales Cortés. University Santiago de Chile, Chile

<sup>2</sup>Resident of Trauma and Orthopedics Pediatric Surgery, Hospital Exequiel Gonzales Cortés. University Santiago de Chile, Chile

<sup>3</sup>Head of the Research Area of the Trauma and Orthopedics Pediatric Surgery Department, Hospital Exequiel Gonzales Cortés. University Santiago de Chile, Chile

<sup>4</sup>Head of the Arthroscopy and Knee Surgery Area of the Trauma and Orthopedics Pediatric Surgery Department, Hospital Exequiel Gonzales Cortés. University Santiago de Chile, Chile

\*Corresponding Author: Freire M, Resident of Trauma and Orthopedics Pediatric Surgery, Hospital Exequiel Gonzales Cortés. University Santiago de Chile, Chile.

DOI: 10.31080/ASOR.2024.06.0872

Received: October 30, 2023

Published: November 24, 2023

© All rights are reserved by Freire M., et al.

### Abstract

The use of osteosynthesis in children, for traumatic and orthopedic pathologies, presents a progressive increase, determined by the materials accessibility for the different treatments needed for the children [1].

Fractures in children usually require orthopedic treatment, but in the last decade the use of osteosynthesis became more common, as in those fractures with joint involvement or unstable fractures that the orthopedic treatment fail, in those the osteosynthesis allows us to maintain the congruence and stability of the fragments. This is how currently mainly the orthopedic surgeon chose using several materials as screws or Kirschner pins (if it is necessary to go through the physis). However, this kind of material usually requires a second intervention with general anesthesia for their removal, a situation that can be avoided with the use of resorbable implants.

**Keywords:** Bioabsorbable; Implants; Osteosynthesis

### Introduction

Historically, osteosynthesis elements have long durability for being of titanium. Permanent or non-resorbable implants remain in the body after healing and bone reshaping. However, in most cases the implant serves a temporary function, and it is not necessary to keep it within the bone structure after healing. Resorbable implants are made of molecules that exist in the human body and are reabsorbed after the tissue has healed.

Osteosynthesis materials based on resorbable polymers have begun to be used gradually, considering the speed of bone healing in children which allows mechanical demands not to be prolonged as in adult patients [1,2].

Other advantages are to avoid their extraction after getting their objective, and it in the future being eliminated from the or-

ganism promoting the restoration of the original tissues, reducing the risk of subsequent migration and long-term complications related to the presence of external materials, etc. [3,4].

The present work aims to show the experience of orthopedic surgeons using the resorbable implants in children, in the treatment of fractures or in orthopedic pathologies. Before using those materials, it was considered that in children surgeons already have used biodegradable resorbable sutures to fix small chondral fragments in fractures without presenting adverse reactions, those materials were polyglycolic and polylactic acid. After an extensive review in the literature of the use of resorbable implants in animals, adult and pediatric patients; we analyzed the work of Mäkelä., et al., who studied the effects of transphyseal perforation of the distal femur in rabbits using polydioxanone and polyglactin pins, observing the regeneration of the physis in the area of perforation and later these

same authors described the use of resorbable pins in supracondylar fractures of humerus in children aged 7.7 to 9 years [5-7].

However, Gil Albarova, *et al.* observed in rabbits that self-tapping screws of polyglycolic acid are unable to achieve an epiphysiodesis of the greater trochanter, behaving as an interposition material that prevents the formation of a physiary bridge [8].

Another study that caught our attention is the one of P. Hope, *et al.*, who in 24 children compared the outcome of using regular pins and biodegradable pins in elbow fractures, 14 fractures of the lateral condyle, 8 of the medial and 2 of olecranon. Eleven fractures were fixed with regular pins and thirteen with polyglycolic acid pin. Surprisingly, no complications were described with biodegradable materials [9].

At the university Orthopedic and Children's Surgery Center in Zurich, Switzerland, some surgeons share their experience with resorbable implants that we found amazing and will describe at the following.

Dr. Teddy and F. Slongo have shown that the use of bioabsorbable implants in children is an emerging field based on the experience of each author and creates the necessity to research more about the topic and their development because of their healing potential and the benign biological reactions with the children's bones. At the same time, O. Illi, *et al.*, from the same orthopedic center, in five years of experience using biodegradable implants in orthopedic surgery concludes that the bioabsorbable material meet all expectations and he plans to increase the use of this material in pediatric trauma surgery [10].

However, implant resorption has rarely been associated with adverse clinical effects from foreign body reaction such as skin flushing on the implantation site, pain, edema, drainage of implant fragments through skin holes. These reactions are related to the local accumulation of degradation products of the implant and the ability of the surrounding tissues to eliminate such waste. In children the size of the implants is smaller than those required in the adult patients so they have a less chance to have an adverse reaction to external material, and by the other side; the children's bones have a large amount of cartilage and physis, which are often compromised by trauma or in the correction of an orthopedic pathology that sometimes makes it necessary to cross the physis with elements of osteosynthesis that in some cases the extraction can be difficult as trying not to damage the physis [11].

Once again demonstrating the advantages of bioabsorbable implants, Otsuka, *et al.* studied the effects of the degradation of

polydioxanone implants which were installed through the physis, however they verified that this degradation did not alter the normal physis growth [11].

In another study, Nordström, *et al.* have investigated the tissue and sponge bone in the distal third of rat's femurs with the self-tapping implants of polyglycolic acid and polylactic acid. They verified the presence of a bone stimulation response between the implant and the recipient tissue of different presentation in both implants. With polylactic acid implants, the bone response was maximal in the first postoperative week, decreasing progressively after that time. However, with polyglycolic acid implants, the response was significantly higher than that observed with the polylactic acid implants at 6, 12 and 24 weeks postoperatively, coinciding with the greater local accumulation of macrophages [12].

As a conclusion Polyglycolic acid implants have a high rate of adverse tissue response, this risk decreases with lactic acid polymers, however, its long degradation in years can be a disadvantage in several situations behaving as a metal implant [13].

As we can see in the literature, the ideal bone substitute should be osteogenic (bone producer), biocompatible (local biological tolerance), bioresorbable (degrade into components of lower molecular weight normally included in human body), capable of providing structural support, capable of transporting other substances, easily usable in clinic and with an adequate cost-benefit ratio.

### Objectives

- Assess the competence of bioresorbable implants.
- Determining the efficiency and efficacy of bioresorbable material in fracture and orthopedic surgeries for children.
- Analyze the cost benefit of surgery with bioabsorbable implants versus regular nonabsorbable osteosynthesis.
- Determining the biocompatibility of bioabsorbable implants in pediatric patients.

### Material and Methods

- **Population:** During the period April 2005 to July 2010, fractures and orthopedic surgeries that required osteosynthesis and did not involve high mechanical demand during the time of bone consolidation were included (Table 1).
- **Excessive mechanical demand:** consolidation time greater than the resistance presented by the bioresorbable material.

### Inclusion criteria

- Children under 15 years of age with fractures and orthopedic surgeries requiring internal osteosynthesis with screw and/or needles, without high mechanical demand.

Cases					
	PIN	Screw	Anchor	Screw and pin	Total
Fractures	15	5		2	22
Orthopedic Surgeries	6	3	2	1	12
total	21	8	2	3	34

Table 1

**Exclusion criteria**

- Children with exposed fracture with high mechanical demand.
- Children with comminute fracture.
- Fractures with orthopedic treatment option without fixation needed.

**Material pre analysis**

Bioresorbable polymer implants are made of the same molecular building blocks of lactic acid which is naturally produced in the human body by different systems, such as the muscular system during intense activity. Long polymeric molecular chains are created by combining lactic acid derivatives called lactids. The resulting polymers are usually called polylactides or PLLA. The implants used are formed of a copolymer in proportion of 82% (PLLA) and 18% (PGA), comparable with the strength of a titanium plate but which is reabsorbed within 9 to 15 months. However, its resistance is maintained for 8 weeks.

The copolymer maintains its strength during the healing process, and by hydrolysis slowly breaks down into lactic acid molecules. The resorption process occurs in two phases, the first H<sub>2</sub>O (water) penetrates the implant, reacts with the polymer, and breaks the polymer chains by hydrolysis; and the second hydrolysis converts long chains into shorter chains until the polymer fragments into simple molecules of lactic acid. The lactic acid molecules are then metabolized by the liver into CO<sub>2</sub> and H<sub>2</sub>O, and finally expelled by the lungs. Bioresorbable polymers provide relatively high strength and predictable resorption rates for hard or soft tissue applications. Different resorption rates are beneficial for different surgical applications. For example, the fast bone healing of the pediatric tissue may require an implant with a faster resorption rate than an implant designated for adult tissue that may experience slower or incomplete healing. Resorption rates are controlled by material selection and manufacturing methods.

The advantage of the bioresorbable polymer implant are many which are describe by Jain and using JS, *et al.*; who conducted a

review of bioresorbable implants for musculoskeletal injuries involving bone and ligaments in adults concluding that they may have significant advantages compared to non-resorbable metal implants such as bone fracture healing, maintaining the articular fracture congruence during the healing after the surgery, bone support after orthopedic surgery and avoiding a second surgery for taking out the nonabsorbable implant in case that were used [14].

**Results**

The average age at the time of surgery was 9.5 years for fractures and 9.6 years for orthopedic surgeries.

There were 9 surgical reductions of Milch II humeral condyle fractures, just one presented a deformity due to hypertrophic ossification at the lateral condyle, which we did not attribute to the use of resorbable pin because this event is not uncommon in both surgical treatment with metal osteosynthesis and orthopedic treatments.

Another 3 epitrochlear fractures were treated with bioresorbable pins, two of them passed through an open reduction and pin fixation, and one more with close reduction and percutaneous fixation.

In ankle fractures, there were no complications in a case of Til-laux fracture treated with close reduction and percutaneous fixation, with at least 6 months of follow-up. Another patient with triplane fracture who received an open reduction plus fragments fixation with screw 2.5 and a pin of 1.5, pitifully the patient did not attend to controls (Figure 1).

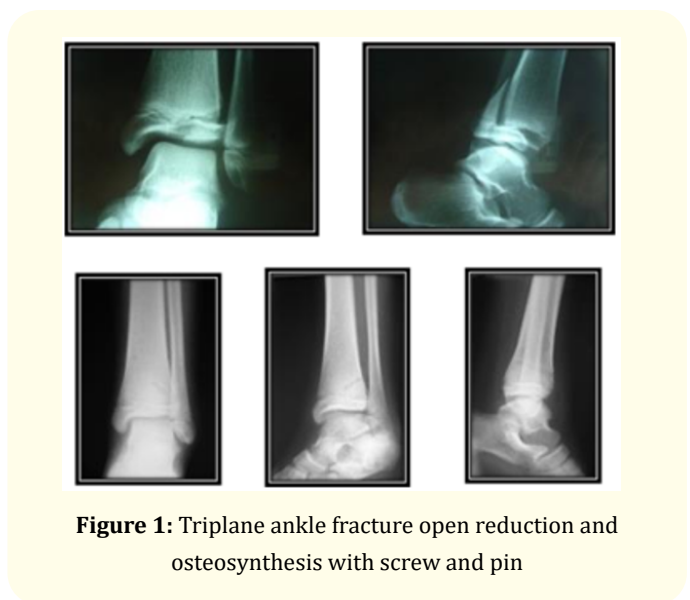
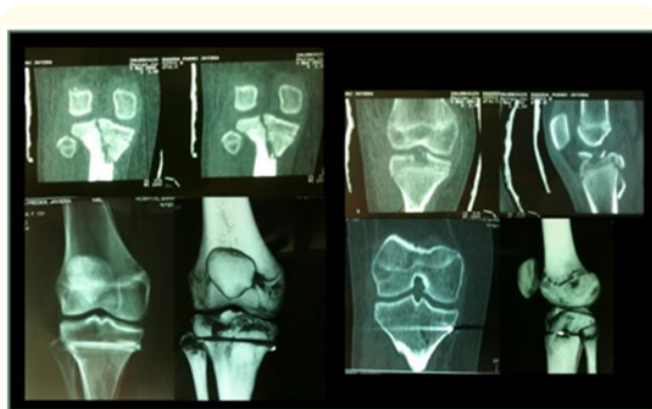


Figure 1: Triplane ankle fracture open reduction and osteosynthesis with screw and pin

All these surgery technics where previouslydone and published as case reports or cohorts ofcases with successfully achievement [15-19].

Fractures of knee, tibial spine and patella, havenot either complication after being treated withreabsorbable material, and surprisingly those with intra articular reabsorbable screws. Besideit was easy to see all the structures at the MRNcontrol, without artefacts [20-22]. (Figure 2).



**Figure 2:** On the left box, Salter IV fracture of proximal tibia treated with regular screws, and in the right box a tibial spine fracture M&M III treated with reabsorbable screws. The proximal tibia fracture shows artefacts at the control imagens while the tibial spine shows no artefacts.

A 15-year-old patient consulted in ER for an angled fracture of the diaphysis of the 5th metacarpal with two previous reduction failed attempts, after that the following action was orthopedic reduction and intra medullary fixation with a reabsorbable pin 1.5 mm was performed. There were no further complications and have had an adequateconsolidation.

However, we describe the case of a 12-year-oldpatient who was admitted to the emergency department with a fracture of olecranon and displaced radial fracture. We perform a reduction and direct fixation of olecranon with2 reabsorbable pins # 2mm and PDS suture with Obenque technique. In the radial fracture,the reduction was performed with TEN with theMetezeau technique. At the 5th week of evolution with a complete consolidation, the patient presented an external body reaction,being necessary to take out the operative scar granulomatous area. However, it evolved well in subsequent controls. It is thought that, afterthe Obenque technique, the resorbable pins had a long time in the subcutaneous space, close tothe skin, condition that can be a risk factor for inflammatory reaction of an external material. The patient presented a small area of physisbridge in the olecranon, but it has not beenrelated with the reabsorbable pin site.

As the Hospital is also a children orthopedic surgery center, we also performed a lot of surgeries like Dega technique in developmental dysplasia of the hip, surgeries for Hallux Valgus and osteotomies for fractures with residual torsion or angulation, all those procedures have some complications and can be treated with different techniques, in this investigation we also look after for complications related with using reabsorbable material that will be discuss in bellow.

A patient who was diagnosed for Hallux valgus, haven been get into an Akin osteotomyin which the reabsorbable pin transfixed from proximal to distal the phalanx bone by about 5 mm out of the skin, required second surgery forremoval of detritus.

A Chevron surgery that was performed in a Hallux Valgus in a child foot with resorbable screws of 2.0 mm diameter, the patient did not present second and were adequately tolerated conventional treatment with metal needles, alsodescribed in other studies [23,24].

Another case to show the good evolution of reabsorbable is a child who has had an unicondylar fracture of the first phalanx index,treated with a percutaneous pin, presented a reaction of an external body in the prominent area but it was not necessary to perform asecond surgery for removal, and the fracture evolved correctly.

A patient with interphalangeal pseudoarthrosis of the thumb secondary to severe trauma with loss of proximal phalanx was treated with a screw 2.0 mm in diameter plus and inguinal flap, evolved adequately without complicationswith an interphalangeal fusion in functionalposition, such as Pietrzak., *et al*, described in his review [25].

Two patients with club foot with relative insufficiency of peroneal muscles, transposition of the anterior tibial muscle was performed to the second wedge bone, where it was fixed with a bioresorbable anchor.

The average evolution time to the last control was 1.9 years for fractures and none describe any complications.

And for the end we like to describe the evolution of 4 patients who had hip dysplasia development, the original Dega osteotomy treatment was combined with the bioresorbableosteosynthesis material.

The procedure was with 2 resorbable pins crossed from proximal to distal iliac fragment through open osteotomy, to give greater



support with tricortical graft wedges, decreasing the possibility of resorption and at the same time suspending the use of pelvic plaster post-surgery, finally the hip surgery got greater stability with excellent outcomes such as the original technic described in the paper of Jan S., *et al.* [26] (Figure 3).

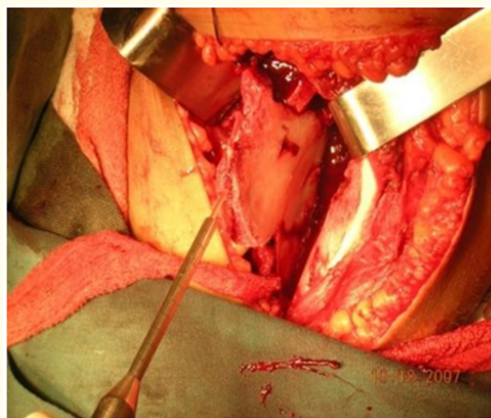


Figure 3: Pin as bicortical graft support in Dega osteotomy.

### Complications

The patients who have participated at the study, none had physis edge, considering the use of implants with a diameter of less than 3mm across the physis.

Only the 10% of patients of our study who documented adverse reaction to the reabsorbable material, we think that it can maybe caused by the size of the implant, its position outside the bone and its proximity to the skin, a similar effect in adult patients in whom the amount of resorbable material to be used is bigger. In the literature we found evidence that implants which are made of polylactic acid polymers in greater proportion have less inflammatory reaction to foreign body [28].

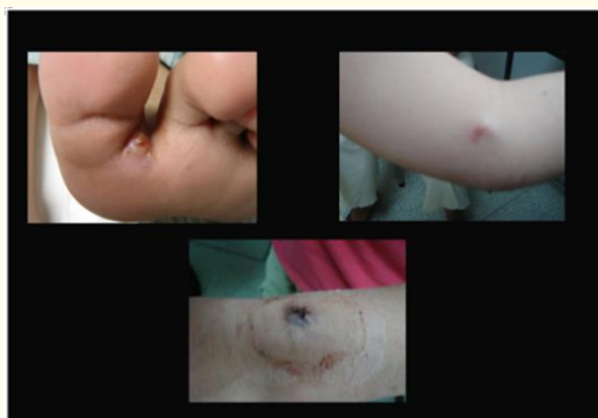


Figure 4: Skin adverse effect of bioabsorbable pinning.

And finally, in addition of analyzing the clinical and radiological outcome of patients operated with bioabsorbable osteosynthesis, the cost and benefit of using this kind of material was analyzed. As being a Chilean public hospital where the study was done, without having access to commercial houses or post-purchase benefits of surgical material, it is guaranteed that the researchers haven't benefits commenting the results of this research. Therefore, a financial analysis was requested from the hospital's finance service, to compare the cost of surgery in one of the patients studied with triplane fracture, and analyze the cost of two choices, one if he would be treated with a regular non-absorbable screw versus the cost of surgery with an absorbable screw.

Initially, the cost of the first intervention was quite similar between the two options, taking into surgery price time, materials, and health personal, the difference highlights only in the osteosynthesis material, the difference between two screws bioabsorbable vs non-absorbable was 200 USD. However, the cost for the removal of non-absorbable screws is 1100 USD, while bioabsorbable screws do not need a second intervention, decreasing the cost for the public service, furthermore, to significantly reducing the patient's risks whether anesthesia effects, as immediate or subsequent clinical post-surgical complications, besides knowing that the patients are children with high psychological susceptibility. Data obtained from the SIGCOM MINSAL system for the month of May 2023 and tenders for clinical supplies carried out by the hospital, through the Public Market.

### Conclusions

The use of bioresorbable implants in trauma or orthopedic treatment in children should be evaluated case by case basis with careful consideration of the benefits and risks involved.

Factors to consider include the patient itself, the nature of the injury, technical considerations, and the experience of the surgeon.

According to the experience obtained, we can describe the following benefits in pediatric patients

- It is useful in every patient avoiding second surgery for osteosynthesis removal after achieving consolidation, in addition to avoiding possible complications of a second intervention, whether physical or psychological damages.
- It is useful in any fracture or orthopedic correction that does not have an excessive mechanical demand.
- Only the cost of surgery for removal the osteosynthesis material in our center cost almost twice than the use of bioresorbable implants in the first intervention, not counting the cost of further medical appointment for stitches, or possible complications.

- Allows imaging examinations such as CT and MRI without artefacts in the images that affect the study or visualization.

We must not forget that the use of bioresorbable implants are not exempt from complications, however, these complications according to our research and experience are apparently related to the improper use or little experience of surgery, but not with the same implant material within the bone structure.

## Bibliography

1. Ashammakhi, *et al.* "Spotlight on Naturally Absorbable Osteofixation Devices". *Journal of Craniofacial Surgery* 14.2 (2003): 247-259.
2. Rovinsky David MD., *et al.* "The Use of Bioabsorbables in the Treatment of Children's Fractures". *Techniques in Orthopaedics* 13.2 (1998): 130-138.
3. Pentti U Rokkanen., *et al.* "Bioabsorbable fixation in orthopaedic surgery and traumatology". *Biomaterials* 21 (2000): 2607-2613.
4. Gil Albarova J., *et al.* "Materiales para la reparación y sustitución ósea. Factores de crecimiento y terapia génica en Cirugía Ortopédica y Traumatología". *Mapfre Medicina* 14 (2003): 51-65.
5. Mäkelä EA., *et al.* "The effect of a penetrating biodegradable implant on the epiphyseal plate: An experimental study on growing rabbits with special regard to polylactin 910". *Journal of Pediatric Orthopaedics* 7 (1987): 415-420.
6. Bostman EA., *et al.* "Transphyseal fracture fixation using biodegradable pins". *The Journal of Bone and Joint Surgery British Volume* 71-B (1989): 706-707.
7. Makela Ea., *et al.* "Biodegradable fixation of distal humeral physeal fractures". *Clinical Orthopaedics* 283 (1992): 237-243.
8. Gil Albarova J., *et al.* "Absorbable screws through the greater trochanter do not disturb physeal growth. Rabbits experiments". *Acta Orthopaedica Scandinavica* 69 (1998): 273-276.
9. PG Hope., *et al.* "Biodegradable pin fixation of elbow fractures in children a randomised trial". *Journal of Bone and Joint Surgery- British Volume* 73-b.6 (2000): 965-968.
10. OE Illi., *et al.* "Five years of experience with biodegradable implants in paediatric surgery". *Journal of Materials Science: Materials in Medicine* 5.6-7 (1994): 417-423.
11. Otsuka N., *et al.* "Biodegradation of polydioxanone in bone tissue: effect on the epiphyseal plate in immature rabbits". *Journal of Pediatric Orthopaedics* 12 (1992): 177-180.
12. Nordström P., *et al.* "Tissue response to polyglycole and polylactide pins in cancellous bone". *Archives of Orthopaedic and Trauma Surgery* 117 (1998): 197-204.
13. Bostaman Ole M., *et al.* "Adverse Tissue Reactions to Bioabsorbable Fixation Devices". *Clinical Orthopaedics and Related Research* 371 (2000): 216-227.
14. Jainandunsing Js., *et al.* "Dispositivos de fijación biorreabsorbibles para las lesiones musculoesqueléticas en adultos (Revisión Cochrane traducida). En: La Biblioteca Cochrane Plus, 2006 Número Oxford: Update Software Ltd (2006).
15. Petrisor Brad A., *et al.* "Management of Displaced Ankle Fractures". *Journal of Orthopaedic Trauma* 20.7 (2006): 515-518.
16. Hovis W David., *et al.* "Treatment of Syndesmotic Disruptions of the Ankle with Bioabsorbable Screw Fixation". *Journal of Bone and Joint Surgery, Incorporated Volume* 84-A.1 (2002): 26-31.
17. Bucholz Robert W., *et al.* "Fixation with Bioabsorbable Screws for the Treatment of Fractures of the Ankle". *Journal of Bone and Joint Surgery, Incorporated Volume* 76-A.3 (1994): 319-324.
18. Lauri Handolin., *et al.* "Effect of ultrasound therapy on bone healing of lateral malleolar fractures of the ankle joint fixed with bioabsorbable screws". *Journal of Orthopaedic Science* (2005) 10:391-395.
19. Jujha-Pekka Kaukonen., *et al.* "Fixation of Syndesmotic Ruptures in 38 Patients with a Malleolar Fracture". *Journal Orthopaedic Trauma* 19 (2005): 392-395.
20. Weckstrom Maria., *et al.* "Comparison of Bioabsorbable Pins and Nails in the Fixation of Adult Osteochondritis Dissecans Fragments of the Knee an Outcome of 30 Knees". *American Journal of Sports Medicine* 35.9 (2007): 1467-1476.
21. Gramenz Paul., *et al.* "Bioabsorbable Polymers Used In Knee Arthroscopy, Part 2: Clinical Results". *Techniques in Knee Surgery* 5.3 (2006): 199-204.
22. Larsen Mitchell W., *et al.* "Fixation of Osteochondritis Dissecans Lesions Using Poly (l-lactic Acid)/Poly (glycolic Acid) Copolymer Bioabsorbable Screws". *American Journal of Sports Medicine*. 33.1 (2005): 68-76.

23. Gill Lowell H., *et al.* "Fixation with Bioabsorbable Pins in Chevron Bunionectomy". *The Journal of Bone and Joint Surgery, Incorporated Volume 79-A.10* (1997): 1510-1518.
24. Singh Samrendu Kumar., *et al.* "Use of A Simple Suture to Stabilize the Chevron Osteotomy: A Prospective Study". *Journal of Foot and Ankle Surgery* 43.5 (2004): 307-311.
25. Pietrzak William S., *et al.* "A Bioabsorbable Fixation Implant for Use in Proximal Interphalangeal Joint (Hammer Toe) Arthrodesis: Biomechanical Testing in a Synthetic Bone Substrate". *Journal of Foot and Ankle Surgery* 45.5 (2006): 288-294.
26. Jan S Grudziak and W Timothy Ward. "Dega Osteotomy for the Treatment of Congenital Dysplasia of the Hip". *The Journal of Bone and Joint Surgery America* 83 (2001): 845-854.
27. Eero Waris., *et al.* "Transphyseal Bioabsorbable Screws Cause Temporary Growth Retardation in Rabbit Femur". *Journal of Pediatric Orthopaedics* 25 (2005): 342-345.
28. Huolman Riikka., *et al.* "New Multifunctional Anti-Osteolytic Releasing Bioabsorbable Implant". *Journal of Craniofacial Surgery* 18.2 (2007): 295-301.