



## Description of WALANT Technique on Forefoot Surgery

Gustavo Lucar-Lopez<sup>1,4</sup>, Guillem Paz Ramírez<sup>1</sup>, Maria Fernanda Gómez Blanco<sup>1</sup>, Manel Ballester-Alomar<sup>1,4\*</sup>, Kerbi Alejandro Guevara-Noriega<sup>3</sup> and MA Villamizar Avendaño<sup>2</sup>

<sup>1</sup>Orthopaedic Surgery Department, Hospital de Mataro, Mataro, Spain

<sup>2</sup>Anaesthesia and Resuscitation, Hospital de la Santa Creu I Sant Pau, Barcelona, Spain

<sup>3</sup>Vascular Surgery and Translational Medicine, Parc Tauli University Hospital, Sabadell, Spain

<sup>4</sup>Foot and ankle and Sports Medicine Unit, Clinica Creu Blanca, Barcelona

**\*Corresponding Author:** Manel Ballester-Alomar, Orthopaedic Surgery Department, Hospital de Mataro, Mataro, Spain and Foot and ankle and Sports Medicine Unit, Clinica Creu Blanca, Barcelona.

**Received:** July 14, 2022

**Published:** August 12, 2022

© All rights are reserved by **Manel Ballester-Alomar, et al.**

### Abstract

Forefoot surgery usually requires tourniquet use and anaesthesia is performed using a popliteal or ankle anaesthetic block. Therefore, surgical departments require an anaesthesiologist to trust them with this procedure. The elective nature of forefoot surgery and the lack of anaesthesiologists resulting from the COVID 19 pandemic, has forced Foot and Ankle specialists to dig into other alternatives, in order to continue their surgical practice and to avoid the growth of the waiting list. The wide-awake local anaesthesia non-tourniquet, which was originally described for upper limb surgery, has recently been adjusted to Foot and Ankle surgery. It does not require sedation, nor regional or general anaesthesia and since the patient is wide-awake, they will be able to fully collaborate during the procedure. The use of lidocaine and adrenaline described on the WALANT technique allows us to obtain a local anaesthesia and vasoconstriction. This method permits the surgeon to move forward into surgery with a completely awake patient and no need of tourniquet giving the advantage of a full motor function assessment intraoperatively. WALANT has been proven to be a safe, effective and affordable technique when it comes to foot and ankle surgery. Having gone through a lack of anaesthesiologists, surgery rooms and hospital resources during SARS-CoV2, WALANT emerged and now represents an acceptable alternative to consider and continue to treat selected cases of foot and ankle surgeries.

**Keywords:** WALANT; Foot and Ankle; Local Anaesthesia; COVID-19; Ambulatory Surgery; Forefoot Surgery

### Introduction

Most forefoot open surgeries require the use of a tourniquet, therefore is usually performed with either popliteal or ankle block, which is commonly associated with patient sedation to avoid discomfort and forces surgeons to rely on anaesthesiologists to perform these procedures [1].

COVID 19 is a disease caused by the emerging agent SARS-CoV-2 which belongs to the known coronavirus family. The World Health Association (WHO) declared Covid-19 epidemic in January 2020 [2]. As a result, medical teams focused their resources and efforts into treating these infections and complications. In this unprecedented context, anaesthesiologists had to change their usual ac-

tivity and subsequently triggered a shortfall of anaesthesiologists inside the operating room. Most forefoot surgeries are elective and considered not priority, therefore finding alternatives to perform surgeries was mandatory to avoid a rising number in the waiting list.

The WALANT (wide-awake local anaesthesia non-tourniquet) technique originally developed by Donald Lalonde and described for hand procedures, was modified to be used on Foot and Ankle surgeries. The surgeon infiltrates adjusted doses of lidocaine, adrenaline and bicarbonate.

Vasoconstriction and following haemostatic control is obtained when using adrenaline, allowing continuing the procedure without an ischemic handle or tourniquet. It does not require sedation, regional or general anaesthesia. Furthermore, patient remains fully conscious during the procedure.

## Methods

### WALANT Technique on forefoot surgery

Several advantages have been demonstrated when using the WALANT technique on hand procedures: it does not require pre-operative tests, nor pre-anaesthetic assessment. Moreover, it is a consistent and reproducible method, which can be executed by the surgeon; therefore, it does depend on an anaesthesiologist being present [3,4].

Despite the concern regarding the vasoconstriction caused by the adrenaline used in this technique, many level 1 evidence-based studies have consistently demonstrated the use of adrenaline does not represent a risk when used on fingers. Fentolamine can be used as an antidote when persistent vasoconstriction appears [5,6].

In contrast with its use in upper limb surgery in which the WALANT technique has been widely described and used, when it comes to Foot and Ankle it is not as extensible described; therefore our team has had to customise it to foot anatomy to be able to apply it.

Patient arrives in the outpatient surgery area. No peripheral intravenous line is required, except when antibiotic prophylaxis is mandatory. If the patient is anxious 1mg of midazolam intravenous may be used, just before the anaesthetic technique starts. It is basic and vital, the treating surgeon explains the anaesthetic technique

and the following surgery, giving information about the time of the procedure, noise experienced inside the OR and what they should expect to perceive during the surgery.

In a 20cc syringe, it is proceeded to prepare the solution on the WALANT. It is compounded by 0,1cc adrenaline (1:100.00), 5cc lidocaine 2%, 5 cc saline solution and 2cc sodium bicarbonate (Figure 1). In our hospital compound, to avoid the inevitable human error, the previously described combination except the sodium bicarbonate is prepared and packed on preloaded syringes by the Pharmacy department. When preparing the field to infiltrate, sodium bicarbonate is added to avoid it from precipitation when including it too soon.

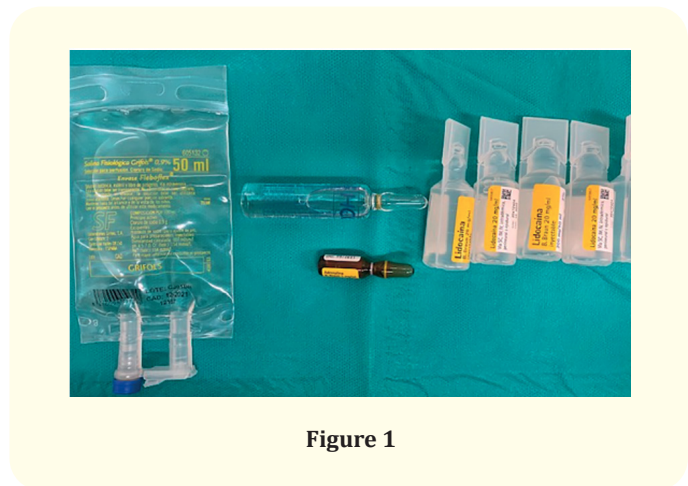

Figure 1

Surgeries such as Akin or Weil osteotomy and Morton neuroma, 10cc are used. Midfoot and complex forefoot surgeries, like scarf, chevron or multiple Weil osteotomies, a 20cc solution is advised.

Using preloaded syringes and 21G needles, the surgeon proceeds to infiltrate (Figure 2). Starting at the subcutaneous tissue and moving forward to deeper tissues until periosteum is reached; 21G needles can be swapped for 18G to advance to deeper tissues. It is advised to avoid intradermal infiltrations since it might cause unnecessary pain.

A minimum of three injection entries is required. A 21G needle is used to start injecting the proximal medial aspect of the first metatarsal, advancing to the dorsal aspect and slowly infiltrating 3cc to 4cc followed by the installation of the plantar aspect with another 3cc to 4 cc. From the medial aspect the metatarsophalangeal

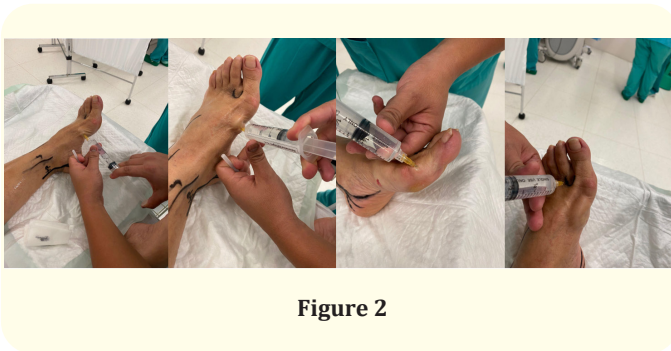


Figure 2

joint is infiltrated with 3cc to 4cc and finally the remaining volume is used for the first commissure.

For a successful painless bloodless procedure, timing is key. 30 minutes are mandatory.

## Results and Discussion

The WALANT technique has demonstrated efficacy, safety and patient satisfaction, as well as cost-effectiveness in hand surgery. However, little literature mentions its use in foot and ankle [7]. Bilgetekin, *et al.* evaluated a total of 31 patients who underwent foot and ankle surgery with WALANT, concluding that this technique generates satisfactory results with low patient anxiety and pain, as well as a low rate of complications and a low average length of stay [7].

Poggetti, *et al.* demonstrated a significant reduction in postoperative pain and hospital stays. This group did not achieve differences in postoperative complications, finally concluding that this technique could be a good option in selected patients, with clinical and economic advantages compared to traditional techniques with regional block and tourniquet [8].

We believe that the WALANT technique does not represent a painful technique for the patient and does not increase the level of anxiety, saving the use of tourniquet. It does not require the use of sedation; the patient is awake during the procedure, where functionality can be assessed by requesting the patient to move the foot or toes. However, the WALANT technique is not recommended in highly apprehensive or refusing patients.

## Conclusion

The WALANT foot and ankle technique is a safe and affordable technique and has a low complication rate. With the tendency in many countries' health resources, and decreased capacity in central operating rooms, this technique represents an appropriate alternative to consider in cases of foot and ankle surgery in patients who are suitable for the technique.

## Bibliography

1. Vadivelu N., *et al.* "Role of regional anesthesia in foot and ankle surgery". *Foot and Ankle Specialist* 8.3 (2010): 212-219.
2. Guevara-Noriega KA., *et al.* "Coagulation Panel in Patients with SARS-CoV-2 Infection (COVID-19)". *Annals of Clinical and Laboratory Science* 50.3 (2020): 295-298.
3. Lalonde D. "Minimally invasive anesthesia in wide awake hand surgery". *Hand Clinics* 30.1 (2014): 1-6.
4. Abdullah S., *et al.* "Wide Awake Local Anesthesia No Tourniquet Forearm Triple Tendon Transfer in Radial Nerve Palsy". *Plastic and Reconstructive Surgery-Global Open* 8.8 (2020): e3023.
5. Hagert E and Lalonde D. "Time to bury the adrenaline-myth! --Safe use of adrenaline anesthesia in hand surgery and orthopedics". *Lakartidningen* 112 (2015): C4MC.
6. Mckee DE., *et al.* "Achieving the optimal epinephrine effect in wide awake hand surgery using local anesthesia without a tourniquet". *Hand (N Y)* 10.4 (2015): 613-617.
7. Bilgetekin YG., *et al.* "The use of the wide-awake local anesthesia no tourniquet technique in foot and ankle injuries". *Foot and Ankle Surgery* S1268-7731.20 (202): 30141-30147.
8. Poggetti A., *et al.* "A local anesthesia without tourniquet for distal fibula hardware removal after open reduction and internal fixation the safe use of epinephrine in the foot. A randomized clinical study". *Journal of Biological Regulators and Homeostatic Agents* 326-1 (2018): 57-63.