



New Strategies for Development of Home Exercise to Prevent Surgery in Patients with Hip Osteoarthritis: Considerations of Pericapsular Soft Tissue as a Pain Generator

Kazuo Hayashi^{1*} and Toshiharu Tsunoda²

¹Arthritis Center, Fukuoka Wajiro Hospital, Japan

²Department of Orthopedic Surgery, Asama General Hospital, Japan

*Corresponding Author: Kazuo Hayashi, Arthritis Center, Fukuoka Wajiro Hospital, Japan.

E-mail: hayashis@giga.ocn.ne.jp

Received: February 13, 2019; Published: March 18, 2019

Abstract

Most patients with hip osteoarthritis complain of hip pain on standing and when taking their first few steps, with decreased hip pain as they continue walking. On some days, they have either no pain or very slight pain. This motion pain seems to result from joint contracture and improve with exercise therapy. Several patients complain of walking pain caused by contact with the subchondral bone secondary to loss of cartilage from the joint surface, and there are no days on which these patients have no pain or very slight pain. Patients with this severity of walking pain require surgery. We propose that diagnosis and treatment of malalignment syndrome should be applied in patients with motion pain.

Keywords: Hip Osteoarthritis; Home Exercise; PSTR Exercise; Postpone or Prevent Surgery; Harris Hip Score (HHS); Malalignment Syndrome

Abbreviations

OA: Osteoarthritis; HHS: Harris Hip Score; THA: Total Hip Arthroplasty; PSTR Exercise: Pericapsular Soft Tissue and Realignment Exercise.

Introduction

Most studies of exercise for hip osteoarthritis (OA) have included participants with mild to moderate hip OA. Fernandes, *et al.* [1] and Svege, *et al.* [2] reported that the inclusion criteria for exercise therapy should include a Harris hip score (HHS) of 60 to 95 points, whereas they recommended total hip arthroplasty (THA) for patients with an HHS of <60 points. Bennell, *et al.* [3] reported that among adults with painful hip OA, physical therapy did not result in greater improvement in pain or function compared with sham treatment. However, patients with an HHS of <60 points may have a stronger desire to postpone surgery than patients with an HHS of >60 points. Most patients with an HHS of >60 points do not have much disturbance in their activities of daily living. The main reasons for avoiding or postponing surgery are work, child-rearing, or caring for one's parents. Long-term treatments that can postpone or prevent surgery and allow patients to exercise

at home while continuing to work are needed. Manual therapies that require hospital visits are not suitable as such long-term treatments. Home exercises are suitable to postpone or prevent surgery. From 1998 to 2006, we treated patients with hip OA using an open kinetic chain exercise to strengthen the hip abductors of the gluteus medius and stretching. This open kinetic chain exercise involves raising and lowering the leg on the affected side. However, it did not alleviate symptoms or improve function in patients with an HHS of <60 points. Most studies that have examined exercise as a nonsurgical treatment for hip OA have involved strength training, stretching, functional training, and aerobic fitness programs [4]. Therefore, we considered the development of a new home exercise to postpone or prevent surgery.

Discovery of different mechanisms of hip pain

In our clinical experience, many patients with hip OA, even those with an HHS of <60 points, have motion pain resulting from joint contracture. In these patients, pain occurs on standing and when taking their first steps but decreases during walking. Motion pain seems to improve with exercise therapy, whereas pain caused by subchondral bone exposure on the joint surface during walking

may require surgical treatment. In addition, patients with motion pain complain that some days they have no pain or very slight pain, whereas patients with walking pain have no such days. Detailed analysis of the patient's complaint is necessary to select the most suitable treatment for each patient. To our knowledge, even most recent studies have not reported the detailed analysis of the patient's complaint [5-8].

Development of pericapsular soft tissue and realignment exercises

Worsening hip OA results in anterior pelvic tilt, elevation of the greater trochanter, and adduction contracture of the affected hip [9,10]. Anterior pelvic tilt and elevation of the greater trochanter of patients with hip OA can cause an apparent shortening of the leg length on the affected side. This apparent difference in leg length can result in instability while walking (Figure 1). We also

showed this condition in the Supplementary Information of the Journal of Physiotherapy and Physical Rehabilitation [11]. We considered that this instability may cause repetitive injury to the pericapsular soft tissues (joint capsule, ligaments, inner muscles), resulting in contracture of the affected hip. Thus, correction of pelvic malalignment before a strengthening exercise is necessary to decrease motion pain. In 2007, we introduced pericapsular soft tissue and realignment (PSTR) exercises that Teruo Ooyati (Shiatsu therapist, Osaka, Japan) had developed over a 20-year period to prevent or postpone surgery for patients with an HHS of <60 points. Performance of PSTR exercise is a part of the Yuki program developed by Teruo Ooyati [12]. Correction of apparent leg length difference due to pelvic malalignment on the affected hip seemed not to have been tried in the previous studies[4-6]. Therefore, the indication of exercise therapy for the patients with hip OA might have been limited to mild to moderate cases [13].

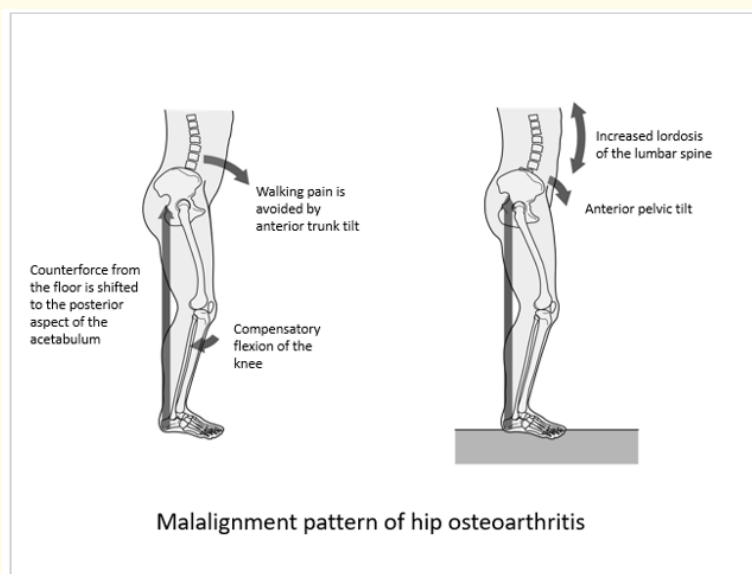


Figure 1: Pain when standing and walking is avoided by tilting the trunk forward. Release of pain generators such as bradykinin from the damaged cartilage site may be reduced by tilting the trunk forward. The counterforce from the floor is shifted to the posterior aspect of the acetabulum. This force causes anterior pelvic tilt and lumbar lordosis.

Dramatic effects of PSTR exercises as a new home exercise

A retrospective study of 285 patients who fulfilled the inclusion criteria among 1077 patients who underwent PSTR exercises showed a significant improvement in the HHS among patients with a baseline HHS of <60 points (Figure 2). We showed an illustration of the PSTR exercises in the Supplementary Information of the Journal of Physiotherapy and Physical Rehabilitation [11]. We consider that exercise for the lower back and correction of apparent differences in leg lengths are the most effective exercises. Most patients with

motion pain have walking instability due to apparent shortening of the leg length on the affected side caused by anterior pelvic tilt and elevation of the greater trochanter. This apparent shortening of the leg length causes hardening of the erector spinae on the affected side, resulting in walking instability. This walking instability cause repetitive pericapsular soft tissue injury to the joint capsule, ligaments, and inner muscles, resulting in contracture of the affected hip. Most patients complain of motion pain while walking home from work or during the night at home, whereas they have no

pain or very slight pain during walking to work in the morning. In addition to hip pain, they also sometimes experience heavy thigh or calf pain at night. This motion pain is considered to be caused by walking instability in the daytime. Therefore, exercise for the lower back and correction of apparent differences in leg lengths to increase flexibility of the erector spinae is the most effective treatment to decrease motion pain. It appears that in many cases, patients with motion pain are considered to have malalignment syndrome [14] due to hip OA. Moreside, *et al.* [15] investigated the erector spinae surface electromyography on 19 individuals with severe hip OA [SOA], 20 with moderate hip OA [MOA], and 19 asymptomatic [ASYM] individuals during treadmill walking. With increasing OA severity, bilateral erector spinae activity increased during the swing phase of gait [$p < 0.001$], whereas during stance, the SOA ipsilateral erector spinae activity was higher than other groups [$p < 0.001$]. With moderate and severe OA, sagittal and frontal trunk motion increased during gait. We consider that investigation regarding erector spinae of patients with moderate to severe OA of the hip will be important in future. There is no conclusive evidence of the effectiveness of PSTR exercises because the above-mentioned study was a retrospective observational study with no controls. We have begun a multicenter prospective single-arm study to confirm the effectiveness of this program [16].

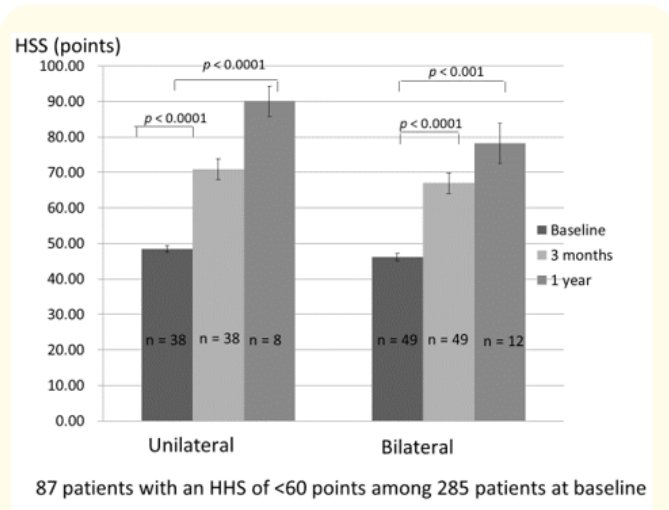


Figure 2: Of 1,077 patients with hip osteoarthritis who underwent pericapsular soft tissue and realignment exercises, 792 patients were excluded because they met the exclusion criteria and 285 patients fulfilled the inclusion criteria. Of these 285 patients, 87 had a Harris hip score of <60 points. Unilateral: Group of patients with unilateral hip osteoarthritis (no pain in the opposite hip). Bilateral: Group of patients with bilateral hip osteoarthritis (pain in the opposite hip). HHS, Harris hip score. Two-sided $P < 0.05$ was significant.

Decontracture test to differentiate between motion pain and walking pain

We developed a decontracture test to differentiate between motion pain and walking pain. Decontracture may be a useful method to ease joint stiffness. We plan to investigate the ability of the decontracture test to differentiate between motion pain and walking pain and thus determine surgical indications in future studies. We plan to present “a decontracture test” using video slide at the World Congress of Orthopaedics 2019 [17].

Association of hip pain with radiographic evidence of hip OA

Kim, *et al.* [18] reported that hip pain was discordant with radiographic hip OA. In their report, pain was not present in many hips with evidence of OA on radiographs, and many painful hips did not show radiographic evidence of hip OA. In contrast, Iidaka, *et al.* [19] reported that hip pain was strongly associated with Kellgren Lawrence grade >3 OA. We reported that symptoms improved markedly as a result of PSTR exercises even in patients with loss of joint cartilage. Partial or total loss of cartilage is not directly related to hip pain [11]. We consider that investigation of the characteristics of hip pain (motion pin or walking pain) is important for resolution of this problem [20]. In future, we plan to investigate the association between the characteristics of hip pain and radiographic findings in addition the effect of PSTR exercises in patients with loss of cartilage [16]. We have examined MRI findings of all patients with hip OA [11] and could not find the difference of MRI findings between patients with motion pain and ones with walking pain.

Basic research regarding the distribution of free nerve ending and nociceptive receptor in subchondral bone

Witt, *et al.* [21] performed a review and found that in animal studies, the subchondral bone was innervated with substance P immunoreactive nociceptive fibers that may be involved in pain generation in OA. However, Fortier, *et al.* [22] reported that the normal subchondral bone nerve supply was obliterated in areas of advanced arthritis, with cartilage loss, bony eburnation, and cyst formation. Hypercellular infiltrates in cystic cavitations in the subchondral bone stained intensely for substance P, but true neurofilaments were absent in horses. We consider that the relationship between the characteristic of hip pain (motion pain or walking pain) and the innervation of the subchondral bone should be investigated in future basic research.

Low back pain related to hip OA

In our study, the Mental Component and Role/Social Component summary scores on the 36-Item Short-Form Health Survey improved in both the unilateral OA and bilateral OA groups to near 50 points according to norm-based scoring. However, the Physical

Component summary score improved only slightly, remaining below 50 points according to norm-based scoring (Figure 3 and 4). Low back pain may have contributed to the low Physical Component summary scores. A lumbosacral or sacroiliac disturbance may have also been involved [9,10]. We plan to develop new exercises to address these issues and establish guidelines for the timing of hip surgery based on screening involving PSTR exercises. Wang W., *et al.* [23] reported that the low back pain might be the most common comorbidity of hip OA, with reported incidence of 21.2% to 100%. Both the abnormal sagittal spine-pelvis-leg alignment and reduced hip range of motion might be involved in the mechanism of the low back pain, hence restoration of the alignment and improvement of the hip range of motion should be aimed in treating hip OA. THA is not only treating the hip pathology, but also the low back pain without spinal disorders. Several studies reported the effect of THA on sagittal spinal-pelvic-leg alignment and low back pain in patients with severe hip OA [24-26]. We experienced the improvement of the mild low back pain in patients with moderate to severe hip OA using PSTR exercises. When low back pain becomes to be moderate or severe due to hip OA, this low back pain should be treated by THA. However moderate to severe low back pain continues after THA when the timing of THA is too late, resulting in disturbances in activities of daily living even if THA improves hip pain and function.

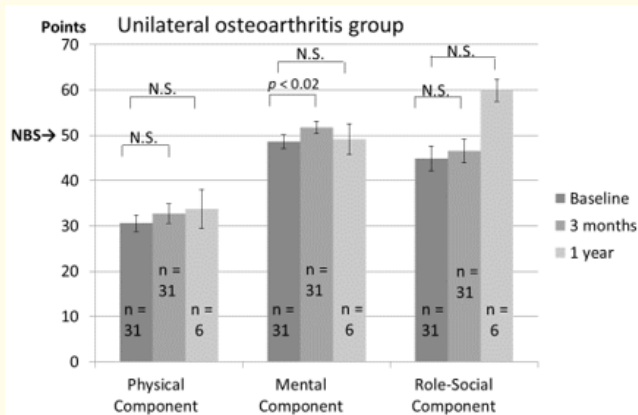


Figure 3: 36-Item Short-Form Health Survey summary scores in accordance with a Harris hip score of <60 points at baseline in the unilateral osteoarthritis group. NBS, norm-based score; Two-sided $P < 0.05$ was significant. N.S., not significant.

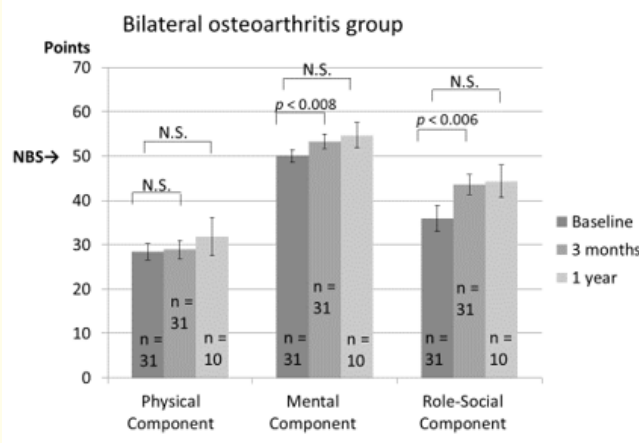


Figure 4: 36-Item Short-Form Health Survey summary scores in accordance with a Harris hip score of <60 points at baseline in the bilateral osteoarthritis group. NBS, norm-based score; $P < 0.05$ was significant. N.S., not significant.

Management of postoperative pain in the lower extremity

Many studies reported postoperative pain in a short period after hip surgery during hospital stay [27-29]. The treatment consists of non-steroid anti-inflammatory drugs, local infiltration analgesia, intrathecal opioids, and lumbar plexus block. Many patients who have undergone surgery such as THA complain of postoperative pain in the lower extremity or low back pain, especially after discharge from the hospital. Erlenwein J., *et al.* [30] reported that six months after THA, between 26% and 58% of patients still had hip pain. Patients with moderate to severe persistent pain intensity (>3 on a numerical rating scale) were more restricted in their daily life activities. Regarding persistent postoperative pain, most patients are explained by doctors that there are no problems about surgery even if patients complain of postoperative pain such as pain in groin, thigh, calf, buttock, and low back. These explanations are performed not for patient's symptoms, but for only roentgenography findings. This may cause distrust of patients to treatment. PSTR exercises can improve this type of postoperative pain. We consider that malalignment syndromes present before surgery were not improved by surgery alone in these cases.

Regenerative medicine of cartilage

Regenerative medicine to regenerate cartilage with induced pluripotent stem cells or cell sheets represents a new prospect for the future treatment of OA [31-34]. Nonetheless, even if cartilage is regenerated, OA may recur if malalignment of the lumbar spine, pelvis, and lower extremities is not corrected and restricted range of motion is not increased. We plan to develop preoperative PSTR exercises as part of regenerative medicine. In addition, we suspect that patients with motion pain will not achieve alleviation of symptoms and improvement in function if cartilage is regenerated without correction of malalignment of the lumbar spine, pelvis, and lower extremities. We consider that walking instability caused by malalignment of the lumbar spine, pelvis, and lower extremities needs to be corrected before cartilage regeneration.

Conclusion

Pericapsular soft tissue should be considered as a pain generator in hip OA. Diagnosis and treatment of malalignment syndrome should be applied in patients with motion pain. Detailed analysis of the patient's complaint is necessary to select the most suitable treatment for each patient. Both narrative-based medicine and evidence-based medicine are important in this setting.

Acknowledgment

We thank Angela Morben, DVM, ELS, from Edanz Group (www.edanzediting.com/ac), for editing a draft of this manuscript.

Conflict of Interest

None.

Bibliography

1. Fernandes L., et al. "Efficacy of patient education and supervised exercise vs patient education alone in patients with hip osteoarthritis: a single blind randomized clinical trial". *Osteoarthritis and Cartilage* 18 (2010): 1237-1243.
2. Svege L., et al. "Exercise therapy may postpone total hip replacement surgery in patients with hip osteoarthritis: a long-term follow-up of a randomized trial". *Annals of the Rheumatic Diseases* 74 (2015): 164-169.
3. Bennell KL., et al. "Effects of physical therapy on pain and function in patients with hip osteoarthritis: a randomized clinical trial". *Journal of the American Medical Association* 311 (2014): 1987-1997.
4. Fransen M., et al. "Exercise for osteoarthritis of the hip". *Cochrane Database of Systematic Reviews* 22 (2014): CD007912.
5. Uusi-Rasi K., et al. "Exercise in treatment and rehabilitation of hip osteoarthritis: A 12-week pilot trial". *Journal of Osteoporosis* (2017): Jan 1. Doi: (10.1155/2017/3905492).
6. Moseng T., et al. "The importance of dose in land-based supervised exercise for people with hip osteoarthritis. A systematic review and meta-analysis". *Osteoarthritis and Cartilage* 25 (2017): 1563-1576.
7. Schiphof D., et al. "Osteoarthritis year in review 2017: rehabilitation and outcomes". *Osteoarthritis and Cartilage* 26 (2018): 326-340.
8. Collins NJ., et al. "Osteoarthritis year in review 2018: rehabilitation and outcomes". *Osteoarthritis and Cartilage* 27 (2019): 378-391.
9. Yoshimoto H., et al. "Spinopelvic alignment in patients with osteoarthritis of the hip: a radiographic comparison to patients with low back pain". *Spine* 30 (2005): 1650-1657.
10. Weng WJ., et al. "Characteristics of sagittal spine-pelvis-leg alignment in patients with severe hip osteoarthritis". *European Spine Journal* 24 (2015): 1228-1236.
11. Hayashi K., et al. "Dramatic effects of new home exercises for patients with osteoarthritis of the hip: pericapsular soft tissue and realignment exercises". *Journal of Physiotherapy & Physical Rehabilitation* 3 (2018): 162-173, Supplementary Information.
12. Hayashi K. "Dramatic effects of a new home exercise to improve hip function for patients with osteoarthritis". *Osteoarthritis Cartilage* 23 (2015): A165-A166.
13. White DM., et al. "Physical therapy and hip osteoarthritis". *Journal of the American Medical Association* 312 (2014): 1257-1258.
14. Schamberger W. "The Malalignment Syndrome". (2nd edn). In: *Diagnosis and treatment of common pelvic and back pain*. Churchill Livingstone, London. (2012)
15. Moreside J. "Altered erector spinae activity and trunk motion occurs with moderate and severe unilateral hip OA". *Journal of Orthopaedic Research* 36 (2018): 1826-1832
16. Hayashi K., et al. "Investigation regarding effects of PSTR (pericapsular soft tissue and realignment) exercises to improve function in patients with osteoarthritis of the hip and a Harris Hip Score (HHS) below 60 points". (UMIN000028277) (2017).

17. Hayashi K, *et al.* "Dramatic Effects of New Home Exercises for Hip Osteoarthritis - Considerations of Pericapsular Soft Tissue as a Pain Generator". in Chapter 3:Frontier of Basic Orthopaedic Research and Tech Innovations. World Congress of Orthopaedics Dailian, China (2019).
18. Kim C., *et al.* "Association of hip pain with radiographic evidence of hip osteoarthritis; diagnostic test study". *The BMJ* 351 (2015): 1-8.
19. Iidaka T, *et al.* "Prevalence of radiographic hip osteoarthritis and its association with hip pain in Japanese men and women; the ROAD study". *Osteoarthritis and Cartilage* 24 (2016): 117-123.
20. Greenhagh T, *et al.* "Narrative-Based Medicine: Dialogue and Discourse in Clinical Practice". *BMJ* Publishing, London. (1998).
21. Witt KL, *et al.* "The anatomy of osteoarthritic joint pain". *Clinical Anatomy* 27 (2014): 451-454.
22. Fortier LA, *et al.* "Distributional changes in substance P nociceptive fiber patterns in naturally osteoarthritic articulations". *The Journal of Rheumatology* 24 (1997): 524-530.
23. Wang W, *et al.* "The low back pain in patients with hip osteoarthritis: current knowledge on the diagnosis, mechanism, and treatment outcome". *Annals of Joint* 1.9 (2016): doi: 10.21037/aoj.2016.0603.
24. Weng W *et al.* "The effect of total hip arthroplasty on sagittal spinal-pelvic-leg alignment and low back pain in patients with severe hip osteoarthritis". *European Spine Journal* 25 (2016): 3608-3614.
25. Piazzolla A, *et al.* "Spinopelvic parameter changes and low back pain improvement due to femoral neck anteversion in patients with severe unilateral primary hip osteoarthritis undergoing total hip replacement". *European Spine Journal* 27 (2018): 125-134.
26. Eguchi Y, *et al.* "Spinopelvic Alignment and Low Back Pain after Total Hip Replacement Arthroplasty in Patients with Severe Hip Osteoarthritis". *Asian Spine Journal* 12 (2018): 325-334.
27. Hojer KP, *et al.* "Postoperative pain treatment after total hip arthroplasty: a systematic review". *Pain* 156 (2015): 8-30.
28. Erlenwein J, *et al.* "The Influence of Chronic Pain on Postoperative Pain and Function After Hip Surgery: A Prospective Observational Cohort Study". *The Journal of Pain* 17 (2016): 236-247.
29. Benditz A, *et al.* "Postoperative pain and patient satisfaction are not influenced by daytime and duration of knee and hip arthroplasty: a prospective cohort study". *Archives of Orthopaedic and Trauma Surgery* 137 (2017): 1343-1348.
30. Erlenwein J, *et al.* "Clinical relevance of persistent postoperative pain after total hip replacement – a prospective observational cohort study". *The Journal of Pain Research* 10 (2017): 2183-2193
31. Takahashi K, *et al.* "Induction of pluripotent stem cells from mouse embryonic and adult fibroblast cultures by defined factors". *Cell* 126 (2006): 663-676.
32. Sato M, *et al.* "Articular cartilage regeneration using cell sheet technology". *Anatomy Tech* (Hoboken) 297 (2014): 36-43.
33. Uto S, *et al.* "Application of induced pluripotent stem cells for cartilage regeneration in CLAWN miniature pig osteochondral replacement model". *Regenerative Therapy* 9 (2018): 58-70.
34. Murphy C, *et al.* "The Potency of Induced Pluripotent Stem Cells in Cartilage Regeneration and Osteoarthritis Treatment". *Advances in Experimental Medicine and Biology* 1079 (2018): 55-68.

Volume 2 Issue 4 March 2019

© All rights are reserved by Kazuo Hayashi.