

Arthroscopic Management of Post Traumatic Anterolateral Soft Tissue Ankle Impingement

Adel Abdel Azim Ahmad¹, Mohamed Othman^{1*} and Hossam Fathi²

¹Assistant Professor, Department of Orthopedics, Faculty of Medicine, Zagazig University, Egypt

²Lecturer, Department of Orthopedics, Faculty of Medicine, Zagazig University, Egypt

*Corresponding Author: Mohamed Othman, Assistant Professor, Department of Orthopedics, Faculty of Medicine, Zagazig University, Egypt.

Received: August 03, 2018; Published: September 25, 2018

Abstract

Purpose: The purpose was to evaluate the results of arthroscopic management of anterolateral soft tissue ankle impingement (ALSTAI) secondary to ankle inversion injuries.

Patients and Methods: We treated 27 cases of ALSTAI by arthroscopic debridement between Jan 2015 and Dec 2016. We excluded cases with associated chondral lesions, mechanical instability. Bony impingement and arthritic ankles.

Results: After a mean follow-up period of 15 months (12 - 240, 24 cases (88%) had complete pain relief while 3 cases (12%) still had pain with strenuous activities. The AOFAS score improved from 42 pre-operative to 88 post-operative (P value = 0.0001). According to Meislen criteria, 14 cases were excellent (51.8%), 10 cases (37.1%) were good while three cases (11.1%) were fair, but no poor results. There was no major postoperative complications in any patient. The reported complications were minor and few; temporary paresthesia of the dorsum of the foot in two and peri-portal superficial infection in two, that resolved with antibiotics and local care.

Conclusion: Arthroscopic debridement of the ankle proved to be effective and safe in management of anterolateral soft tissue ankle impingement subsequent to ankle inversion injuries.

Keywords: Ankle Arthroscopy; Ankle Impingement Anterolateral Soft Tissue Impingement; Posttraumatic Chronic Ankle Pain; Ankle Arthroscopic Debridement

Introduction

Persistent ankle pain, swelling and functional disability following inversion injuries of the ankle is not uncommon, despite proper conservative management [1-4]. Numerous causes can account for this, including residual ankle instability, soft tissue or bony impingement, and chondral/osteochondral injuries. One or more of the previous pathologies can co-exist; explaining for persistent disability [2-5].

Anterolateral soft tissue ankle impingement (ALSTAI) can occur after one, or more often, repeated inversion injuries and is a common, but frequently neglected, cause of chronic pain [6] and recently, it got more attention. Therefore, it should be suspected in any case of chronic ankle pain secondary to a sprain [3-5].

Such trauma may result in tearing of the anterolateral soft tissues and ligaments without substantial associated mechanical instability. Repeated microtrauma can lead to hypertrophied synovial tissue and scar tissue in the anterolateral gutter of the ankle, which become entrapped in the lateral gutter with movement (Figure 1), causing mechanical impingement and pain [5-10]. In advanced cases, mechanical impingement may mold the tissue into a hyalinized meniscoid lesion, which was originally described by Wolin., *et al* [11,12]. Other impinging factor is hypertrophy of an accessory fascicle of the anterior inferior tibiofibular ligament (AITFL) [7,8,13]. This accessory fascicle is a common variant that

was first described by Bassett., *et al* [14]. It can hypertrophy after repeated trauma, causing impingement, especially when other anterolateral supporting structures are compromised [10,13].

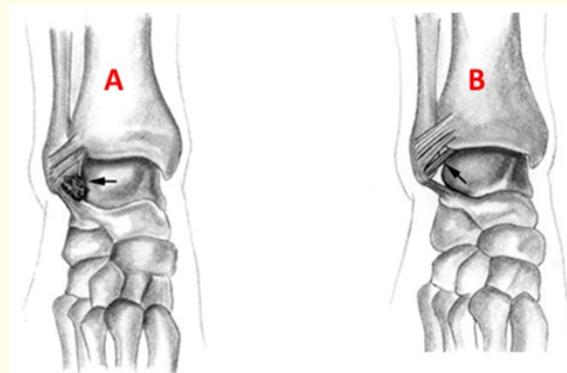


Figure 1: Diagrams showing: [A] Site of anterolateral impingement; [B] Ligament of bassett [14].

The diagnosis of ALSTAI is based mainly on history and physical examination [2-11,13]. It should be suspected in any case of chronic complaints after an ankle sprain [3,4]. It can be highly suggested on clinical basis [5-8]. The principal role of plain radiographs, CT and MRI should be in differential diagnosis and detection of other causes of anterolateral ankle pain as bony impingement,

osteochondral lesions and ankle instability [13,15-17]. Ankle arthroscopy is the gold standard for diagnosis and assessment of ALSTAI [3,4,13,15-18].

Successful treatment of this disability depends on proper identification of the exact leading pathology [7-10]. With the advent of ankle arthroscopy better identification and management of persistent pain following inversion injuries of the ankle can be achieved [15-18].

Aim of the Study

The aim of the present study was to evaluate the results of arthroscopic management of anterolateral soft tissue impingement of the ankle (ALSTAI) secondary to inversion injuries of the ankle.

Patients and Methods

A prospective study was executed at our institution, between January 2015 to December 2016, on arthroscopic management of anterolateral soft tissue ankle impingement (ALSTAI) subsequent to ankle inversion injuries in 27 ankles (27 patients), after authorization by the local Ethical Committee.

Twenty-one cases had right side affection while six cases had left side affection. The mean age was 29.5 years (Range: 17 - 49). Four cases were females while 23 cases were males. Seventeen cases had single episode of inversion ankle injury while ten cases had recurrent inversion injuries. The chief complaints of these patients pre-operatively were recurrent attacks of anterolateral ankle pain, ankle swelling, limited ankle movement and limited functional activity.

The mean time elapsed from the last episode till presentation was 112 days (Range: 92 - 371 days). Only cases with ALSTAI secondary to ankle inversion injuries not responding to conservative treatment for at least three months were included in this study. We excluded other causes of persistent disability such as bony impingement, osteochondral lesions, mechanical instability, ankle with degenerative or inflammatory arthritis, or preexisting deformity, cases with less than 12 months-follow-up, and bilateral cases (to make comparison valid).

Preoperative assessment

- Diagnosis of ALSTAI relied mainly on history and clinical examination findings. Infiltration with local anesthetics was done in case of doubt, and relief of pain was an indicator of the diagnosis [17]. All the patients were examined for ankle instability
- Plain radiographs (anteroposterior and lateral projections) and MRI were done routinely for all cases, principally for exclusion of other causes and differential diagnosis.
- The American foot and ankle society score [19] was calculated pre- and post-operatively for comparison.

Preoperative assessment

Surgery was done with the patient in supine position under spinal or epidural anaesthesia with tourniquet applied to the upper thigh. The principal steps were:

- The ankle was approached through standard anteromedial and anterolateral portals, taking care to protect the neurovascular structures. Both portals were landmarked (Figure 2) and the skin was opened at first. The anteromedial portal was placed just medial to tibialis anterior tendon at the level of the ankle joint. The anterolateral portal placement needed more accurate localization, to avoid injury to the superficial peroneal nerve with subsequent painful neuroma. At first, the superficial peroneal nerve was identified by planter flexion and eversion of the ankle with plantar flexion of the 4th toe (4th toe sign) with that maneuver the superficial peroneal nerve was prominent [20]. Skin is incised few millimeters medial to the superficial peroneal nerve. After portals were landmarked, the skin was incised with scalpel, then the capsule was opened bluntly with small artery forceps starting with the anteromedial portal first then the anterolateral portal. A sterile crepe bandage was applied to the foot to allow for intermittent distraction when needed, and for plantarflexion and dorsiflexion of the foot.
- Using a 4 mm 30° angled arthroscope, routine visualization of the ankle joint was performed. The impinging tissues (hypertrophic synovium, fibrous adhesions, meniscoid lesions, or hypertrophied distal fascicle of the AITFL) were arthroscopically visualized, and resected using an oscillating shaver.
- The articular cartilage was inspected thoroughly. Associated cartilage damage of the anterolateral aspect of the dome of the talus ranging from grade I to II was seen in two of the patients, and they were treated with shaving to clean the cartilage fibrillation.
- An arthroscopic translation test of the distal tibiofibular joint was performed in all patients. While holding the distal third of tibia with one hand, the lateral malleolus was moved forwards and backwards. A translation of > 3 mm was considered as abnormal movement of syndesmosis [8,17].

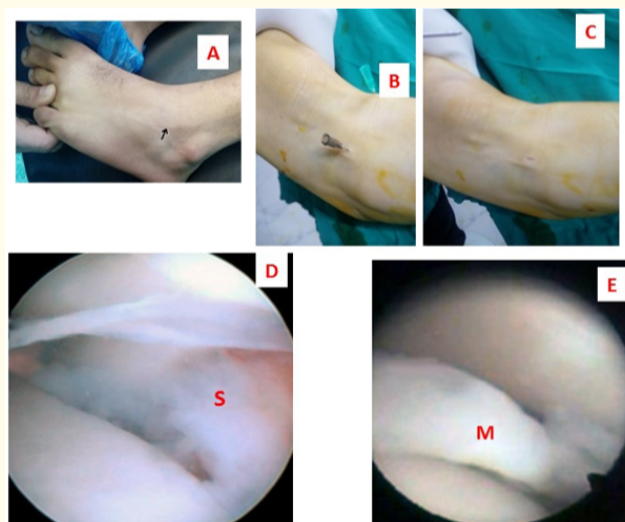


Figure 2: [A-C] Localization of portal placement during anterior ankle arthroscopy; [C] Arthroscopic view of hypertrophied synovium and scar (marked by S); [D] Meniscoid lesion (marked by M).

A suction drain was used for all cases, to be removed 48 hours after surgery. Finally, a crepe bandage was applied to the ankle.

Postoperative care and follow-up

Intermittent ice packs were applied to the ankle and active ankle motions were encouraged on the day of surgery. Partial weight bearing was allowed for the first three weeks progressing to full weight bearing by 6 - 8 weeks as tolerated by the patient. Physiotherapy was started on day one, that involved gentle passive ankle ROM and progressing to proprioceptive exercises and strength training by 6-8 weeks. The patients were followed-up regularly till the final follow-up.

Postoperative and final evaluation

The patients were assessed:

- (A) Clinically: for pain, local signs and ROM.
- (B) Using three ankle scores; the AOFAS scoring system [19], Meislen’s score [21], and Liu., *et al.*’s score [6].

The AOFAS scoring system [19] includes main indexes such as pain, patient ambulatory function, and ankle joint movement limitations. It involves up to 100 points, and is classified as excellent (90 to 100), good (80 to 89), fine (70 to 79), and poor (< 70).

Meislin criteria [21] have 3 indicators including: pain during rest and activity, clinical examination, and patient self-evaluation (Table 1).

	Pain at Rest or with Activity	Physical Examination	Self-assessment
Excellent	None	Normal	Normal
Good	None	No tenderness, minimal swelling	Greatly improved
Fair	Minimal pain with activities	Minimal/moderate tenderness, moderate swelling, instability	Somewhat improved
Poor	Pain at rest, moderate/severe; pain with activity	Severe swelling, limitation of range of motion	Unchanged or worse

Table 1: Meislin criteria [21].

Liu., *et al.* [6] proposed a score for final assessment of the ability to return to work or previous level of athletic activity, using four grades; grade 0, no limitation of athletic activities and return to previous employment; grade I, no limitation of athletic activities despite mild pain, with some discomfort at work; grade II, moderate limitation of athletic activities or moderate limitation at work; and grade III, inability to return to athletic activities or employment.

Statistical analysis

Results were expressed as means ± SD (standard deviation). The differences between pre- and post-operative data were analyzed by Paired T test. A statistical significance was set at p < 0.05.

Results

Arthroscopic findings

- (a) Impinging soft tissues: (1) Synovial hypertrophy and scar tissue mainly in the anterolateral gutter of ankle was found in all cases, (2) meniscoid lesion in one ankle, and (3) hypertrophied accessory band of AITFL (Basset ligament) in one ankle. All these lesions were removed using motorized shaver.
- (b) The articular cartilage (AC) overlying the distal tibia and talus was normal in 20 cases, but seven cases (25.9%) showed associated AC changes of the anterolateral aspect of talus dome; softening (grade I) in five and superficial fibrillation (grade II) in two, but with no case of complete eburnation with subchondral bone exposure.
- (c) No mechanical instability of ankle.
- (d) No intraoperative complications

The final outcome

The average follow up period was 15 months (Range: 12 - 24 months). None of the patients was lost from follow - up.

- (a) At the final follow up, 24 cases (88.9%) get complete pain relief, while 3 cases (11.1%) still have ankle pain with strenuous activities, these cases had articular fibrillation revealed during arthroscopic evaluation. The ROM improved in all cases except in two, who showed residual limitation of 15 - 20° in planter-/dorsi-flexion range. Anterolateral swelling disappeared in all except in two, who showed mild swelling after activity.
- (b) There was no major postoperative complications in any patient. The reported complications were minor and few. Two cases had temporary parathesia of the dorsum of the foot secondary to neuropraxia of the superficial peroneal nerve. Two patients showed signs of peri-portal superficial infection, that resolved with antibiotics and local care.
- (c) The mean AOFAS score [19] improved from 42 (Range: 34 - 48) preoperatively to 88 (Range: 79 - 92) postoperatively (P value = 0.0001); which is statistically-significant.
- (d) According to Meislen criteria [21], 14 cases were excellent (51.8%), 10 cases (37.1%) were good while three cases (11.1%) were fair, but no poor results.
- (e) According to the scoring of Liu., *et al.* [6], 14 cases (51.85%) were grade 0 (no limitation of athletic activities and return to previous employment), nine cases (33.3%) were grade I (no limitation of athletic activities despite mild pain, with some discomfort at work) and three cases (11.1%) were grade II (moderate limitation of athletic activities or moderate limitation at work), but no case was grade III (inability to return to athletic activities or employment).

Discussion

Soft tissue impingement in the anterolateral gutter of the ankle is common following single or repeated ankle inversion injuries [1-5]. In the literature [6-15,22], the impinging structures included: hypertrophied synovium and scar, meniscoid lesion and hypertrophied accessory band of AITFL (ligament of Bassett). This finding was consistent with our study.

In agreement with other authors [2-4,7-11,23], the present study showed that the diagnosis of ALSTAI is based mainly on history and physical examination. It should be suspected in any case of chronic complaints after an ankle sprain. It can be highly suggested on the basis of the combined presence of anterolateral ankle tenderness, swelling, and pain exacerbated by single leg squatting, ankle eversion, or dorsiflexion and positive impingement test [9]. However, the clinical diagnosis of anterolateral impingement is one of exclusion [15-17]. The differential diagnosis include residual ankle instability, soft tissue or bony impingement, and chondral/osteochondral injuries. These conditions should be ruled out before the diagnosis of anterolateral soft tissue ankle impingement [2,3,13,16].

The principal role of plain radiographs, CT and MRI should be in differential diagnosis and detection of other causes of anterolateral ankle pain as bony impingement, osteochondral lesions and instability. Persistent ankle disability should continue after arthroscopic ankle debridement if these other concomitant pathologies are not detected preoperatively [4,7-11,13,23,24]. The role and accuracy of conventional MRI in diagnosis of ALSTAI is controversial [16-18,23,24]. MR arthrography can be more accurate depending on absence of fluid recess between the anterolateral soft tissues and the anterior surface of the fibula, that may be due to the presence of hypertrophied synovium and scar tissue in that region [16]. Despite advances in diagnostic imaging, diagnostic arthroscopy still remains the gold standard for diagnosis and assessment of ALSTAI [2,3,6-11,13,17,18,25].

The arthroscopic findings in the current study, were consistent with that reported in the literature [6,7,19]. The final outcome of the current study was satisfactory in most cases; with disappearance or improvement of the complaints, improved function and improved ankle scores. This was comparable to the reported literature. The rate of excellent to good results after arthroscopic treatment of ALSTAI varied from 75% to 96.7% in the published literature [1-4,6-11,15-18,25]. After arthroscopic treatment of 41 patients with ALSTAI, Ürgüden., *et al.* [26], reported 21 patients as excellent, 16 as good, 2 as fine, and 2 as weak according to the Meislin criteria [21] and an 89.6 mean score according to the AOFAS criteria. Hassan [17], reported an AOFAS mean score of 34 preoperatively and 89 postoperatively after arthroscopic treatment of 23 patients with ALSTAI. In the series of Devgan., *et al.* [13], the mean VAS score decreased 7.93 preoperatively to 2.57 finally, and the mean AOFAS ankle hind foot scale improved from 50.5 preoperatively to 85.71 finally.

Cases with articular damages beyond the stage of softening and fibrillation were excluded from this study, as the outcome of arthroscopic debridement of ankle impingement with and without cartilage damage is different, because cartilage damage negatively affects the outcome [1], although other authors [14,27] reported no difference in the outcome in both situations. Even with mild changes as shown in the current study the outcome of the 17 cases without any cartilaginous changes showed better results than the remaining ten cases with cartilaginous changes

El-sayed [25] reported 7 cases (35%) of grade I and II chondral lesions. In the current study, seven cases (25.9%) reported also grade I and II chondral lesions.

The routine joint distraction during arthroscopy for ankle impingement is controversial. Dijk van and Schulte [28], proposed that, in patients with soft tissue impingement, distraction leads to tightening of the anterior joint capsule thereby decreasing the anterior working area. When the joint is brought into the forced plantar flexion, however, the anterior compartment opens up, and the pathology can be identified, and treated. So it is possible, and beneficial for the treatment of anterior impingement lesion, to perform the arthroscopic procedure without joint distraction. Others used distraction in various forms. Devgan., *et al.* [13], used ankle distraction strap with hanging weight of about 7 pounds. We used a crepe bandage applied to the foot, for intermittent distraction and plantar flexion of the foot, as proposed by others [17,25].

After failure of conservative treatment, the primary treatment remains debridement, either open or arthroscopic. Good results have been reported with open debridement done previously [29]. Arthroscopic debridement has gained popularity and is considered the gold standard treatment for virtually all causes of impingement syndrome, because it is minimally invasive and associated with low morbidity and faster recovery [4,13,17,18,25].

Limitations of the Study

Limitations of this study include relatively small number of cases and short follow up period are considered defects in this study. Longer follow up period with larger number of cases are needed to be more satisfactory in the future.

Conclusions

Arthroscopic management of anterolateral soft tissue ankle impingement secondary to inversion injuries was indicated if the history and clinical examination are suggestive, after failure of conservative management for at least three months. Arthroscopy proved to be effective for confirming the diagnosis and for treatment. The outcome was satisfactory in most cases, with marked improvement of pain and function. The procedure proved to be safe, with minimal morbidity and few complications.

Bibliography

1. Ferkel RD, et al. "Arthroscopic treatment of anterolateral impingement of the ankle". *American Journal of Sports Medicine* 19.5 (1991): 440-446.
2. Ferran NA and Maffulli N. "Epidemiology of sprains of the lateral ankle ligament complex". *Foot and Ankle Clinics of North America* 11.3 (2006): 659-662.
3. Buda R, et al. "Arthroscopic treatment and prognostic classification of anterior soft tissue impingement of the ankle". *Foot and Ankle International* 37.1 (2016): 33-39.
4. Ross KA, et al. "Arthroscopic treatment of anterior ankle impingement". *Foot and Ankle Surgery* 23.1 (2017): 1-8.
5. Nazarian LN, et al. "Ultrasound-guided percutaneous needle fenestration and corticosteroid injection for anterior and anterolateral ankle impingement". *Foot and Ankle Specialist* 11.1 (2018): 61-66.
6. Liu SH, et al. "Arthroscopic treatment of anterolateral ankle impingement". *Arthroscopy* 5 (1994): 215-218.
7. Devrim Akseki, et al. "The anterior inferior tibiofibular ligament and talar impingement: a cadaveric study". *Knee Surgery, Sports Traumatology, Arthroscopy* 10.5 (2002): 321-326.
8. Vega J, et al. "Minor or occult ankle instability as a cause of anterolateral pain after ankle sprain". *Knee Surgery, Sports Traumatology, Arthroscopy* 24.4 (2016): 1116-1123.
9. Umans HR and Cerezal L. "Anterior ankle impingement syndromes". *Seminars in Musculoskeletal Radiology* 12.2 (2008): 146-153.
10. Sanders TG and Rathur SK. "Impingement syndromes of the ankle". *Magnetic Resonance Imaging Clinics of North America* 16.1 (2008): 29-38.
11. Robinson P. "Impingement syndromes of the ankle". *European Radiology* 17.12 (2007): 3056-3065.
12. Wolin I, et al. "Internal derangement of the talofibular component of the ankle". *Surgery, Gynecology, and Obstetrics* 91.2 (1950): 193-200.
13. Devgan A, et al. "Comparative analysis of arthroscopic debridement in osseous versus soft tissue anterior ankle impingement". *Journal of Clinical Orthopaedics and Trauma* 7.3 (2016): 200-206.
14. Bassett FH, et al. "Talar impingement by the anteroinferior tibiofibular ligament, a cause of chronic pain in the ankle after inversion sprain". *Journal of Bone and Joint Surgery. American Volume* 72.1 (1990): 55-59.
15. Kim SH and Ha KI. "Arthroscopic treatment for impingement of the anterolateral soft tissues of the ankle". *Journal of Bone and Joint Surgery* 82.7 (2000): 1019-1021.
16. Cerezal L, et al. "MR imaging of ankle impingement syndromes". *American Journal of Roentgenology* 181.2 (2003): 551-559.
17. Hassan AH. "Treatment of anterolateral impingements of the ankle joint by arthroscopy". *Knee Surgery, Sports Traumatology, Arthroscopy* 15.9 (2007): 1150-1154.
18. Mardani-Kivi M, et al. "Arthroscopic treatment of patients with anterolateral impingement of the ankle with and without chondral lesions". *The Journal of Foot and Ankle Surgery* 52.2 (2013): 188-191.
19. Madeley NJ, et al. "Responsiveness and validity of the SF-36, Ankle Osteoarthritis Scale, AOFAS Ankle Hindfoot Score, and Foot Function Index in end stage ankle arthritis". *Foot and Ankle International* 33.1 (2012): 57-63.
20. Stephens MM and Kelly PM. "Fourth toe flexion sign: a new clinical sign for identification of the superficial peroneal nerve". *Foot and Ankle International* 21.10 (2000): 860-863.
21. Meislen RJ, et al. "Arthroscopic treatment of synovial impingement of the ankle". *The American Journal of Sports Medicine* 21.2 (1993): 186-189.
22. van den Bekerom MP and Raven EE. "The distal fascicle of the anterior inferior tibiofibular ligament as a cause of tibiotalar impingement syndrome: a current concepts review". *Knee Surgery, Sports Traumatology, Arthroscopy* 15.4 (2007): 465-471.
23. Liu SH, et al. "Diagnosis of anterolateral ankle impingement. Comparison between magnetic resonance imaging and clinical examination". *American Journal of Sports Medicine* 25.3 (1997): 389-393.
24. Rubin DA, et al. "Anterolateral soft-tissue impingement in the ankle: diagnosis using MR imaging". *American Journal of Roentgenology* 169.3 (1997): 829-835.
25. El-Sayed AMM. "Arthroscopic treatment of anterolateral impingement of the ankle". *The Journal of Foot and Ankle Surgery* 49.3 (2010): 219-223.
26. Ürgüden M, et al. "Arthroscopic treatment of anterolateral soft tissue impingement of the ankle: Evaluation of factors affecting outcome". *Arthroscopy* 21.3 (2005): 317-322.
27. Deberardino TM, et al. "Arthroscopic treatment of soft tissue impingement of the ankle in athletes". *Arthroscopy* 13.4 (1997): 492-498.
28. Dijk van CN and Schulte D. "Arthroscopy of the ankle joint". *Arthroscopy* 13.1 (1997): 90-96.
29. Cutsuries AM, et al. "Arthroscopic arthroplasty of the ankle joint". *Clinics in Podiatric Medicine and Surgery* 11.3 (1994): 449-467.

Volume 1 Issue 1 October 2018

© All rights are reserved by Mohamed Othman, et al.