

Bilateral Bumpy Iris: A Case Report on Lisch Nodules

Aakash Chowdhary*

Junior Resident, Department of Ophthalmology, Rama Medical College Hospital and Research Centre, Hapur, India

***Corresponding Author:** Aakash Chowdhary, Junior Resident, Department of Ophthalmology, Rama Medical College Hospital and Research Centre, Hapur, India.

Received: June 19, 2023

Published: August 04, 2023

© All rights are reserved by **Aakash Chowdhary.**

Abstract

A 25-year-old woman was referred by dermatology, who had suspected neurofibromatosis type 1 (NF1), to rule out the presence of Lisch nodules. The patient's neuro-ophthalmic examination was otherwise normal, but her irides revealed bilateral Lisch nodules, with a diffuse distribution over anterior surface of the irides.

Keywords: Iris Nodules, Lisch Nodules, Neurofibromatosis, NF

Abbreviation

NF1: Neurofibromatosis Type-1

Introduction

Lisch nodules are hamartomas of the iris and are virtually pathognomonic for neurofibromatosis type 1 (NF1). They appear as dome-shaped elevations on the iris stroma, are yellow to brown in color, present in a variable number in both eyes, and their detection raise suspicion for the presence of NF1, especially if multiple café-au-lait macules are present [1].

Materials and Methods

Anterior-segment examination was done by a slit-lamp (SLx45; Labomed Inc.) and photograph captured via smartphone camera (iPhone SE 2nd generation; Apple Inc.).

Results and Discussion

A 25-year-old woman was referred by dermatology, who had suspected neurofibromatosis type 1 (NF1), to rule out the presence of Lisch nodules.

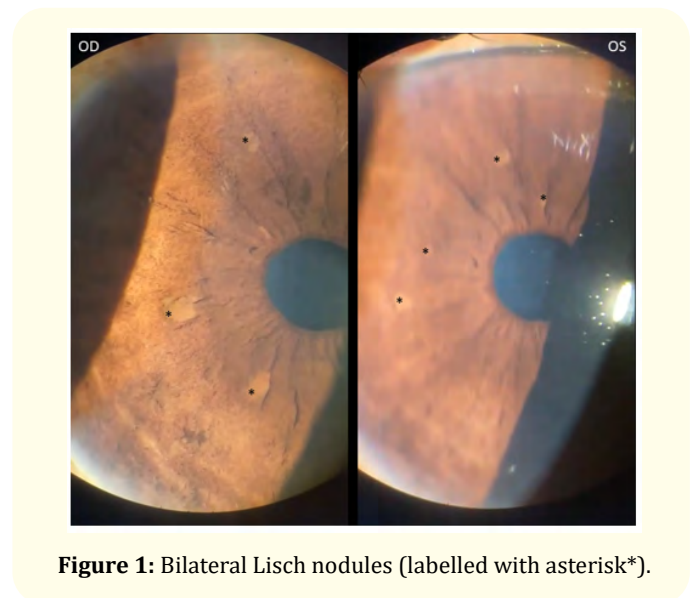


Figure 1: Bilateral Lisch nodules (labelled with asterisk*).

The patient's neuro-ophthalmic examination was otherwise normal, but her irides revealed bilateral Lisch nodules, with a diffuse distribution over anterior surface of the irides (Figure 1).

Conclusion

Abnormal lesions on anterior surface of the irides may be a sign of systemic illness, and should be examined by an ophthalmologist routinely as part of out-patient examination, or as part of referral examination.

Practitioners and specialists outside ophthalmology should also be on careful lookout and seek expert advise as and when deemed possible.

Acknowledgments

This brief study would not have been possible without unwavering support and guidance from respected Prof. Dr. Anshu Sharma, Head, Deptt. of Ophthalmology; Asstt. Prof. Dr. Priyanka Dubey, and Asstt. Prof. Dr. Marisha Bishnoi, Deptt. of Ophthalmology.

Conflict of Interest

Nil financial interest or any conflict of interest exists.

Bibliography

1. American Academy of Ophthalmology. Basic and Clinical Science Course, Section 11: Lens and Cataract. San Francisco: American Academy of Ophthalmology (2019).