



Subhyaloid Haemorrhage: A Case Report

Santosh Subedi and Sujan Rijal*

Rapti Eye Hospital, Province Lumbini, Nepal

***Corresponding Author:** Sujan Rijal, Rapti Eye Hospital, Province Lumbini, Nepal.

DOI: 10.31080/ASOP.2022.05.0553

Received: July 11, 2022

Published: July 19, 2022

© All rights are reserved by **Santosh Subedi and Sujan Rijal.**

Abstract

Introduction: Intraocular collection of blood, usually between posterior limiting layer of the vitreous and retina is subhyaloid haemorrhage.

Case Presentation: Unilateral subhyaloid haemorrhage with history of trauma in 30 years male is the case that we present. Laboratory tests was done and it is within the normal.

Conclusion: Our case decorate an fascinating presentation of unilateral subhyaloid haemorrhage, where history of trauma was the risk factor.

Keywords: Trauma; Subhyaloid Haemorrhage; Rapti Eye Hospital

Introduction

Subhyaloid haemorrhage is the collection of blood between posterior limiting layer of vitreous and retina which can lead to moderate to severe vision loss when macula involved. Trauma, proliferative diabetic retinopathy, Age-related macular degeneration, macroaneurysm, valsalva retinopathy are some related causes of subhyaloid haemorrhage.

Subhyaloid haemorrhage is rare. The first case was reported by Liebreich in 1863, and other have been recorded, although infrequently.

Lots of technique have been created to treat subhyaloid haemorrhage. Just observation is also a conventional treatment. Depending upon the thickness and total amount of blood present, conventional treatment would be the risk factor of macular complication and it also take several weeks or months for resolve. Over and above that, development of significant epiretinal tissue proliferation and pigmentary macular changes can lead to the permanent vision loss. Cellular proliferation and fibrous tissue

formation occurs due to heavy bounce haemorrhage between the internal limiting membrane and the posterior surface of the hyaloid membrane so that is unable to flow in subhyaloid area. Pneumatic Displacement is a simple procedure that aims to shift blood from under the macular to other parts of the retina that are less vital for vision.

Tissue plasminogen activator (tPA) is a thrombolytic agent that break down blood clots to restore blood flow to the ischemic region.

With or without use of Tissue Plasminogen activator, Pars Plana Vitrectomy and pneumatic displacement procedure has been used as options. Pneumatic displacement with the use of tPA injection includes some complications, retinal detachment, retinal toxicity, haemorrhage re-occurred. For the management of macular subhyaloid haemorrhage, Nd:YAG laser has been used for internal drainage. It can generate an space in the surface of hyaloid membrane implement expeditious drainage of the haemorrhage from the subhyaloid area into the vitreous gel, from where it is adherence. Although the procedure is safe it has possible

complication including vitreous haemorrhage, failed drainage, metamorphosis, macular hole, and retinal break causing retinal detachment.

Here in, we report a case of traumatic subhyaloid haemorrhage that was successfully treated with pars plana vitrectomy with Internal Limiting Membrane Peeling done with endolaser including Fluid Air Exchange, that showed rapid recovery.

Case Presentation

A 30 years Male presented to the Rapti Eye Hospital with acute vision loss secondary to trauma hit by a stone six months back to his Right eye. He came to the clinic when he feel vision get worst. Visual acuity (VA) was 6/6 in left eye and counting finger in right eye. Normal Anterior segment examination. The posterior segment examination divulge a subhyaloid macular haemorrhage in his right eye, so the vision get loss. No any chronic disease was mentioned of the patient.

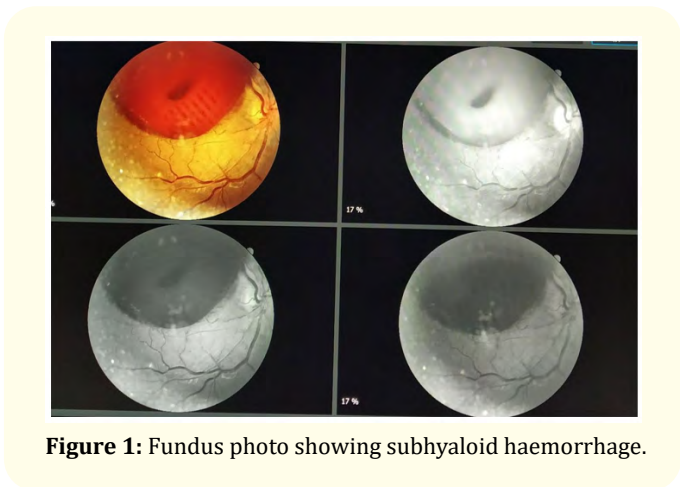


Figure 1: Fundus photo showing subhyaloid haemorrhage.

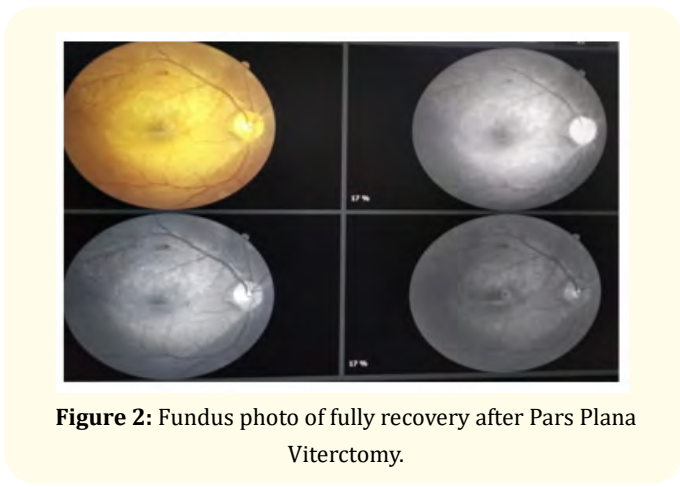


Figure 2: Fundus photo of fully recovery after Pars Plana Viterctomy.

Ensuing obstacle were enlightened for the patient from retina specialist (Primarily retinal detachment and cataract formation).

With the first follow up after 3 days visual acuity was improved upto 6/18. After 6 days follow up visual acuity was 6/9 with normal IOP.

Discussion

Subhyaloid macular haemorrhage fabricate unexpected extreme loss of vision that may be perpetual if left unstained. Subhyaloid haemorrhage is the direct cause of damage to retina and epiretinal membrane, which can lead to vision loss. There are several important criteria.

Firstly patient was advice for close observation. PRP (Pan Retinal Photocoagulation) laser was done after 11 days. Injection Avastin was recommend. Injection Avastin was given after 2 days of PRP laser. Then after 4 days of injection Avastin, Pars Plana vitrectomy was done. It is relatively safe and helps in quick visual recovery [1-10].

Conclusion

The foremost of our comprehension, there have been no delineate case of subhyaloid macular haemorrhage treated at Rapti Eye Hospital in which cause was trauma and the patient showed fully recuperation, retrieve 6/9 visual acuity with no outcome. For the subhyaloid haemorrhage there are different options for the treatment, Pars Plana Vitrectomy, hyaloidotomy with Nd:YAG laser or observation alone are all accepted. As the disease is disruptive, collation is difficult. Pars plana vitrectomy is considered as an option, in the presence of an experienced ophthalmologist for full recuperation with no outcome damage of eye for the treatment of subhyaloid haemorrhage.

Acknowledgement

We would like to acknowledge Dr. Santosh subedi, The Medical Superintendent of our hospital for his general support.

Bibliography

1. J Hillenkamp., et al. "Management of submacular hemorrhage with intravitreal versus subretinal injection of recombinant tissue plasminogen activator". *Graefe's Archive for Clinical and Experimental Ophthalmology* 248.1 (2009): 5-11.
2. V Gabel., et al. "Nd:YAG laser photodisruption of hemorrhagic detachment of the internal limiting membrane". *American Journal of Ophthalmology* 107.1 (1989): 33-37.

3. GP O'Hanley and CLB Canny. "Diabetic dense premacular hemorrhage: a possible indication for prompt vitrectomy". *Ophthalmology* 92 (1985): 507-511.
4. PN Schultz, *et al.* "Long-term visual outcome in Terson syndrome". *Ophthalmology* 98 (1991): 1814-1819.
5. SS Sandhu, *et al.* "Displacement of submacular hemorrhage associated with age-related macular degeneration using vitrectomy and submacular tPA injection followed by intravitreal ranibizumab". *Clinical Ophthalmology* 4 (2010): 637-642.
6. F Treumer, *et al.* "Subretinal coapplication of recombinant tissue plasminogen activator and bevacizumab for neovascular age-related macular degeneration with submacular haemorrhage". *British Journal of Ophthalmology* 94.1 (2009): 48-53.
7. D Khadka, *et al.* "Nd:YAG laser hyaloidotomy in the management of premacular subhyaloid hemorrhage". *BMC Ophthalmology* 16.1 (2016).
8. F Qureshi. "Management of macular pre-retinal subhyaloid hemorrhage by Nd:Yag laser hyaloidotomy". *Pakistan Journal of Medical Sciences* 30.2 (2014).
9. M Ulbig. "Long-term results after drainage of premacular subhyaloid hemorrhage into the vitreous with a pulsed Nd:YAG laser". *Archives of Ophthalmol-Chic* 116.11 (1998): 1465.
10. Kuruvilla, *et al.* "Nd:YAG membranotomy for preretinal hemorrhage secondary to valsalva retinopathy". *Saudi Journal of Ophthalmology* 28 (2014): 145-151.