



The First Results of the Complex Laser Surgery Technology Application for Primary Open-angle Glaucoma

Balalin AS^{1*}, Fokin VP¹, Balalin SV^{1,2} and Dzhashi BG¹

¹Eye Microsurgery Named After Academician S.N. Fedorov, Volgograd Branch, Volgograd, Russia

²Volgograd State Medical University, Volgograd, Russia

*Corresponding Author: Balalin AS, Eye Microsurgery Named After Academician S.N. Fedorov, Volgograd Branch, Volgograd, Russia.

DOI: 10.31080/ASOP.2022.05.0529

Received: May 26, 2022

Published: June 03, 2022

© All rights are reserved by Balalin AS, et al.

Abstract

Examination and treatment of 50 patients (50 eyes) with the early stage of primary open angle glaucoma before and after application of complex laser surgery technology was carried out. Selective laser trabeculoplasty in combination with YAG-laser trabeculostomy was performed in the projection of the outflow meshwork. Hypotensive effect was 31.1% of the initial intraocular pressure level on the 1st post-op day and remained for a month after the surgery due to the outflow improvement of the intraocular fluid by 62.5%. The YAG-laser and OCT data allow optimization of YAG trabeculostomy, providing an alternative noninvasive laser treatment for patients with primary open angle glaucoma.

Keywords: Primary Open Angle Glaucoma; Selective Laser Trabeculoplasty; YAG Laser Trabeculostomy

Glaucoma remains one of the main causes of blindness and low vision and is currently one of the most relevant problems of ophthalmology.

Glaucoma takes the first place among the causes of blindness and low vision in Russia. In the nosological structure of disability, the percentage of glaucoma has increased from 20 to 28% [1].

Normalization of ophthalmotonus in glaucoma is the primary and fundamental purpose. The effectiveness of glaucoma treatment is evaluated according to the following criteria: normalization of ophthalmotonus - by achieving individual IOP, stabilization of visual functions - by perimetry, nonprogression of glaucoma optical neuropathy according to ophthalmoscopy, optical coherence tomography of optic nerve disc and retina [1].

Despite the availability of new medications in drug therapy of glaucoma, laser and surgical therapies still play the leading role.

One of the main directions of treatment of early stages of primary open-angle glaucoma is laser surgery techniques aimed at reducing elevated intraocular pressure (IOP) by improving aqueous outflow through natural pathways - through the trabecular meshwork of the Schlemm's canal. M.M. Krasnov and co-authors (1972) were one of the first developers of laser operations on the trabecula. They suggested performing goniotomy with a short laser pulse with 20-25 laser pulses per session of 0.05-0.25 J [2]. Hypotensive effect of this technology reached 12 mm Hg, IOP normalization was observed in 90% of cases, compensation of ophthalmotonus was observed within 5 years. Disadvantages of the technology: application of excessive laser energy led to trabecula damage and its subsequent scarring, detection of hemorrhages in the trabecula and hyphema area in the early postoperative period.

In 1979, J. Wise, S. Witter developed the technique of argon laser trabeculoplasty (ALT). This surgery showed high efficacy in multicenter studies of POAG patients, that were observed under

hypotensive therapy and under combining hypotensive therapy with ALT. The ALT group showed a higher reduction in IOP compared with isolated hypotensive therapy, including eyes with pseudoexfoliative glaucoma (PEG). By performing this technique, 100 applications are made all around the Schlemm's canal. The applied spot diameter was 50 μm , the power was 400-1200 mW, and the exposure - 0.1s. The hypotensive effect of this technique is based on active damage to the trabecular meshwork with a change in its tension (plastics), where burn scar tissue changes tighten the trabecular meshwork and increase its permeability for aqueous humor [3].

However, histological studies have shown that ALT leads to coagulative destruction of the trabecular meshwork of the Schlemm's canal. At the same time, a fibrovascular membrane may form between the coagulates, resulting in decreased outflow of intraocular fluid and increased ophthalmotonus. Therefore, repeated ALT is not recommended due to the volume of the intervention and changes in the trabecular meshwork, according to the studies of several authors [4-6].

In 1995, M.A. Latina, *et al.* proposed a method of selective laser trabeculoplasty (selective photothermolysis) using a Nd:YAG laser (on ilium-yttrium garnet) with a wavelength of 532 nm. A targeted beam with a spot diameter of 400 microns is focused on the pigmented trabecula. One treatment session applied on the lower sector of the trabecular circumference - 180°. There are 90-100 contacting but not overlapping spots. The method selects a subthreshold maximum energy during the procedure, which does not cause cavitation bubbles. The average energy value of the procedure is 0.5 mJ. According to cellular theory, the release of inflammatory mediators followed by SLT results in the migration of macrophages which phagocytize pigment, cell exchange products, and exfoliative deposits, clearing the trabecular meshwork zone of debris and increasing its capacity to aqueous humor. This technique also induces the expression and secretion of IL-1beta (interleukin 1) and TNF-alpha (tumor necrosis factor alpha) during the first 8 hours after SLT. Cytokines initiate remodelling of the juxtacanalicular extracellular matrix, which leads to improved outflow of intraocular fluid [7,8].

Further development of the technique led to the appearance of different variants of its performing. E.S. Ivanova, N.R. Tumanyan,

T.S. Lyubimova, E.A. Subkhangulova (2012) suggested selective laser activation of trabecula (SLAT) for maximal clearing of trabecular meshwork and improvement of intraocular fluid outflow. The optimal SLAT parameters are the size of the operating zone in the range of 90-120° (on average, 100°) and the number of applied pulses in the range of 80-100. According to the authors, in comparison with SLT, SLAT provides maximum clearing of the trabecular meshwork of the anterior angle chamber, due to a greater amount of pigment «knocked out» during the operation, 1.5-2 times more evident and prolonged hypotensive effect and 2.6 times less postoperative inflammatory reactions [9].

In suprathreshold SLT, the minimum energy is selected to cause the formation of microcavitation bubbles and the defragmentation of large pigment granules, knocking the pigment out of the trabecular network. The initial energy level for this SLT modification is 0.3 mJ according to the authors, then it is increased by 0.1 mJ to the threshold effect - the appearance of microcavitation bubbles («champagne splashes»). Then increase the energy by 0.1 mJ up to the minimum value at which the effect of «knocking out» of pigment from trabecular membrane, defragmentation of large granules of pigment is noted. The energy value of suprathreshold SLT is only 0.1-0.2 mJ higher than the established threshold. In addition to photothermolysis, this method promotes the release of pigment granules from the trabecular network [10].

Laser activation of the trabecula (LAT) suggests application of 50-60 applications to the trabecular area in the projection of the Schlemm's canal in a circle 180° Nd-YAG laser with a wavelength of 1064 nm, spot diameter of 8-10 μm , power 0.8-1.1 mJ and exposure of 3 ns. In this case a shock wave is performed above the trabecular surface, which drives anterior chamber humor and various deposits on the trabecular surface, carrying out «flushing» of trabecular slits under pressure. According to the authors, the hypotensive effect after LAT is less stable than after SLT. With this technique, laser treatment reaches its goal regardless of the degree of trabecular pigmentation [11].

Purpose

To develop and evaluate the effectiveness of a complex optimized laser surgery technology for primary open angle glaucoma.

To achieve this goal, it was necessary to use the advantages of SLT: photothermolysis of pigment granules across the entire width of the trabecula by using a 400 μm laser spot; second, to use a Nd-YAG laser with a 3 ns short pulse and a 10 μm spot diameter to perform YAG-laser trabeculostomy, which allows postoperative IOP to significantly reduce elevated levels by improving aqueous humor outflow through the holes created in the trabecula.

Materials and Methods

50 patients (50 eyes) with the initial stage of primary open angle glaucoma were examined. Mean age: 68.9 ± 1.38 years (41 to 92 years). There were 24 men and 26 women. The distribution according to the tonometric IOP level was: with normal values of ophthalmotonus (up to 25 mm Hg) - 8 patients, 8 eyes (12.2%), with moderately elevated values (from 26 to 32 mm Hg) - 35 patients, 35 eyes (53.9%) and with high level of ophthalmotonus (above 32 mm Hg) - 22 patients, 22 eyes (33.9%).

Criteria for selection of patients: initial stage of primary open-angle glaucoma, open angle of the anterior chamber; I-IV pigmentation degree; reduction of elevated ophthalmotonus to values of the average norm, but exceeding the value of individually tolerated pressure using hypotensive drug therapy (prostaglandins F-2a, b-adrenoblockers and/or carboangiradase inhibitors).

Exclusion criteria: elevated IOP using combined drug therapy; closed angle of the anterior chamber; advanced and far advanced glaucoma, secondary glaucoma.

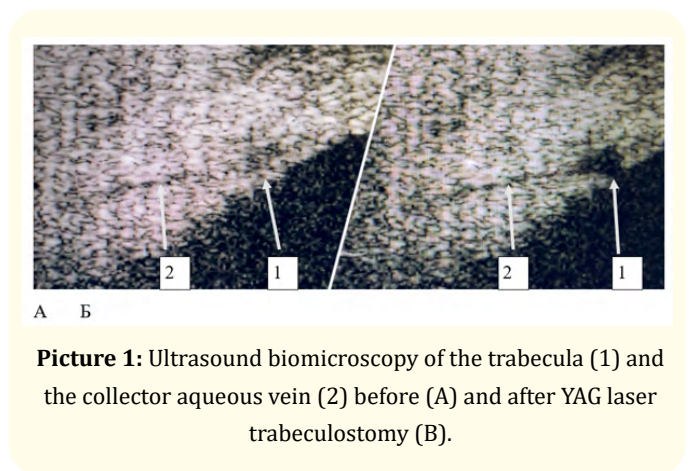
YAG-trabeculostomy was performed taking into account OCT data of the anterior eye segment in the projection of aqueous veins location. Laser exposure parameters: pulse duration - 3 ns, spot diameter - 10 μm, pulse energy - 1.5-2.0 mJ with formation of up to 10 trabeculostomas. OCT of the anterior segment was performed using a Triton (Topcon, Japan) diagnostic device.

Selective laser trabeculoplasty according to M.A. Latina technique and YAG laser trabeculostomy were performed using Selecta II (Lumenis, USA).

The values of tonometry and tonography received as a result were processed by the method of variation statistics using the Numbers 12.0 (Apple Inc.). To assess the significance of differences between the mean values (M ± σ), the Student’s t-test was calculated. If its value was 2.0 or higher and p<0.05, the difference was interpreted clinically significant.

Results

Picture 1 shows the state of the trabecula and aqueous vein before and after YAG laser trabeculostomy.



Picture 1: Ultrasound biomicroscopy of the trabecula (1) and the collector aqueous vein (2) before (A) and after YAG laser trabeculostomy (B).

Hypotensive effect and improvement of ocular hydrodynamic indices after application of a complex technology of laser surgery for primary open-angle glaucoma are presented in table 1. According to static perimetry, the mean values of MD and PSD were -1,52 ± 1,78 dB and 1,8 ± 0,31dB, respectively, corresponding to the initial stage of glaucoma.

Parameters	Pre-op	Post-op (1 day)	Post-op (1 month)
BCVA	0,68 ± 0,26	0,69 ± 0,25	0,69 ± 0,25
Tonography			
P ₀ , mm Hg	17,74 ± 3,52*	12,2 ± 3,75**	12,48 ± 3,2**
C, mm ³ /mm Hg × min	0,16 ± 0,091*	0,26 ± 0,09**	0,25 ± 0,09**
F, mm ³ /min	1,2 ± 1,13	0,7 ± 0,77	0,8 ± 0,8
P ₀ /C	170,9 ± 171,9*	54,1 ± 30,1**	56,3 ± 29,8**

Table 1: Clinical and functional parameters in patients with primary open-angle glaucoma before and after combined laser surgery (SLT + trabeculostomy), 50 eyes, M ± σ.

Differences between the mean values marked by * and ** are statistically significant (p < 0.05).

Hypotensive effect after using the combined technology of laser glaucoma surgery was noticed within 1 day post-op, was 31.1% of the initial level of ophthalmotonus on medical treatment and persisted for 1 month after surgery. The decrease of the ophthalmotonus was due to a significant improvement in the outflow of aqueous humor. The outflow coefficient increased by 62.5% on the first day post-op and by 56.3% after 1 month.

According to Latina M. A. (1998) the hypotensive effect of SLT during 26 weeks of observation was 23.6% [8]. The use of complex technology allows achieving a more pronounced hypotensive effect, which was registered within 1 day after the procedure (31.1%) and remained at the same level for 1 month after surgery - 30%.

Conclusion

The YAG laser and OCT data optimize SLT and trabeculostomy technology, providing an alternative noninvasive combined laser treatment for patients with initial stage primary open angle glaucoma. Further studies are planned for long-term follow-up.

Conflict of Interest

There is no conflict of interest.

Bibliography

1. "Natsional'noye rukovodstvo po glaukome: dlya praktikuyushchikh vrachey [National guidelines for glaucoma: for practitioners]" pod red. Ye.A. Yegorova, V.P. Yericheva. [ed. E.A. Egorova, V.P. Ericheva] (2019): 384.
2. Krasnov MM., et al. "Lazernoye lecheniye pervichnoy glaukomy [Laser treatment of primary glaucoma] Vestnik oftal'mologii". *Bulletin of Ophthalmology* 5 (1982): 18-22.
3. Wise JB and Witter SL. "Argon laser therapy for open-angle glaucoma: a pilot study". *Archives of Ophthalmology and Glaucoma* 97 (1979): 319-322.
4. Rodrigues MM., et al. "Electron microscopy of argon laser therapy in phakic open-angle glaucoma". *Ophthalmology* 89 (1982): 198-210.
5. Ticho U and Zauberman H. "Argon laser application to the angle structures in the glaucomas". *Archives of Ophthalmology* 94.1 (1976): 61-64.
6. Bradley JM., et al. "Mediation of laser trabeculoplasty-induced matrix metalloproteinase expression by IL-1beta and TNF-alpha". *Investigative Ophthalmology and Visual Science* 41.2 (2000): 422-430.
7. Latina MA and Park CH. "Selective targeting of trabecular meshwork cells: in vitro studies at pulsed and CW laser interactions". *Experimental Eye Research* 60 (1995): 359-371.
8. Latina MA., et al. "Q-switched 532-nm Nd-YAG selective laser trabeculoplasty (selective laser trabeculoplasty)". *Ophthalmology* 105.11 (1998): 2082-2090.
9. Ivanova ES., et al. "Selektivnaya lazernaya aktivatsiya trabekuly v lechenii patsiyentov s pervichnoy otkrytougol'noy glaukomoy [Selective laser activation of the trabecula in the treatment of patients with primary open-angle glaucoma]". Vestnik Orenburgskogo gosudarstvennogo universiteta. [Vestnik Orenburg State University] 12.148 (2012): 65-68.
10. Balalin SV and Fokin VP. "Nadporogovaya SLT v lechenii bol'nykh otkrytougol'noy glaukomoy na fone psevdooksfoliativnogo sindroma [Suprathreshold SLT in the treatment of patients with open-angle glaucoma associated with pseudoexfoliative syndrome]". Vestnik Tambovskogo gosudarstvennogo universiteta [Tambov University Review] 19.4 (2014): 1083-1085.
11. Sokolovskaya TV., et al. "YAG-lazernaya aktivatsiya trabekuly v lechenii bol'nykh pervichnoy otkrytougol'noy glaukomoy [YAG-laser activation of the trabecula in the treatment of patients with primary open-angle glaucoma]". *Oftal'mokhirurgiya [Ophthalmosurgery]* 1 (2014): 47.