



A Comparative Study of Conjunctival Autografting after Pterygium Excision with Autologous Blood Coagulum and Sutures

Aswathy Vijayan*, Vijayalakshmi MS, Leila Mohan and M Nivean

Department of Ophthalmology, MN Eye Hospital, Chennai, India

*Corresponding Author: Aswathy Vijayan, Department of Ophthalmology, MN Eye Hospital, Chennai, India.

DOI: 10.31080/ASOP.2022.05.0505

Received: April 04, 2022

Published: April 29, 2022

© All rights are reserved by Aswathy Vijayan, et al.

Abstract

Purpose: To compare autologous blood coagulum versus sutures for attaching limbal conjunctival autografts in patients undergoing primary pterygium excision. To compare graft stability, postoperative pain and discomfort, and recurrence rate in the two groups.

Methods: Prospective cohort study of patients undergoing surgery for pterygium from Comtrust Eye Hospital, Calicut, Kerala during for 1 year,6 months, where sutures or autologous blood coagulum was used for graft adhesion.154 patients who underwent pterygium excision with limbal conjunctival autografting were selected into 2 groups.

Group A: Autografts attached by sutures (77 cases).

Group B: Autografts attached by autologous blood coagulum (77 cases).

Results: 1 case (1.3%) showed graft displacement in group A. In group B, 6 cases (7.8%) showed graft displacement and 2 cases (2.6%) showed graft loss. Thus a total of 8 cases (10.6%) showed graft instability. At the end of 6 months post operatively, recurrence was found to be equal 4 cases (5.2%) in both the groups. Post operative pain at the end of 1st week was found in 21 cases (27.3%) in the group A as compared to 4 cases (5.2%) in the group B. Foreign body sensation was present at the end of 1 week in 29 cases (37.7%) in the group A compared to 2 cases (2.6%) in the group B.

Conclusion: The postoperative discomfort was high in group A but subsided in 4 weeks. Graft stability is higher in the suture group. Both groups had equal number of recurrences.

Keywords: Conjunctiva; Autograft; Autologous Blood Coagulum; Suture; Pterygium

Introduction

Pterygium is a benign growth that develops in conjunctiva with a prevalence rate of 0.7% to 31% around the world [1-4]. It occurs commonly where ultraviolet light intensity is highest [5]. Other causative factors are dust, smoke and wind. A pterygium usually does not require any treatment unless it is blocking the vision, causing severe discomfort, restricted ocular motility or cosmetic deformity. There are numerous techniques for surgical treatment

of pterygium. Pterygium excision with conjunctival autografting remains the gold standard for reducing recurrence since its initial description by Kenyon, et al. in 1985 [6]. One of the most common methods of surgical management with least recurrence rate (5%) is pterygium excision with limbal conjunctival autograft [7]. The conjunctival autograft can be attached by suturing, fibrin glue or autologous blood coagulum.

Fixing the autograft with sutures has the disadvantage of postoperative foreign body sensation, pain and watering. Plasma

derived products like fibrin glue can overcome this problem; but it is expensive, less available and has associated risk of viral transmission. So it was this very significant consideration which prompted to look for an ideal alternative, which will ensure greater degree of safety, efficacy as well as entail minimum complications. The suture-free glue-free method is attaching the autologous graft using autologous blood coagulum. Autologous blood coagulum is natural and has no extra cost or associated risk. It can also overcome post operative irritation to a great extent.

Pterygium is a very common condition especially in our locality which lies in the coastal area of Kerala. Using patient's own blood coagulum as bioadhesive for the conjunctival graft is a cost effective option especially in a developing country like India. Moreover, there have been only a few studies which compared the outcome of autologous blood coagulum and sutures.

Thus a prospective study conducted to compare the outcome of conjunctival autografting using autologous blood coagulum and sutures becomes relevant.

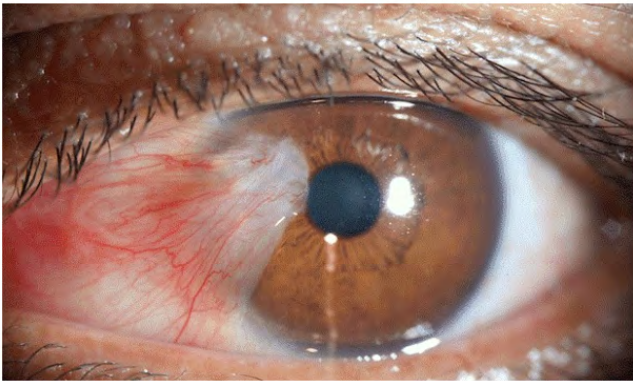


Figure 1: Nasal pterygium.

Objectives

- To compare graft stability in the two groups.
- To compare postoperative pain and discomfort in the two groups.
- To compare recurrence rate in the two groups.

Materials and Methods

It was a prospective cohort study done in Comtrust Eye Hospital, Calicut, Kerala which is a tertiary eye hospital for 1 year and 6

months. Patients who underwent pterygium excision with limbal conjunctival autografting were selected into 2 groups.

- Group A: Autografts attached by sutures.
- Group B: Autografts attached by autologous blood coagulum. Inclusion criteria's were, 1) Patients undergoing pterygium surgery with limbal conjunctival autografting using sutures. 2) Patients undergoing pterygium surgery with limbal conjunctival autografting using autologous blood coagulum. Exclusion criteria's were 1) Recurrent pterygium. 2) Pseudopterygium. 3) Those patients with pterygium who were not willing to take part in the study.

A detailed history was taken from each patient with special reference to age, occupation, residence, exposure to dust and hot wind. After informed consent, patients fulfilling the inclusion criteria were taken for the study.

Preoperative investigations were best corrected visual acuity was determined using Snellens chart, near vision assessment, slit lamp examination, intraocular pressure measurement and fundus examination were performed as part of routine ophthalmologic evaluation.

The surgeries were performed by various surgeons in our hospital. After subtenons block, the apex of the pterygium was scraped off from the cornea and the whole pterygium excised. After taking measurements, a conjunctival autograft slightly larger than the defect was taken from the superior limbus of same eye and placed on the raw area. The graft was held in place maintaining proper orientation, using sutures or autologous blood coagulum.

The graft position should not be disturbed for a minimum period of 5-7 minutes in the autologous blood coagulum group. The sutures used for securing graft was 6-0 vicryl. Simple interrupted suturing was done. Patients were given antibiotic eye drops 4 times a day for 2 weeks. Steroid eye drops were given 4 times a day for 2 weeks, then 3 times a day for 2 weeks and then 2 times a day for 2 weeks. Antibiotic eye ointment was prescribed for night application for 4 weeks.

Patients were followed up at 1 week, 1 month, 3 months, 6 months interval post operatively. Best corrected visual acuity was noted at every visit.

Post operatively the following parameters were analysed

- **Pain:** Pain was assessed using Visual Analogue Scale with a score ranging from 0 to 10. In this study any score of 3 or more was taken as presence of pain.
- Foreign body sensation
- Watering
- Subconjunctival haemorrhage
- **Recurrence:** In this study, recurrence was defined as any fibrovascular growth extending across the limbus onto cornea at the site of surgical excision.
- **Graft instability:** In this study, graft instability means either graft displacement/graft loss.
- **Graft displacement:** In this study, it was defined as any edge of the graft having moved away from the graft-bed.
- **Graft loss:** In this study, it was defined as graft completely displaced from its graft bed. In this study, graft is stable when all sides of the graft margin are well apposed.
- **Other complications:** Cystic swelling, dellen, graft edema, granuloma.

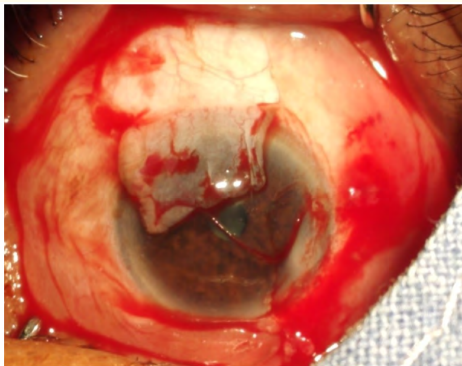


Figure 2: Conjunctival graft fashioning from superior limbus.

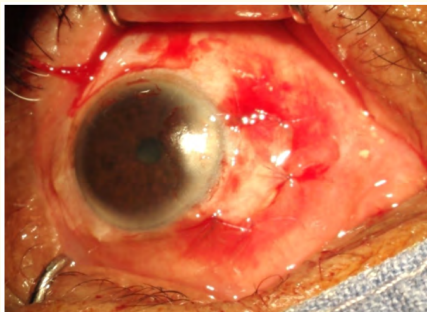


Figure 3: Conjunctival autograft sutured after excision of pterygium.

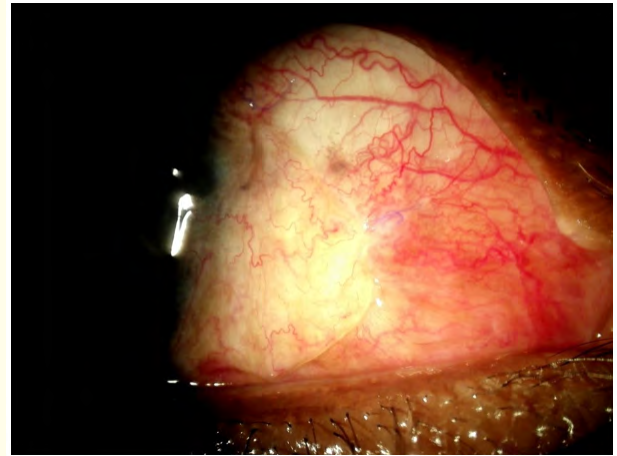


Figure 4: Post operative day 7.

Statistical analysis

The data obtained was analysed using appropriate statistical methods. Qualitative variables were presented as frequency and percentage. Comparison between the groups was done using the Chi square test. A p value of ≤ 0.05 was considered statistically significant. Data was analysed using the software SPSS version 16.

Results

Patients were divided into different age groups, of which majority were in 36-50 years of age, 68 cases (44.16%), followed by above 51 years of age group 54 cases (35.06%) and 32 cases (20.78%) in 20-35 years. Out of 154 samples, 117 cases (76%) were males and 37 cases (24%) were females, which showed a male preponderance for pterygium in this study. Pterygium were found more common in those with outdoor occupation like fisherman, manual labourer, farmers 85 cases (55.19%) as compared to those with indoor occupation like teachers, office staffs 69 cases (44.81%). Pterygium was found more frequently in the right eye 98 cases (63.6%) as compared to 56 cases (36.4%) in the left eye. Nasal pterygium was seen more commonly, 145 cases (94.2%) as compared to temporal pterygium, 9 cases (5.8%). Post operative pain at the end of 1st week was found in 21 cases (27.3%) in the suture group as compared to 4 cases (5.2%) in the autologous blood coagulum group as shown in the figure below.

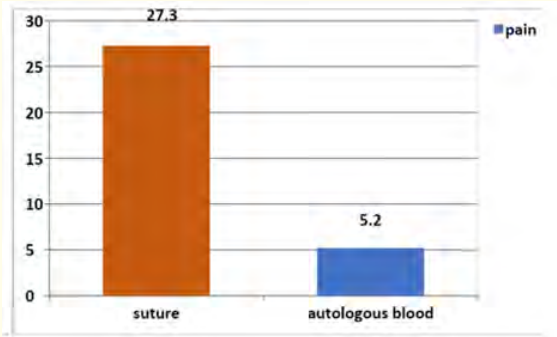


Figure 5: Comparison of pain at the end of 1 week based on surgery.

Chi-Square tests			
	χ^2	df	p value
Pearson Chi-Square tests	13.800	1	0.00
p value = 0 (<0.05), which is statistically significant.			

Table 1

Foreign body sensation was present at the end of 1 week in 29 cases (37.7%) in the suture group compared to 2 cases (2.6%) in the autologous blood coagulum group as shown in the figure below.

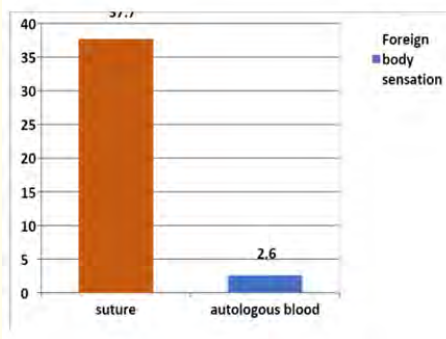


Figure 6: Comparison of foreign body sensation at the end of 1 week based on surgery.

Chi-Square tests			
	χ^2	df	p value
Pearson Chi-Square tests	29.443	1	0.00
p value = 0 (<0.05), which is statistically significant.			

Table 2

Out of 77 samples in the autologous blood coagulum group, 6 cases (7.8%) showed graft displacement and 2 cases (2.6%) showed graft loss. Thus a total of 8 cases (10.6%) showed graft instability.

Out of 77 samples in suture group, only 1 case (1.3%) showed graft displacement and none had graft loss.

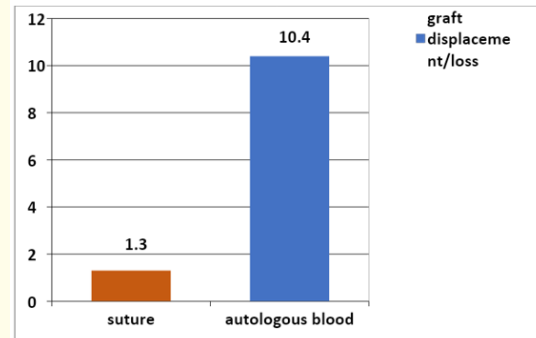


Figure 7: Comparison of graft instability (displacement/loss) based on surgery.

Chi-Square tests			
	χ^2	df	p value
Pearson Chi-Square tests	5.782	1	0.016
p value = 0.016 (< 0.05), which is statistically significant.			

Table 3

	Graft displacement		Graft loss	
	Count	Percent	Count	Percent
Autologous blood	6	7.8	2	2.6
Suture	1	1.3	0	0

Table 4: Comparison of graft instability based on surgery.

In the autologous blood group, other complications seen were cystic swelling in 1 case (1.3%), graft edema in 2 cases (2.6%).

In the suture group, dellen in 1 case (1.3%), graft edema in 2 cases (2.6%), granuloma in 1 case (1.3%).

At the end of 6 months post operatively, recurrence was found to be equal 4 cases (5.2%) in both the groups as shown in the table and figure below.

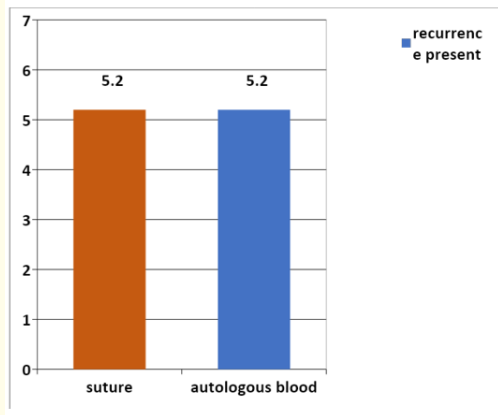


Figure 8: Comparison of recurrence at the end of 6 month based on surgery.

Chi-Square tests			
	χ^2	df	p value
Pearson Chi-Square tests	0.00	1	1.000
p value = 1 (> 0.05), which is statistically not significant.			

Table 5

Discussion

In this study, most of the patients were in 36-50 years age group. The oldest patient was 70 years and youngest 24 years. A male preponderance was noticed. The distribution of pterygium was found to be higher in those working outdoors as compared to those working indoors. This is due to the higher lifetime UV exposure. Of the total 154 pterygia, 145 were nasal and 9 were temporal. Nasal presentation being more common is seen due to transmission of UV light from temporal side of cornea through the stroma on to the nasal aspect of eye, perhaps explaining why these lesions are more common nasally [8,9]. In this study, the percentage distribution of pterygia was found to be more frequent in the right eye compared to left eye. In this study no intraoperative complications were noticed. Postoperative complications noted were pain, foreign body sensation, watering, subconjunctival hemorrhage, graft displacement, graft loss, cystic swelling, dellen, graft edema, granuloma. Incidence of postoperative pain (sutures = 27.3% > autologous blood = 5.2%), foreign body sensation (S = 37.6% > A = 2.6%), watering (S = 37.6% > A = 2.6%), and subconjunctival hemorrhage (S = 20.8% > A = 1.3%) at 1 week postoperative period was higher for sutures. This was statistically analysed by Chi square

test and p value = 0, which was statistically significant. However all symptoms resolved within 4 weeks.

The above findings are shown in the figure below.

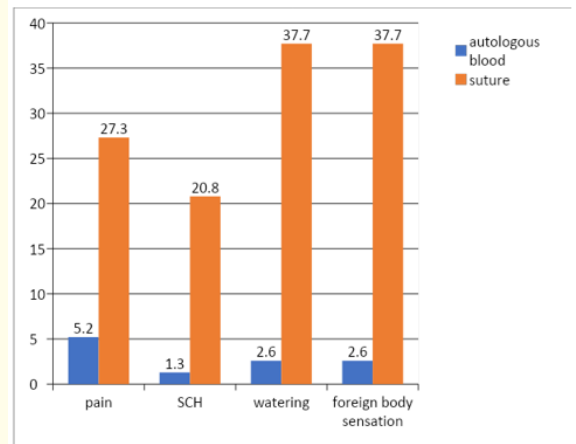


Figure 9: SCH: Subconjunctival Hemorrhage.

In this study, graft displacement was noticed in 6 eyes (7.8%) and graft loss in 2 eyes (2.6%) in autologous blood coagulum group. However graft displacement was noticed only in 1 eye (1.3%) in suture group. No graft loss was seen in suture group. This was statistically analyzed by Chi square test and p value = 0.016, which was statistically significant. Recurrence was equal 4(5.2%) in both the groups.

This was statistically analyzed by Chi square test, p value = 1, which was statistically not significant.

Other complications were cystic swelling in 1 patient in autologous blood group (1.3%), dellen and granuloma in 1 patient in suture group (1.3%), graft edema 2 each in both groups. This was statistically analyzed by Chi square test and p value = 0.557 which was statistically not significant.

Conclusions

Graft stability is higher in the suture group. BCVA is unrelated to the method used to fix the graft. Postoperative complications like pain, foreign body sensation, watering and subconjunctival hemorrhage were more in the suture group but subsided with treatment in 4 weeks. No intra-operative complications were noticed in either group. Both groups had equal number of recurrences.

Acknowledgements

I am very much obliged to Dr. Leila Mohan, Director of Post Graduate Studies and Research, Comtrust Eye Hospital, whose ever-inspiring guidance and critical judgment has been very important in the realization of this thesis. Without her untiring help and sincere criticism, the present work would not have been possible. I feel deeply indebted and thankful to Dr.M.S. Vijayalakshmi, who took special interest to help me in case selection and evaluation. Without her able guidance and encouragement, I would not have been able to complete this study.

I am very grateful to Dr. Nivean, MN eye hospital, Chennai for his valuable support and advice.

Conflicts of Interest

No conflict of interest exists.

Bibliography

1. Youngson RM. "Recurrence of pterygium after excision". *British Journal of Ophthalmology* 56 (1972): 120-125.
2. Detels R and Dhir SP. "Pterygium: a geographical study". *Archives of Ophthalmology* 78.4 (1967): 485-491.
3. P Sivasubramaniam. "Pterygium in Ceylon". *British Journal of Ophthalmology* 55 (1971).
4. JR Rojas and H Malaga. "Pterygium in Lima, Peru". *Annals of Ophthalmology* 18.4 (1986): 147-149.
5. Cameron, ME. "Pterygium throughout the world". Charles C Thomas, Springfield, IL (1965).
6. Ang LP, et al. "Current concepts and techniques in pterygium treatment". *Current Opinion on Ophthalmology* 18 (2007): 308-313.
7. Krachmer JH., et al. *Cornea*, 2nd ed. (Philadelphia: Elsevier Mosby), (2005): 1481.
8. Saw SM and Tan D. "Pterygium: prevalence, demography and risk factors". *Ophthalmic Epidemiology* 6 (1999): 219-228.
9. Threlfall TJ and English DR. "Sun exposure and pterygium of the eye: a dose-response curve". *American Journal of Ophthalmology* 128 (1999): 280-287.