Acta Scientific Ophthalmology (ISSN: 2582-3191)

Volume 4 Issue 9 September 2021

Research Article

Reduced Contribution of Capillaries to Parafoveal Perfusion Before Changes of Vessel Density in Arterial Hypertension

Fernando José Macouzet-Romero, Gabriel Antonio Ochoa-Máynez, Olivia Pérez-García, Beatriz Jatziri Pérez-Aragón and Virgilio Lima-Gómez*

Retina Department, Sala Uno Ophthalmology Clinic, Mexico

***Corresponding Author:** Virgilio Lima-Gómez, Retina Department, Sala Uno Ophthalmology Clinic, Mexico.

Received: May 23, 2021

Published: August 13, 2021

Abstract

Introduction: Arterial hypertension decreases vessel and perfusion density, measured with optical coherence tomography angiography, in people without retinopathy. The contribution of parafoveal capillaries to foveal perfusion might change before capillary densities decrease and could be measured with a coefficient of determination.

Materials and Methods: Non-experimental, prospective, comparative cross-sectional study in people with and without arterial hypertension, that compared vessel and perfusion densities in the superficial parafoveal capillary plexus with a 3 x 3 optical coherence tomography angiography (Cirrus 6000 with Angio Plex) between groups (Mann-Whitney's U. Coefficients of determination were calculated to learn the contribution of vessel density to perfusion density in each group.

Results: 15 eyes in each group, there were no differences in age, or any of the vessel and perfusion densities between groups. The coefficients of determination were lower in people with arterial hypertension and reached up to 15 percentage points in the superior and temporal fields; these changes show a reactive dilatation of vessels larger than capillaries.

Conclusion: The contribution of capillaries to perifoveal perfusion, measured with a coefficient of determination, decreased before vessel density in people with arterial hypertension.

Keywords: Angio OCT; Arterial Hypertension; Coefficient of Determination; Perfusion Density; Vessel Density

Abbreviation

OCT: Optical Coherence Tomography

Introduction

Optical coherence tomography (OCT) angiography evaluates the parafoveal capillaries quantitatively. Two commonly used variables are vessel density (the sum of the length of capillaries with circulation in a defined area, measured in mm/mm^2 (mm^{-1}) and perfusion density, the percentage of an area where there is circulation [1]. Vessel density contributes to perfusion density, but the second one includes circulation of vessels larger than capillaries as well.

Angio OCT is currently used to measure reductions in vessel and perfusion density in retinal vascular diseases, such as diabetic retinopathy and hypertensive retinopathy. Arterial hypertension is

a common chronic disease, and a reduction of vessel density has been identified early in the disease [2,3]. The vascular changes of arterial hypertension that lead to a reduction of vessel density could start by changing the contribution of capillaries to perfusion density, and this change could be measured by a coefficient of determination between vessel and perfusion densities.

We conducted a study to compare the coefficient of determination between vessel and perfusion densities in people with and without hypertension, an learn whether capillary contribution to parafoveal circulation required a larger participation of vessels larger than capillaries to keep a perfusion level.

Materials and Methods

This was a non-experimental, prospective, comparative, cross sectional study. The sample was obtained from people who accompanied patients treated at an Ophthalmic Referral Center in Mexico City. The study took place from March 1st to May 21st 2021 and adhered to the tenets of the Declaration of Helsinki; the identity of the people who entered the study was kept confidential.

We included people from any gender, aged 40 to 70 years, with a diagnosis of essential arterial hypertension, who received treatment for this disease for a year or longer, with a corrected visual acuity ≥ 20/40, who accepted to participate in the study; we selected age-matched people without arterial hypertension, with systolic blood pressure below 121 mmHg and diastolic blood pressure below 81 mmHg for the reference group. We did not include people with diabetes, metabolic syndrome, smokers, who had drunk any caffeine beverage on the day of the evaluation, who had any retinopathy or ocular media opacities that prevented obtaining angio OCT maps of adequate quality. We excluded people whose angio OCT maps had artifacts or measurement errors.

All the participants underwent a complete ophthalmic evaluation. Then a 3 x 3 mm density map of the superficial parafoveal capillary plexus was obtained with the Cirrus 6000 with AngioPlex equipment (Zeiss, Dublin CA). A single investigator obtained al the density maps; and excluded all the maps with a signal strength ≤ 7.

People without arterial hypertension were assigned to group 1, and people with arterial hypertension were assigned to group 2. We compared the following variables between groups: center vessel density, inner vessel density, full vessel density, superior vessel density, inferior, vessel density, temporal vessel density, nasal vessel density, center perfusion density, inner perfusion density, full perfusion density, superior perfusion density, inferior perfusion density, temporal perfusion density and nasal perfusion density. All the densities were measured automatically by the equipment.

We then calculated the coefficient of determination between corresponding vessel and perfusion densities (e.g. center vessel density and center perfusion density). We used the Shapiro-Wilk Test to evaluate a normal distribution of the variables, a Mann-Whitney's U test to compare the densities between groups and considered a p value < 0.05 as a statistical difference.

Results

We evaluated 15 eyes from 15 patients in each group. Median age was 55 years (47 - 63) in group 1 and 54 years (47 - 63) in group 2 (p = 0.9). There were 9 women in group 1 (60%) and 13 in group 2 (86-7%, p = 0.1). The Shapiro-Wilk test identified that temporal vessel density (p = 0.020) in group 1 and inner (p= 0.046), temporal (0.015) and nasal (0.004) densities in group 2 did not have a normal distribution.

The distribution of angio OCT variables is shown in table 1. There were no statistical differences between groups in any variable.

Although the variable distribution did not vary between groups, the coefficient of determination between corresponding vessel and perfusion densities was always lower in group 2 (Table 2). The difference was larger for inner (Figure 1), superior and temporal densities (Figure 2).

Discussion

The lower coefficient of determination shows that the contribution of capillaries to perfusion density decreases in arterial hypertension before a reduction of vessel density becomes evident.

In this study the vessel and perfusion densities in people with arterial hypertension were not lower than those of people without hypertension, a difference with studies that evaluated people without hypertensive retinopathy as well. Both with other angio OCT devices [4,5] and with Cirrus 5000 with AngioPlex [6]. However, the percentage of perfusion density that was explained by vessel density was lower in people with hypertension. The difference was

Variable	Group 1	Group 2
Center vessel density (mm^{-1})	9.4 (8 - 11.2)	10.0 (8.0 - 13.1)
Inner vessel density (mm^{-1})	21.7 (20.4 - 23.1)	22.0 (20.6 - 23.2)
Full vessel density (mm^{-1})	20.3 (18.8 - 21.6)	20.4 (19.6 - 21.8)
Superior vessel density (mm^{-1})	21.6 (19.6 - 23.1)	22.2 (21.1 - 23.2)
Inferior vessel density (mm^{-1})	22.0 (21.0 - 22.7)	21.4(20.2 - 23.8)
Temporal vessel density (mm^{-1})	21.8 (18.9 - 22.4)	22.7 (21.3 - 23.5)
Nasal vessel density (mm^{-1})	22.0 (20.5 - 23.2)	22.1 (20.5 - 22.8)
Center perfusion density (%)	17.3 (13.8 - 20.0)	18.1 (14.4 - 21.7)
Inner perfusion density (%)	40.1 (36.9 - 42.6)	41.5 (39.3 - 42.4)
Full perfusion density (%)	37.3 (34.4 - 40.3)	38.1 (36.9 - 39.4)
Superior perfusion density (%)	40.5 (35.6 - 42.0)	40.1 (39.3 - 42.9)
Inferior Perfusion density (%)	40.6 (36.6 - 42.0)	41.1 (39.4 - 43.0)
Temporal perfusion density (%)	40.6 (35.8 - 42.4)	41.4 (39.5 - 42.4)
Nasal perfusion density (%)	41.6 (36.5 - 43.3)	41.3 (39.6 - 41.8

Table 1: Variable comparison between groups (median, interquartile range).

Variables	Group 1	Group 2
Center	0.984	0.973
Inner	0.884	0.794
Full	0.900	0.824
Superior	0.912	0.768
Inferior	0.687	0.615
Temporal	0.859	0.705
Nasal	0.940	0.908

Table 2: Determination coefficient (R^2) between vessel and perfusion densities by group.

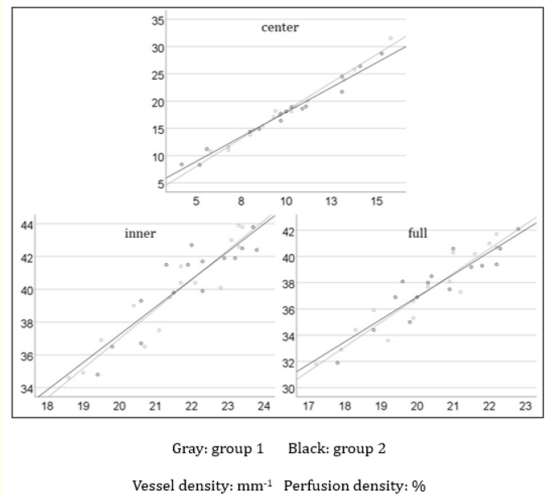

Figure 1: Scatterplots of vessel density (x axis) and perfusion density (y axis) by group.

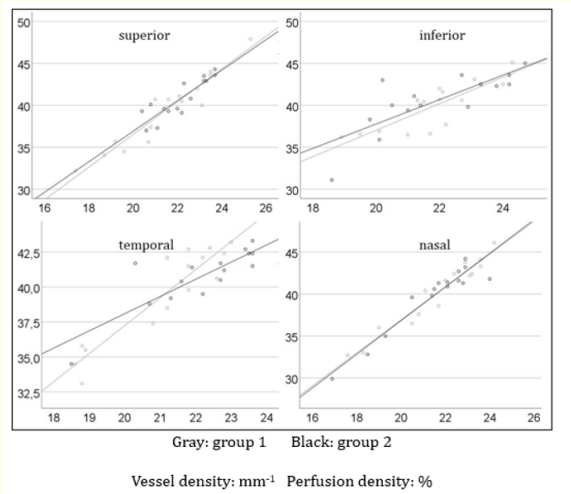

Figure 2: Scatterplots of vessel density (x axis) and perfusion density (y axis) by group and field.

only 1 percentage points I the center, where there are almost only capillaries, but it rose to 15 percentage points in the superior and temporal fields of the map.

Although the study was not designed to explain the capillary changes that lead to a lower contribution of these vessels to perfusion density, the lower coefficients of determination show that there is a dilatation of vessels larger than capillaries in people with arterial hypertension. This vasodilatation probably corresponds to arteries [7] and may reflect a reduced oxygen delivery, that induces a reactive response.

The study strengths were the automated measurements of densities and the pairing of groups according to age. Potential weaknesses are the small sample size and the wide age range; although there were no statistical differences of any density variable between groups, we recommend evaluating the differences of coefficient of determination in larger groups. We are also aware that the findings are limited to people from Mexico City.

The change of capillary contribution resulting from a reactive dilatation of vessels larger than capillaries needs evaluation as a biomarker; the results of this study cannot still define a point where the contribution of larger vessels indicates functional or anatomic damage to the retina, as it has been associated with vessel density reduction [8], but show that there is an alteration of vessel dynamics that appears before commonly used variables change. Specifically designed studies will be needed to address the impact of this early findings in people with arterial hypertension.

Conclusion

The contribution of capillaries to perifoveal perfusion, measured with a coefficient of determination, decreased before vessel density in people with arterial hypertension.

Acknowledgements

Thanks to Zeiss Mexico, for the unrestricted support to use the Cirrus 6000 with AngioPlex equipment.

Conflict of Interest

There is no financial interest or any conflict of interest to declare.

Bibliography

1. Rosenfeld PJ., *et al*. "Zeiss AngioPlex spectral domain optical coherence tomography angiography: technical aspects". *Developments in Ophthalmology* 56 (2016): 18-29.
2. Xu Q., *et al*. "Retinal microvascular metrics in untreated essential hypertensives using optical coherence tomography angiography". *Graefe's Archive for Clinical and Experimental Ophthalmology* 259.2 (2021): 395-403.
3. Sun C., *et al*. "Systemic hypertension associated retinal microvascular changes can be detected with optical coherence tomography angiography". *Scientific Reports* 10.1 (2020): 9580.
4. Hua D., *et al*. "Use of optical coherence tomography angiography for assessment of microvascular changes in the macula and optic nerve head in hypertensive patients without hypertensive retinopathy". *Microvascular Research* 129 (2020): 103969.
5. Donati S., *et al*. "Optical coherence tomography angiography and arterial hypertension: A role in identifying subclinical microvascular damage?" *European Journal of Ophthalmology: SAGE Journals* 31.1 (2021): 158-165.
6. Lee WH., *et al*. "Retinal microvascular change in hypertension as measured by optical coherence tomography angiography". *Scientific Reports* 9.1 (2019): 156.
7. Warner RL., *et al*. "Full-field flicker evoked changes I parafoveal retinal blood flow". *Scientific Reports* 10.1 (2020): 16051.
8. Lim HB., *et al*. "Changes in ganglion cell-inner plexiform layer thickness and retinal microvasculature in hypertension: an optical coherence tomography angiography study". *American Journal of Ophthalmology* 199.3 (2019): 167-176.

Volume 4 Issue 9 September 2021