

## Retinoblastoma

**Dr Partha Haradhan Chowdhury<sup>1\*</sup> and Brinda Haren Shah<sup>2</sup>**

<sup>1</sup>Ph.D. in Optometry (Gujarat State Government University) and Professor and Principal, Shree Satchandi Jankalyan Samiti Eye Institute - Pauri, Uttarakhand, India

<sup>2</sup>M. OPTOM, Practitioner, Ahmedabad, Gujarat, India

**\*Corresponding Author:** Dr Partha Haradhan Chowdhury, Ph.D. in Optometry (Gujarat State Government University) and Professor and Principal, Shree Satchandi Jankalyan Samiti Eye Institute - Pauri, Uttarakhand, India.

**Received:** March 23, 2021

**Published:** April 16, 2021

© All rights are reserved by **Dr Partha Haradhan Chowdhury and Brinda Haren Shah.**

### Abstract

This paper gives brief information on retinoblastoma.

**Keywords:** Retinoblastoma; Optic Nerve Layer; Retina

### Introduction

It is a malignant tumor and it is originated in the optic nerve layer of the retina. The meaning of malignant is "cancer".

Most of the time it is bilateral. Its occurrence is 1: 20000. It is congenital but mainly it is diagnosed on the 18<sup>th</sup>.

### Clinical features:

- Leukocoria: White reflex is seen.
- Squinting eye: It mainly occurs due to convergent.
- Most of the time, it is associated with secondary glaucoma, endophthalmitis.

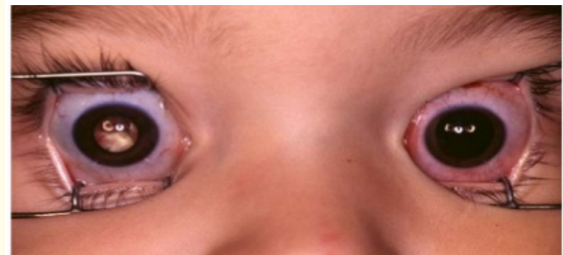### This tumor spreads directly to the:

- Inter ocular tissue.
- Extra ocular tissue like central nervous system, orbit etc.
- It may spread by the lymphatic organ.
- It is spread into Bones, Liver etc. via blood stream.

### Stages

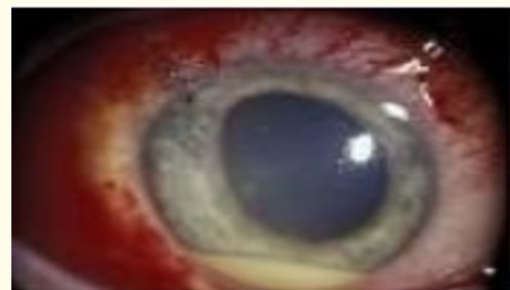
Q-G-S-S (To remember).

**Stage 1:** Quiescent stage - Stays up to 6 to 12 months.



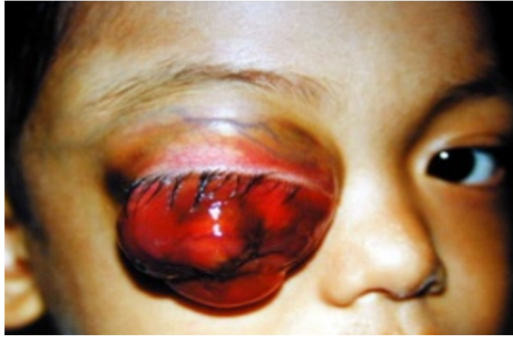**Figure 1**

**Stage 2:** Glaucomatous stage.



**Figure 2**

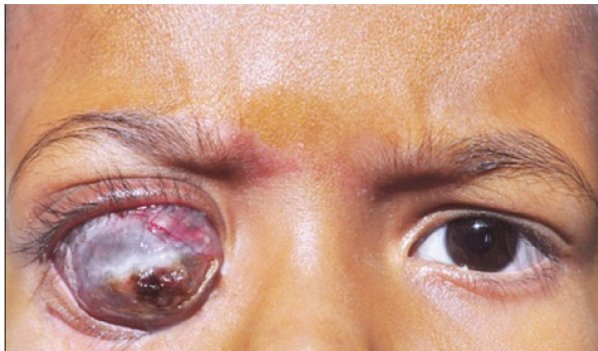**Stage 3:** Stage of extra ocular muscle tissue.



**Figure 3**

In this stage retinoblastoma spreads from one part of the eye to the other part of eye.

**Stage 4:** Stage of metastasis.



**Figure 4**

Here, retinoblastoma spreads from eye to other organs of the body.

#### Diagnosis:

1. Indirect ophthalmoscopy
2. Investigations like:
  - a. X ray
  - b. Fine needle aspiration cytology
  - c. Ultrasonography
  - d. CT scan of orbit and brain
  - e. Fluorescein angiography.

#### Treatment:

1. Enucleation: In this excision of the eye is performed.
2. Exenteration: This should be performed when orbit is involved in the tumor.
3. Radiotherapy: This should be performed in small, recurrent or residual tumors.
4. Photo coagulation: This is performed when optic nerve or macula is not involved in tumor.
5. Cryotherapy: This is performed for small peripheral tumors.
6. Chemotherapy: This should be performed in advanced cases which should be followed by enucleation.
7. Combination therapy: To achieve the best results [1-3].

#### Bibliography

1. Brad Bowling. "Kanski's Clinical Ophthalmology E-Book: A Systematic Approach". 8<sup>th</sup> Edition (2016).
2. Sihota Radhika Tandon. "Parson's Diseases of the Eye". 22<sup>nd</sup> Edition (2018).
3. Samar K Basak. "Clinical Ophthalmology" (2009).

#### Assets from publication with us

- Prompt Acknowledgement after receiving the article
- Thorough Double blinded peer review
- Rapid Publication
- Issue of Publication Certificate
- High visibility of your Published work

**Website:** [www.actascientific.com/](http://www.actascientific.com/)

**Submit Article:** [www.actascientific.com/submission.php](http://www.actascientific.com/submission.php)

**Email us:** [editor@actascientific.com](mailto:editor@actascientific.com)

**Contact us:** +91 9182824667