



The Incidence of Macular Ectopia in Eyes Previously Diagnosed as Amblyopic

Nataliia Karandiuk* and Anastasiia Kalyshenko

Department of Ophthalmology, Clinic of Vision Recovery, Ukraine

***Corresponding Author:** Nataliia Karandiuk, Department of Ophthalmology, Clinic of Vision Recovery, Ukraine.

Received: February 20, 2021

Published: March 10, 2021

© All rights are reserved by **Nataliia Karandiuk and Anastasiia Kalyshenko.**

Abstract

Background/Objectives: To define the incidence of macular ectopy in amblyopic children and evaluate the relationship between the presence of macular ectopia and visual acuity (VA) using optical coherence tomography (OCT).

Subjects/Methods: There were evaluated 52 eyes of 37 patients. 32 patients (52 eyes) were in control group with best corrected visual acuity (BCVA) and no OCT findings of macular ectopia. Control group was used to define standard deviation of distance between fovea and optic nerve. To define the presence\ absence of macular ectopia was used manual tool "caliper" of measurements. The measurement was performed from the beginning of complex of RPE+Bruch's membrane from Optic disc and ending in the foveal center. In cases of dislocation of macula up or down from optic nerve (figure 3) we calculated distance by the Pythagorean Theorem. The correlation between presence, distance and direction of macular ectopia and BCVA was determined.

Results: Of 52 amblyopic eyes 34 were with macular ectopia, 19,2% of eyes presented strabismus and 26,9% of eyes had a hypoplasia macular. BCVA in logMAR was not correlated with presence of macular ectopia (p value=0,086712) nor with CMT (p value=0,670086). The majority of eyes (58,8%) with macular ectopia has just temporal displacement (p value=0,006741).

Conclusions: The incidence of macular ectopia in amblyopia eyes is 65,3%. The OCT measurements according to distance between Optic disc and foveal center are effective for determining the presence of macular ectopia. Majority of patients with strabismus have macular displacement. The presence of macular ectopia doesn't affect visual acuity.

Keywords: Macular Ectopia; Amblyopia; Optical Coherence Tomography (OCT)

Introduction

Amblyopia is a loss of vision as a consequence of an impairment or alteration during the normal development of vision (Evans, 2006). Ciuffreda (1991) defined it as the abnormal development of vision, due to a physiological alteration in the visual cortex with the consequent decrease in vision. It has also been defined as a condition that causes reduced central vision, not correctable by refractive means, which cannot be attributed to obvious structural or pathological abnormalities of the eye.

The most frequent causes of amblyopia are: Firstly, strabismus, since 30% of untreated strabismus children will have amblyopia. The figure varies depending on the type of strabismus, being less in the divergent than in the convergent ones. Anisometropias or refractive differences between both eyes, if they are > 1.5 diopters (D) and are not corrected at the time, produce amblyopia in the eye with the greatest refractive defect, since the child's brain (being able to send only a single and equal order of focus to both eyes) chooses the vision of the eye with the least defect, producing a blur

in the eye with the greatest defect (which does not develop its visual capacity well). Major bilateral ametropia or refractive defects, if not corrected early, produce bilateral amblyopia, since the image does not reach the retina of both eyes in focus. Generally, hyperopia greater than 6 D and astigmatism greater than 3 D; myopia is theoretically less cause amblyopia (as the eye is focused closely). Nystagmus usually causes bilateral amblyopia and frequently coexists with large ametropia. And, finally, eye diseases, such as: palpebral ptosis, congenital cataract, corneal lesions, retinal lesions, etc., which have in common the existence of an associated organic factor and produce severe deprivation amblyopia, since they interfere with the correct development of vision in children small by depriving them of the visual experience. It is very difficult to resolve amblyopia, despite the anatomical success of the treatment of these alterations and, at times, can affect both eyes.

Amblyopia also can be classified according to the VA of the amblyopic eye:

- Low: the VA of the amblyopic eye is greater than 0.5.
- Severe: VA of the amblyopic eye is 0.1 to 0.5.
- Moderate: said VA is less than 0.1.

Prevalence of amblyopia

The prevalence of amblyopia worldwide is approximately 1%-5%. The World Health Organization (WHO) estimates 19 million children less than 15 years of age are visually impaired; of those, 12 million are impaired due to uncorrected refractive errors and amblyopia.

It is considered that macular ectopia, unless it is very mild, it usually cause poor central vision and can be confused with amblyopia.

The term of macular ectopia encompasses a relatively rare pathology, which involves an abnormal position of the macula (usually macula is displaced temporally).

From the anatomical point of view and following the LANDOLT scheme, it can be found that the macula is located in the temporal sector of the retina at 3.915 mm of the papilla and at 0.78 mm below it, with an angle of inclination of the foveal center - papilla axis of 15° , taking into account that the papilla measures 1.5 mm in diameter, it could be said that the macular region is about two

papillary diameters from the edge of the papilla and towards the temporal side.

Reviewing the literature, it can be observed that there is some confusion when labeling this term, because some authors speak of heterotopy for some cases and of ectopy for others, when for certain authors both terms are meaning the same.

According to the first group of authors (Decourt (1963), Woillez (1964), François (1976)) the following classification can be made:

- Heterotopia or true ectopia - Anomaly of the development of the posterior pole of the globe. It is usually one-sided (Sometimes bilateral and symmetric (Bonnet 1974). It is accompanied by papillary diversion. Growing coloboma (Bonnamour 1960) rotation of the lens sutures. - Presents good visual acuity and pseudostrabismus due to alpha angle alteration.
- Acquired macular ectopia - Secondary to trauma, vascular or inflammatory processes before the definitive development of the macula (sixth month of extrauterine life). It is usually one-sided. It is usually accompanied by papillary diversion and associated pathology. Presents poor visual acuity, strabismus and diplopia or amblyopia.

The most common examinations to diagnose the macular ectopia were: ophthalmoscopy and fundus photography, additionally was used synaptophore to capture fixing deviation and the Hess screen to confirm muscle imbalance. Nowadays we can use optical coherence tomography (OCT) to capture and mid the macular ectopia.

In this study we aimed to investigate the incidence of macular ectopia in eyes with amblyopia and evaluate the OCT-findings of the macula and visual acuity (VA) in eyes with amblyopia.

Methods

Retrospective, cross-sectional and descriptive study of patients with Diagnosis of Amblyopia observed in Clinic of vision recovery in Kyiv.

The study was approved by the Health Area Clinical Research Ethics Committee (Commission of Investigation of Clinic of vision recovery in Kyiv) - all the research work in it adheres to the bioethical principles of the Declaration of Helsinki.

Study population

Patients previously diagnosed as Amblyopic.

Inclusion criteria

- Children of 4-18 years old diagnosed as Amblyopic
- Patients who have a medical history that includes at least one complete ophthalmological examination
- Patients who have undergone OCTs, which allow the evaluation of the results.

Exclusion criteria

- Patients with inflammatory retinal diseases (uveitis, proliferative vitreoretinopathy), optic nerve atrophy, cataract and other diseases that lead to visual loss (except anomalies of refraction, strabismus and nystagmus)
- Patients who do not have data in the medical records
- Patients with poor quality OCT images or media’s opacity that prevents their correct interpretation.

Methods

The study variables were collected at the time of the study using OCT.

The non-tomographic variables were obtained from the records in the clinical history of each patient and the tomographic variables from the team’s databases, based on the observations made by a single observer (measurements of distance Optic disc-foveal center were made by two observers). Table 1 shows the study variables.

| Demographic variables | Clinical variables |
|-----------------------------------|-------------------------------------|
| Age | Best corrected visual acuity (BCVA) |
| Sex | Affected eye |
| | Refraction |
| | Presence of strabismus |
| Tomographic variables | |
| Quantitative | Qualitative |
| Central macular thickness (CMT) | Presence of macular ectopia |
| Distance Optic disc-foveal center | Direction of macular ectopia |
| | Presence of macular hypoplasia |

Table 1: Study variables.

Visual acuity

The visual acuities recorded in the clinical histories in decimal scale were translated to the LogMAR scale (logarithm of the minimum angle of resolution) to unify the format of the variable in the sample and its subsequent statistical analysis. The formula of Khoshnood B., *et al.* [1] have been used for it.

Optical coherence tomography (OCT)

The OCTs included in this study were performed with the Optopol Revo (Poland) 3D spectral domain OCT model that allows the cube-section measurement of a 6 x 6 mm area centered in the fovea.

For the study of the quantitative variables of thickness and volume, the ETDRS grid was used, centered on the fovea, which shows the total average thickness in nine sectors, being the value of the central circle that has a radius of 500 microns (diameter 1 mm), which is identified as central macular thickness (CMT), was obtained from the report generated from each OCT (Figure 1).

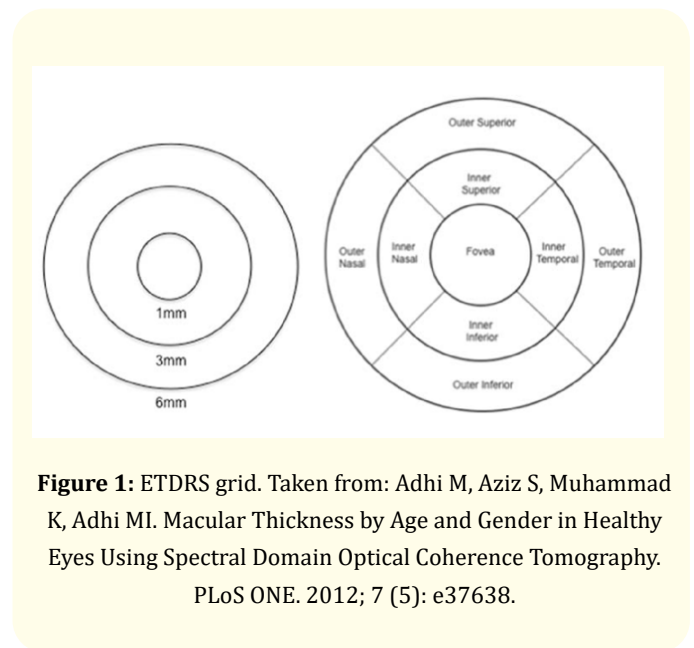


Figure 1: ETDRS grid. Taken from: Adhi M, Aziz S, Muhammad K, Adhi MI. Macular Thickness by Age and Gender in Healthy Eyes Using Spectral Domain Optical Coherence Tomography. PLoS ONE. 2012; 7 (5): e37638.

In cases when automatically centration was not been able the ETDRS grid was replaced manually to the fovea.

Since SD OCT 3D OCT (Optopol) does not allow automatic measurement of the distance between Optic disc and foveal center,

manual tool “caliper” of measurements has been used for this. In cases of temporal or nasal macular dislocation it was performed the measurement from the beginning of complex of RPE+Bruch’s membrane from Optic nerve and ending in the foveal center (Figure 2).

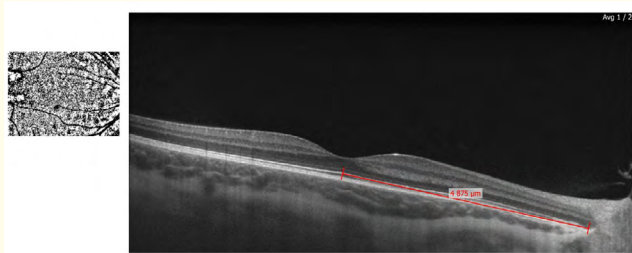


Figure 2

In cases of dislocation of macula up or down from optic nerve (Figure 3) we calculated distance by the Pythagorean Theorem: the sum of the squares of two legs is equal to the square of the hypotenuse ($a^2+b^2=c^2$), so to find hypotenuse it used next formula:

$$c = \sqrt{a^2 + b^2}$$

- a- number of steps of B-scansx50 microns (1 step - 50 microns)
- b- measured manually with “caliper” tool
- c- Distance Optic disc-foveal center.

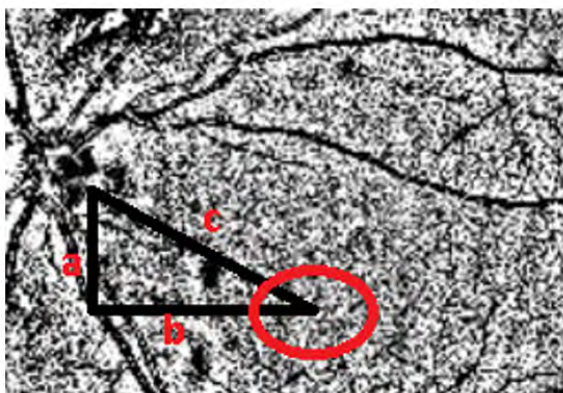


Figure 3

The evaluation of the qualitative variables has been carried out throughout the entire macular cube and they have been defined as follows:

Macular ectopia - is a condition in which the *macula* is displaced markedly from its normal position and it is notable visually in fundus reconstruction on OCT image (Figure 1).

Fundus reconstruction

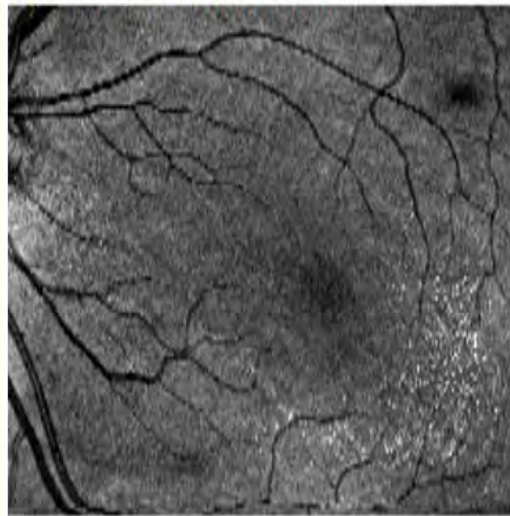


Figure 4: Fundus reconstruction of eye with macular ectopia in lower temporal direction.

The middle distance between foveal center and optic nerve in control group was $3975,28 \pm 335,5$ microns. Due to this data the “normal macular position” was defined as location of macula in the temporal sector of the retina at 3.975 mm ($3975,28 \pm 335,5$ microns of the papilla and at 780 microns(LANDOLT scheme) below it.

Direction of macular ectopia was defined as:

- Temporal (distance between foveal center and optic nerve more than 4310,5 ($3975,28 + 335,5$) microns)
- Temporal-up (distance between foveal center and optic nerve is more than 4310,5 microns in upper direction that is notable visually in fundus reconstruction on OCT image)
- Temporal down (distance between foveal center and optic nerve more than 4310,5 microns in lower direction)

that is notable visually in fundus reconstruction on OCT image)

- Nasal (distance between foveal center and optic nerve is less than 3639,5 (3975,28 -335,5) microns)
- Nasal-up (distance between foveal center and optic nerve is less than 3639,5 microns in upper direction that is notable visually in fundus reconstruction on OCT image)
- Nasal-down (distance between foveal center and optic nerve is less than 3639,5 microns in lower direction that is notable visually in fundus reconstruction on OCT image)
- Down (distance between foveal center and optic nerve is 3975,28±335,5 microns but macula is displaced down direction that is notable visually in fundus reconstruction on OCT image)
- Up (distance between foveal center and optic nerve is 3975,28 ±335,5 microns but macula is displaced up direction that is notable visually in fundus reconstruction on OCT image) (Figure 5).

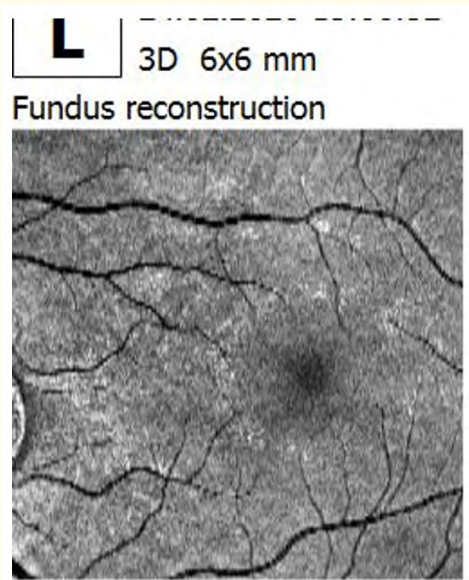


Figure 5: Fundus reconstruction of eye with macular ectopia in upper direction.

All measurements are carried out independently by two investigators to try to avoid bias.

Statistic analysis

Visual acuity was converted to the logarithm of the minimum angle of resolution of visual acuity (logMAR) for statistical analysis.

Microsoft Excel (Microsoft Corp, Redmond, WA) was used for data accumulation and statistical analysis.

Statistical analysis included parametric tests (paired and independent t tests; one and two-way analysis of variance [ANOVA]) and nonparametric tests (chi-square test, Wilcoxon signed-rank test, Friedman test, Mann test -Whitney, and Kruskal-Wallis test).

Step-by-step logistic regression was performed to evaluate the presence of predictors of poor response to treatment. Pearson's coefficient was calculated to correlate visual acuity results with OCT-measured variables.

Statistically significant data were defined with $p < 0.05$.

This study followed the principles established in the Declaration of Helsinki.

The entire statistical study was carried out with the support of statistic specialist (Egor Gritsenko).

Results

Sample description

There were analyzed 52 consecutive eyes of 37 patients previously diagnosed as amblyopic (mean age: $8,6 \pm 3,37$ years, male to female ratio: 21:16) were evaluated in a single institution between January 2018 and February 2021. Also we had a control group of 52 eyes of 32 patients with BCVA 20\20 (including emetropic, hypermetropic, myopic eyes and eyes with astigmatism) with no notable visually dislocation of macula. Control group was only analyzed to define standard deviation of distance between fovea and optic nerve. The exclusion criteria were eyes with inflammatory retinal diseases (uveitis, proliferative vitreoretinopathy), optic nerve atrophy, cataract and other diseases that lead to visual loss (except anomalies of refraction, strabismus and nystagmus), poor quality of OCT images.

46,2% of right eyes and 53,8% of left eyes were included.

With respect to type of ametropia, the patients presented: hypermetropia - 40,4%, Myopia - 11,5%, astigmatism - 46,2%, emetropia - 1,9%.




Figure 6: Distribution by type of refraction.




Figure 8: Incidence of macular ectopia.

19,2 % of eyes presented strabismus and 26,9% of eyes had a hypoplasia macular.

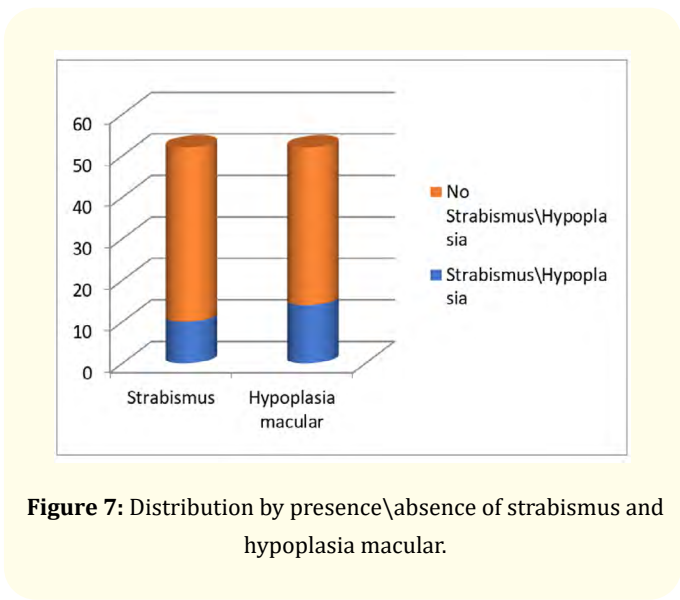


Figure 7: Distribution by presence\absence of strabismus and hypoplasia macular.

According to previous definition 65,3% of investigated eyes had a macular ectopia.

Distribution of macular ectopia due to displacement's direction was next:

- Temporal - 58,8%
- Temporal-up -0
- Temporal-down - 11,8%

- Nasal - 3%
- Nasal-up -0
- Nasal-down - 8,8%
- Down - 8,8%
- Up - 8,8%

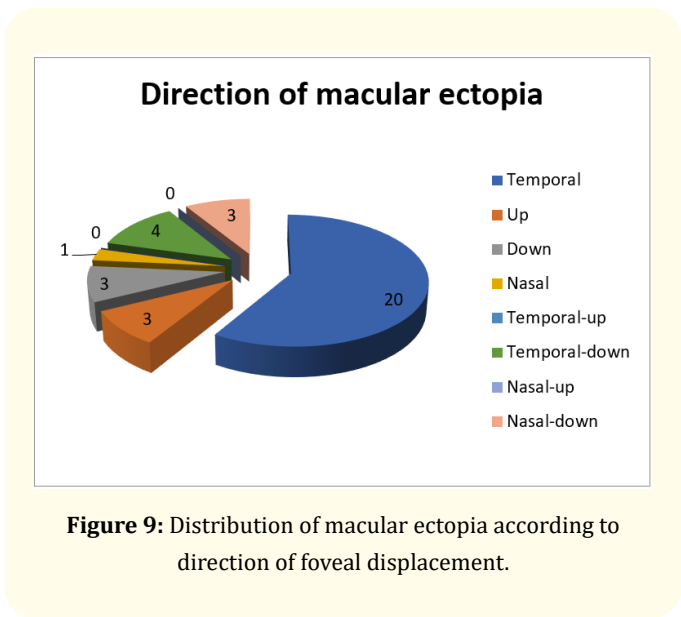


Figure 9: Distribution of macular ectopia according to direction of foveal displacement.

Summary of clinical variables are presented in the following table (Table 2).

| Clinical variable | Meddle | Minimal | Maximum |
|---|----------|---------|---------|
| Age | 8,6 | 4 | 15 |
| BCVA (LogMAR scale) | 0,44 | 1,3 | 0,08 |
| CMT, microns | 235,4 | 197 | 277 |
| Distance "foveal center - optic nerve", microns | 4176,192 | 3097 | 6475 |

Table 2

Patients had a mean baseline of BCVA of 0.44 ± 0.39 on the log-MAR scale.

Within the demographic variables included in the study, neither age nor sex showed a relationship with the presence of macular ectopia in our sample (Table 3). There were no statistically significant differences according to the clinical variables (affected eye, refraction, presence of strabismus or macular hypoplasia). The presence of macular ectopia did not influence in BCVA (p value = 0,086712), but it significantly correlate with direction of macular displacement (p value = 0,006741) and poorly correlate with presence of strabismus (p value= 0,050964) table 3 and distance "foveal center - optic disc" (p value=0,033646) (Table 4).

Relationship of p values between the study variables is presented in the following table (Table 3).

| | Age | Sex | Affected eye | Refraction | BCVA | Presence of hypoplasia macular | Presence of strabismus | CMT |
|---|----------|----------|--------------|------------|----------|--------------------------------|------------------------|----------|
| Presence of macular ectopia | 0,913214 | 0,56885 | 0,454367 | 0,324439 | 0,086712 | 0,163127 | 0,050964 | 0,670086 |
| Distance "foveal center - optic nerve", microns | 0,448871 | 0,054477 | 0,16452 | 0,948355 | 0,365587 | 0,230011 | 0,661855 | 0,185063 |
| Direction of macular ectopia | 0,396937 | 0,245365 | 0,28295 | 0,943296 | 0,545249 | 0,076214 | 0,002114 | 0,135897 |

Table 3

Relations of p values between the macular ectopia variables (Table 4).

| | Distance "foveal center - optic disc", microns | Direction of macular ectopia |
|-----------------------------|--|------------------------------|
| Presence of macular ectopia | 0,033646 | 0,006741 |

Table 4

| | Presence of macular ectopia | Distance "foveal center - optic nerve", microns | Direction of macular ectopia | Presence of hypoplasia macular | CMT |
|------|-----------------------------|---|------------------------------|--------------------------------|----------|
| BCVA | 0,086712 | 0,365587 | 0,545249 | 0,590021 | 0,498107 |

Table 5

Relations of p values between BCVA and OCT-findings (Table 5).

Table 6 shows very good (almost perfect) agreement strength between two researchers.

Analysis of concordance between researchers

| | CCI | IC95% | IC95% |
|-----------|---------|---------|---------|
| EXT_X_INI | 0,99998 | 0,99997 | 0,99999 |
| EXT_Y_INI | 0,99871 | 0,99793 | 0,99949 |
| ALT_INI | 0,99999 | 0,99999 | 1 |
| EXT_X_3M | 0,99998 | 0,99997 | 0,99999 |
| EXT_Y_3M | 1 | 0,99999 | 1 |
| ALT_3M | 0,99992 | 0,99987 | 0,99997 |
| EXT_X_F | 0,95202 | 0,92317 | 0,98087 |
| EXT_Y_F | 0,98856 | 0,98146 | 0,99565 |
| ALT_F | 0,99999 | 0,99999 | 1 |

Table 6: Values of agreement between two researchers.

Discussion

Reviewing the literature respect to macular ectopia we revealed that the majority of papers described macular displacement as a secondary condition of retinopathy of prematurity or other diseases, there were several papers that describe some clinical cases, and most of them have been written in the XX century. However the macular ectopia isn't such rare condition as used to think. Modern technology allows us to identify and analyze macular dislocation [2-12].

One of the main non-invasive techniques that helps us to determine the characteristics macular ectopia is SD-OCT. Qualitative evaluation of OCT images shows localization of the lesion, morphological changes in the retina, while quantitative evaluations, such as macular maps, provide measurements of macula thickness. The quality of modern optical coherence tomographs makes it possible to determine presence, direction of macular ectopia and measure distance between optic disc and foveal center.

Although we did not find a relationship between visual acuity and macular ectopia, we determined that the majority of patients with Amblyopia did have macular displacement. The most cases of macular ectopia described in the literature have dislocation in the lower temporal or nasal direction; however in our study the majority of eyes (58,8%) has just temporal displacement (p value=0,006741), that not always can be detected during ophthalmoscopy.

Also we find that majority of patients with strabismus has macular displacement in temporal or lower temporal direction (p

value=0,002114).

So in this sense the SD-OCT allows to determinate and analyze distance "optic disc-foveal center".

At our disposal we had the Optopol Revo 3D-OCT, the data viewer of which did not allow visualizing the A-scans as the cross sections or "caliper" tool for measuring in enface mode, which was essential to measure the distance between optic disc and foveal center in cases of oblique displacements. For that reason we used mathematical Pythagorean Theorem.

In an attempt to minimize biases, a double reading was performed by two independent ophthalmologists, finding a good degree of correlation between them ($r > 0.95$), using the intraclass correlation coefficient study method, which provides a higher degree of reliability to the data.

It is very possible that the arrivals of the new high-resolution OCTs and with the "en face" the qualitative parameters of the optical coherence tomography will progressively acquire greater weight and contribute to improving diagnostic ability.

Limitations of the study

- Retrospective study design
- Small sample of patients
- VA data taken from medical records were taken on the decimal scale (not ETDRS)
- Manual measurement of the distance between optic disc and foveal center in cases of oblique displacements.

Conclusions

- The incidence of macular ectopia in amblyopia eyes is of 65,3%.
- SD-OCT permit measure distance between optic disc and foveal center and can help diagnosing macular ectopia.
- The majority of eyes (58,8%) with macular ectopia has just temporal displacement (p value=0,006741)
- Majority of patients with strabismus has macular displacement (p value=0,050954) and has it in temporal or lower temporal direction (p value=0,050964).
- The presence of macular ectopia doesn't affect visual acuity.

Bibliography

1. Khoshnood B., *et al.* "Transforming scales of measurement of visual acuity at the group level". *Ophthalmic and Physiological Optics* 30.6 (2010): 816-823.
2. Staurengi G., *et al.* "Proposed lexicon for anatomic landmarks in normal posterior segment spectral-domain optical coherence tomography: the IN•OCT consensus". *Ophthalmology* 121.8 (2014): 1572-1578.
3. Rodriguez Pérez JA., *et al.* "A propósito de un Caso de ectopia macular". 6 (1981): 73-81.
4. Heussen FM., *et al.* "Simple estimation of clinically relevant lesion volumes using spectral domain-optical coherence tomography in neovascular age-related macular degeneration". *Investigative Ophthalmology and Visual Science* 52.10 (2011): 7792-7798.
5. <https://www.aao.org/disease-review/amblyopia-introduction>
6. <https://www.aao.org/disease-review/amblyopia-types-diagnosis-treatment-new-perspectiv>
7. GS Willetts. "Heterotopia of the macula". *British Journal of Ophthalmology* 50 (1966): 595.
8. Mitchell Scheiman and Michael Gallaway. "Heterotopia of the macula (ectopic macula): An unusual presentation". *Optometry and Vision Science* 63.7 (1986): 567-570.
9. Siatkowski RM., *et al.* "Severe visual impairment in children with mild or moderate retinal residua following regressed threshold retinopathy of prematurity". *Journal of AAPOS* 11.2 (2007): 148-152.
10. Grace P Soong., *et al.* "Macular structure and vision of patients with macular heterotopia secondary to retinopathy of prematurity". *Retina* 28.8 (2008): 1111-1116.
11. Miriam Rahhal-Ortuño., *et al.* "Suspected ocular toxocariasis and macular heterotopia". *Romanian Journal of Ophthalmology* 64.1 (2020): 66-69.
12. Rie Hoshikawa., *et al.* "Cataract surgery in a patient with an angle gamma due to macular heterotopia". *American Journal of Ophthalmology Case Reports* 12 (2018): 97-100.

Assets from publication with us

- Prompt Acknowledgement after receiving the article
- Thorough Double blinded peer review
- Rapid Publication
- Issue of Publication Certificate
- High visibility of your Published work

Website: www.actascientific.com/

Submit Article: www.actascientific.com/submission.php

Email us: editor@actascientific.com

Contact us: +91 9182824667