



Lid Hygiene Versus Lid Hygiene Plus Microblepharoexfoliation for the Treatment of *Demodex folliculorum* Blepharitis

Michael B. Choi and Rebecca Stein*

Cornea External Disease, Cataract and Refractive Surgery Fellow, Ophthalmic Consultants of Long Island, Rockville Centre, NY, USA

***Corresponding Author:** Rebecca Stein, Cornea External Disease, Cataract and Refractive Surgery Fellow, Ophthalmic Consultants of Long Island, Rockville Centre, NY, USA.

Received: July 31, 2020

Published: August 25, 2020

© All rights are reserved by **Michael B. Choi and Rebecca Stein.**

Abstract

Purpose: To compare lid hygiene versus lid hygiene and microblepharoexfoliation (MBE) (BlephEx®) in the treatment of *Demodex folliculorum* blepharitis.

Methods: This study was an Institutional Review Board approved randomized prospective single masked trial of 50 patients with microscopically proven *Demodex* blepharitis. All subjects received lid hygiene two times a day and half were randomized to in-office MBE treatment. All subjects at baseline and one month were evaluated for the total number of *Demodex* on 4 eyelashes, Ocular Surface Disease Index (OSDI), tear osmolarity, MMP-9, Schirmer 1, Non-invasive tear break-up time (NIBUT), lipid layer thickness, meibography, lissamine green staining, and eyelid margin exam.

Results: The total number of *Demodex* decreased by 3.88 from baseline to month 1 for the lid hygiene plus MBE group vs. 0.4 for the lid hygiene alone group ($p < 0.001$). NIBUT increased 1.1 seconds from baseline to month 1 for the lid hygiene plus MBE group vs. 2.8 seconds for the lid hygiene alone group ($p = 0.52$). All other measurements were similarly not statistically significantly different (lipid layer thickness, OSDI, Osmolarity, MMP-9, Schirmer 1, meibography, lissamine green staining, and eyelid margin exam).

Conclusion: Both lid hygiene plus MBE and lid hygiene alone decreased the amount of *Demodex* with the group receiving MBE showing a greater decrease that was statistically significant ($p < 0.001$). MBE may have a positive role in the treatment of *Demodex* blepharitis.

Keywords: *Demodex folliculorum*; Lid Hygiene Plus; Dry Eye Disease

Introduction

Blepharitis is a chronic eyelid inflammation mainly involving the eyelid margin and is a common cause of chronic ocular irritation [1]. Traditionally classified as either anterior or posterior, blepharitis is seen in up to 47% of patients in a clinical setting [2].

Critically, blepharitis is a primary factor in the pathophysiology of dry eye disease (DED), inducing the cycle of hyperosmolar-

ity and tear film instability that is the hallmark of the disease [3]. While staphylococcal and seborrheic blepharitis are categorized as anterior blepharitis; meibomian gland dysfunction (MGD) (posterior blepharitis) leads to a reduction in the quality and quantity of lipid-based meibomian gland secretions (meibum) resulting in an abnormal or deficient protective outer lipid layer of the tear film [4-10]. Evaporative tear loss begins the cycle of ocular surface inflammation and tear film instability, leading to the progression of ocular symptoms and signs over time [11].

The exact pathophysiology of blepharitis remains to be elucidated. Increased rates of *Staphylococcus species* in the eyelid flora as well as increased cell-mediated immunity to the organism have been demonstrated in patients with blepharitis compared to those without [12-14]. A unification theory, Dry Eye Blepharitis Syndrome (DEBS), has been proposed as an explanation connecting dry eye and blepharitis through the mechanism of bacterial biofilm proliferation along the eyelid margin leading to chronic inflammation [15].

In addition to systemic, dermatologic and nutritional factors, infestation with the *Demodex folliculorum* mite is an established risk factor for blepharitis [16-19]. The purpose of this study is to evaluate the subcategory of blepharitis; *Demodex* blepharitis confirmed by light microscopy. Current treatment of *D. folliculorum* involves use of tea tree oil eyelid scrubs, oral ivermectin, and oral and topical metronidazole, with differing levels of success [20-22]. We investigated treatment with a new modality, microblepharoexfoliation (MBE), this is a new method of lid hygiene that aims to debride accumulated bacterial biofilm from the lid margin with a rotating brush, analogous to the removal of bacterial biofilm from the teeth with an electric toothbrush. This is done as an in-office procedure with the BlephEx® [BlephEx®LLC, Franklin, TN] system [23]. We evaluated this treatment prospectively by determining its effect on *D. folliculorum* infestation levels measured by light microscopy, subjective symptoms, and quantitative ocular surface parameters.

Patients and Methods

This was a prospective, single-masked, randomized, and IRB-approved study. The subjects included were 50 consecutive patients with *Demodex* blepharitis at a single site, Ophthalmic Consultants of Long Island (OCLI) in Rockville Centre, NY. The study was 1 month long. At the baseline evaluation, all subjects were examined and started on a 1 month regimen of lid hygiene with warm compresses for 10 minutes, two times a day [24]. Additionally, half the subjects were randomly assigned to receive in-office MBE treatment with the BlephEx® system at the initial visit. At the 1-month follow up visit, all subjects were re-evaluated and the study concluded.

Utilizing extremely conservative estimates of a BlephEX + lid hygiene providing a 80% +/- 20% overall demodex burden reduc-

tion versus a 60% reduction when using lid hygiene alone, while utilizing a two independent sample study with a continuous endpoint, 1:1 enrollment ratio, alpha/beta of 0.05, and power of 95% we have calculated the minimum number of patients needed to enroll as 42 in order to provide statistically significant data. Accounting for a 20% drop out in the study, the number needed to enroll was 50 individuals.

This research protocol gained approval from the institutional review board (Biomedical Research Alliance of New York) and was conducted in accordance with the tenants of the Declaration of Helsinki. The research was not financially sponsored; however, the manufacturer of BlephEx® provided tips for the patients and covered the IRB fee. Subjects were not directly compensated for participation; however, all fees related to a complete ophthalmic examination, testing, and a BlephEx® treatment for all study visits were waived. Additionally, subjects were further incentivized with an optional BlephEx® treatment at the final study visit at no cost.

Patients were recruited from a single cohort of patients in the OCLI Rockville Centre, NY. The inclusion criteria were as follows: (i) study subjects had to be at least 18 years of age or older with the ability to consent for an eye exam, diagnostic testing and non-invasive ophthalmic procedures; (ii) all patients had to have clinical evidence of blepharitis, defined as matted crusts encircling individual cilia on the anterior eyelid margin or telangiectasis and injection of the anterior and posterior eyelid margins with varying degrees of poliosis, madarosis, and trichiasis or MGD, defined as meibomian secretions with increased viscosity or turbidity, atrophy of meibomian gland acini, foam on the tear meniscus along the lower eyelid, or prominent telangiectatic blood vessels on the posterior eyelid margin; and (iii) positive identification of *Demodex folliculorum* confirmed by light microscopy under 10x objective magnification was required on at least one epilated eyelash. Subjects were excluded if they were pregnant, less than 18 years of age, lacked the ability to consent, illiterate, or displayed signs of an active ocular infection.

Following the discussion and receipt of informed consent for participation in research, subjects were enrolled and assigned an ID numbering 1 - 50. IDs were pre-assigned to either the MBE plus lid hygiene group or lid hygiene only group using a randomization table based on block randomization [25].

Subjective evaluation was done at each study visit. Subjects filled out a standard Ocular Surface Disease Index (OSDI) Questionnaire to assess ocular symptoms [26]. Calculated scores range from 0-100 with higher scores indicating greater severity of symptoms.

A Schirmer's 1 test was done by placing a standard paper strip in the inferior fornix of both eyes without topical anesthetic and measuring the length of aqueous tear migration along the paper strip in millimeters after 5 minutes.

Tear osmolarity was measured using the point of care TearLab™ system [TearLab Corporation, San Diego, CA]. A level greater than 308 mOsm/L is considered abnormal [27].

MMP-9 inflammatory marker levels in tears were measured using the point of care Inflammadry® immunoassay test [Quidel Corporation, San Diego, CA].

Meibography was done by infrared imaging of the everted lower lids using the OCULUS Keratograph®5M corneal topographer [OCULUS, Wetzlar, Germany]. The clinician graded the image on a standard scale from 0-4 with a score of 0 indicating 0% meibomian gland dropout, 1 indicating < 25%, 2 indicating 25-50%, 3 indicating 51-75%, and 4 indicating >75% [28].

Following testing, patients were evaluated at the slit lamp. Two different clinicians (MC, HP) performed ophthalmic exams during the study. The presence or absence of eyelid foam was noted. The clinical appearance of the eyelid margin was graded from 0 - 5 with higher scores indicating a greater amount and intensity of blepharitis signs such as and not limited to meibomian gland capping or pouting, lid thickening, telangiectasias, lid erythema, foamy tear film, scalloping of the lid margin, trichiasis or poliosis.

One eyelash from each lid was epilated to determine the level of *D. folliculorum* infestation. Lashes with a significant amount of cylindrical dandruff were targeted for epilation. Lashes were gently pulled while rotating along the base to avoid leaving the cuff of cylindrical dandruff behind on the lid margin and to capture as many organisms as possible from the eyelash root. Each lash was placed on a glass slide labeled and examined under a light microscope; the total amount of live organisms were counted under objective magnification power of 10x, including organisms present on the slide but not contiguous with the lash. In lashes with compact cylindrical

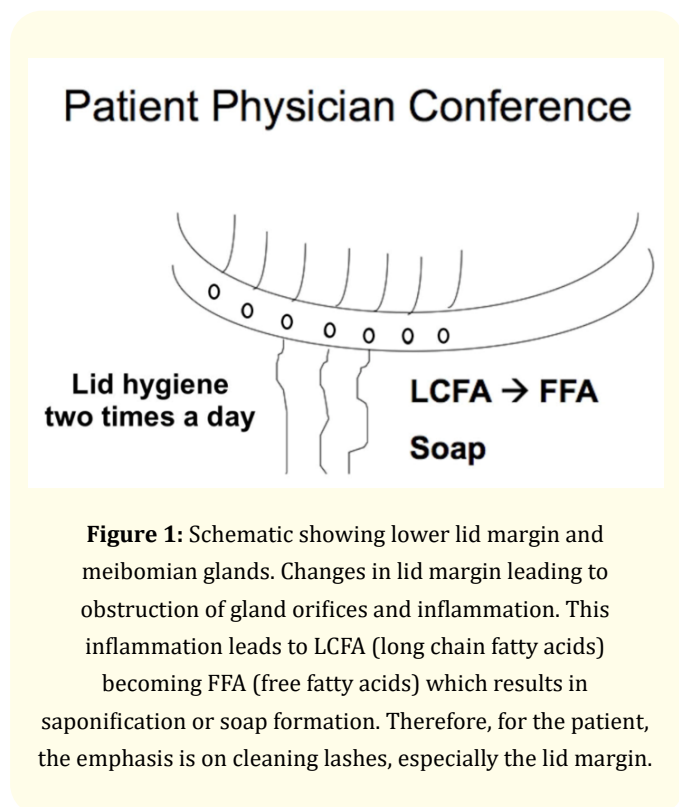
dandruff, a Demodex mite was counted only if a clearly distinct prosoma and opisthosoma were able to be identified within the cylindrical dandruff. For each subject, the total organism counts for all four lids were recorded as right upper, right lower, left upper, left lower.

The ocular surface was then examined with vital dye staining by applying lissamine green. The degree of conjunctival and corneal staining was graded from 0 - 5 using the Oxford scale [29]. The meibomian glands were then expressed with cotton tipped applicators compressing from the internal and external palpebral surfaces. The quality of the expression was graded from 0 - 3: 0 (clear), 1 (cloudy), 2 (granular), 3 (toothpaste). Ease of expression was graded from 1 - 3: 1 (light pressure), 2 (moderate), 3 (heavy).

Following the completion of all testing and the examination, a BlephEx® MBE treatment was given by a certified technician to the subjects randomized to the MBE treatment group. The BlephEx® system was designed to exfoliate the eyelid margin with a rapidly spinning micro-brush to remove the bacterial biofilm,¹³ lid scurf/debris, and *D. folliculorum* mites and eggs. This procedure has been generally termed MBE. A brush with a sponge tip is soaked in LidHygenix® Foam [LidHygenix, Inc, Atlanta, GA], which is an over-the-counter eyelid cleansing foam made with natural ingredients and recommended by BlephEx®, LLC for use with their system. The brush is attached to a rotating electric swivel (2500 rpms) on a handheld device and is swept back and forth along each lid margin for about 1 - 2 minutes. The procedure is completed with four disposable brushes one for each eyelid margin.

Instructions for lid hygiene was explained to the patient via an active diagram and printed instruction sheet [24]. This physician-patient conference served to not only illustrate proper lid hygiene but to foster realization on the patients part that they were at least partially responsible for their outcome. We feel that this conference significantly increases compliance as we encourage questions and carefully go over methodology (Figure 1). All patients in the study were to use lid hygiene for 10 minutes, two times a day [23].

All data collected was processed using the Prism 7 software [GraphPad Software, La Jolla, CA]. For statistical analyses, student's t-tests, Pearsons correlation coefficient, z-score, ANOVA, two-way ANOVA, and chi-squared tests were utilized where appropriate. A p-value of <0.05 was considered significant.



Results

50 patients were enrolled: 25 randomized to receive MBE. The average age of the MBE group was 73.76 years and 70.44 years for the lid hygiene only group. The MBE group was 40% female and 60% male. The lid hygiene only group was 44% female and 56% male. In the MBE group, 1 subject was lost to follow-up prior to the 1-month follow-up visit, leaving 24 subjects included for analysis. The lid hygiene only group had 3 subjects lost to follow-up prior to the 1-month follow-up visit, leaving 22 subjects included for analysis after 1 month.

The average number of Demodex mites in the MBE group and lid hygiene only group at baseline was 5.32 ± 3.21 and 4.08 ± 2.61 , respectively. This difference was not statistically significant ($p = 0.14$). The average change in Demodex levels for the MBE group was a decrease of 3.88 ± 1.31 total organisms per 4 lashes from baseline to month 1. The average change in Demodex levels for the lid hygiene only group was a decrease of 0.04 ± 1.36 total organisms from baseline to month 1. The difference between the two groups was statistically significant ($p < 0.001$). The average change

in NCBUT for the MBE group was an increase of 1.13 ± 2.15 seconds from baseline to month 1. The average change in NCBUT for the lid hygiene only group was an increase of 2.82 ± 5.08 seconds from baseline to month 1. The difference between the two groups was not statistically significant. The average change in lipid layer thickness for the MBE group was an increase of 0.20 ± 4.72 nm from baseline to month 1. The average change in lipid layer thickness for the lid hygiene only group was an increase of 1.18 ± 5.74 nm from baseline to month 1. The difference between the two groups was not statistically significant.

Average OSDI scores in the MBE group were 15.68 ± 5.73 and 14.3 ± 6.06 at baseline and month 1, respectively. There was no statistical significance between values at the different time points. Comparative OSDI scores in the lid hygiene only group were 19.41 ± 6.99 and 13.14 ± 6.0 for baseline and month 1, respectively. There was no statistical significance. Tear osmolarity levels in the MBE group were on average 304.13 ± 7.55 and 294.14 ± 13.39 mOsm/L at baseline and month 1, respectively. Comparative averages in the lid hygiene only group were 298.94 ± 5.8 and 296.14 ± 4.81 mOsm/L, respectively. Again, there was no statistical significance. MMP-9 positivity in the MBE group was 52% and 50% at baseline and month 1, respectively. There was no statistical significance. Comparative rates in the lid hygiene only group were 62% and 57.14%, respectively. Again, there was no statistical significance. Schirmer 1 results in the in the MBE group were on average 10.75 ± 3.54 and 10.41 ± 3.79 mm at baseline and month 1, respectively. Comparative averages in the lid hygiene only group were 11.22 ± 3.05 and 12.81 ± 4.156 mm, respectively. There was no statistical significance.

The presence of a foamy tear film in the MBE group was found in 25% and 21.74% of subjects at baseline and month 1, respectively. Comparative rates in the lid hygiene only group were 20% and 11.36%, respectively. Again, there was no statistical significance. Average modified Oxford scores of lissamine green staining of the conjunctiva in the MBE group were 1.05 ± 0.40 and 0.90 ± 0.38 at baseline and month 1, respectively. There was no statistical significance between values at the different time points. Comparative averages in the lid hygiene only group were 0.98 ± 0.39 and 1.07 ± 0.43 , respectively. There was no statistical significance. Average modified Oxford scores of lissamine green staining of the cornea in the MBE group were 0.48 ± 0.32 , and 0.35 ± 0.27 at base-

line and month 1, respectively. There was no statistical significance between values at the different time points. Comparative averages in the lid hygiene only group were 0.32 ± 0.30 and 0.45 ± 0.31 , respectively. There was no statistical significance. Meibomian gland dropout scores graded on infrared meibography in the MBE group were on average 1.98 ± 0.28 and 1.82 ± 0.32 at baseline and month 1, respectively. There was no statistical significance between values at the different time points. Comparative average scores in the lid hygiene only group were 2.07 ± 0.33 and 1.85 ± 0.27 , respectively. There was no statistical significance. For the whole sample, the average number of Demodex mites on the upper and lower lashes at baseline was 3.24 ± 2.08 and 1.46 ± 1.54 mites, respectively. This difference was statistically significant ($p < 0.001$). The average number of Demodex mites on the upper and lower lashes at month 1 was 1.82 ± 1.93 and 0.86 ± 1.14 mites, respectively. This difference was statistically significant ($p < 0.01$).

Differences between the patients in the two arms of the study were analyzed by appropriate statistical methods. Correlations between demographics as well as overall demodex numbers, as well as ocular lid characteristics were assessed using the χ^2 -test, student's t-test, and the Z-test. For independent samples either the t-test or the Mann-Whitney-U test was used for interval data depending on the outcome of the Kolmogorov-Smirnov test for normality of distribution. Nominal data was analyzed using either the χ^2 -test test or the Mann-Whitney-U test, again based on the outcome of the Kolmogorov-Smirnov test for normality of distribution. P-values less than or equal to 0.05 were considered statistically significant.

Discussion

The pathophysiologic rationale for the use of MBE treatment of Demodex blepharitis, centers on the dry eye blepharitis (DEBS) unification theory by Rynerson, *et al.* that the proliferation of bacterial biofilm on the eyelid margin leads to chronic blepharitis [15]. In this study, the group receiving MBE treatment showed a significantly greater decrease in the number of Demodex mites found on eyelash samples.

Closer inspection of the lifecycle of *Demodex folliculorum* may help elucidate the mechanism by which MBE decreases Demodex infestation. Demodex are thought to have a life cycle between 14 and 21 days [30]. Demodex eggs are deposited on the eyelashes

and within the follicle. Demodex larvae emerge from the eggs and at this stage of development, have no means to grip the eyelash follicles [31]. The larvae then develop into six-legged nymphs. From this stage, the nymphs become sexually mature adults, which have eight short articulated legs that are able to grip eyelashes and also hard exoskeleton [32]. Adults clump in groups around the eyelash base and copulate [33]. The females then deposit the eggs on the eyelashes. The adults die, leaving the carcass coagulating around the eyelash, possibly contributing to the collarettes and cylindrical dandruff formed around eyelash follicles seen in Demodex blepharitis [34]. During their lifecycle, it is thought that Demodex feed on sebum and possibly keratin from the host skin. Additionally, some have proposed that Demodex graze on the plentiful bacteria and bacterial biofilm found in the eyelash microflora [35].

After consideration of the lifecycle of the Demodex mite, several possible mechanisms for the efficacy of MBE in the removal of Demodex are apparent. The eggs are deposited on the eyelash follicle and may be brushed off the lash ending the lifecycle before it begins. Demodex nymphs lack the rotating, articulated legs that adults have to grip onto the human eyelash and may be easily wiped away by MBE. It is unclear whether the spinning brush of MBE are powerful enough to uproot an adult Demodex mite anchored on an eyelash. It is also unclear why the number of Demodex were higher on the upper lids than the lower lids both at baseline and at month 1. It is possible that Demodex on the upper lids are more securely entrenched. MBE may attack adult Demodex mites in a more insidious way: by removing the food source of biofilm and bacteria. Finally, the LidHygenix® Foam itself may limit proliferation of Demodex mites or kill them outright. It is unclear by which of these mechanisms MBE is able to effectively decrease Demodex infestation, possibly a combination of all four.

Interestingly, the interaction of Demodex mites, bacterial biofilm, and MBE and its impact on blepharitis remains to be elucidated. If Demodex mites graze on bacteria and the biofilm, one could hypothesize that Demodex infestation actually decreases biofilm accumulation and bacterial load on the eyelid margin. In fact, some authors have observed an initial worsening of symptoms of blepharitis following starting treatment for Demodex and have advocated restoration of the normal ocular flora ecological balance as opposed to complete eradication of Demodex [35].

NIBUT was decreased in both groups. This suggests that lid hygiene is critical for improving the function of Meibomian glands in the treatment of blepharitis [23]. MBE appears to also have a positive effect in the improvement of NIBUT, possibly by the removal of accumulated biofilm at the eyelid margin and Meibomian gland orifices. OSDI scores, lipid layer thickness, and other clinical examination measures did not appear to correlate with Demodex levels. This finding reflects similar findings in other studies on blepharitis as a lack of correlation between symptoms and exam findings has been demonstrated previously [5].

Treatment of Demodex blepharitis has previously centered around the use of compounds toxic to the survival of Demodex including, tea tree oil, ivermectin, or metronidazole, with varying levels of success [20-22]. MBE provides a novel mechanism for the treatment of Demodex by possibly physically removing the mites and their food source from the eyelash. Additional studies are needed to further define the mechanisms by which MBE decrease Demodex infestation and to establish clinical correlates between patient symptomatology and exam findings.

Conclusion

This study showed that both lid hygiene plus an in-office MBE procedure (BlephEx® and lid hygiene alone decreased the amount of *Demodex* with the group receiving MBE showing greater efficacy ($p < 0.001$). MBE may have a positive role in the treatment of *Demodex* blepharitis and provides clinicians with a novel mechanism to treat this chronic disease.

Disclosures

IRB fee provided by BlephEx LLC.

Henry D. Perry, Eric D. Donnenfeld - Declarations of interest: Advisory Board for BlephEx®.

Michael B. Choi, Ilan Epstein, Ross Stuber, Eric Rosenberg – Declarations of interest: none.

Bibliography

- Amescua G., et al. "Blepharitis Preferred Practice Pattern®". *Ophthalmology* 126 (2019): P56.
- Lemp MA and Nichols KK. "Blepharitis in the United States 2009: a survey-based perspective on prevalence and treatment". *The Ocular Surface* 7 (2009): S1-S14.
- Craig JP, et al. "TFOS DEWS II report executive summary". *The Ocular Surface* (2017).
- Nichols KK, et al. "The international workshop on meibomian gland dysfunction: executive summary". *Investigative Ophthalmology and Visual Science* 52 (2011): 1922-1929.
- Dougherty JM and McCulley JP. "Analysis of the free fatty acid component of meibomian secretions in chronic blepharitis". *Investigative Ophthalmology and Visual Science* 27 (1986): 52-56.
- Dougherty JM and McCulley JP. "Bacterial lipases and chronic blepharitis". *Investigative Ophthalmology and Visual Science* 27 (1986): 486-491.
- McCulley JP and Shine WE. "Meibomian secretions in chronic blepharitis". *Lacrimal Gland, Tear Film, and Dry Eye Syndromes 2*: Springer (1998): 319-26.
- Jester J, et al. "Meibomian gland dysfunction. II. The role of keratinization in a rabbit model of MGD". *Investigative Ophthalmology and Visual Science* 30 (1989): 936-945.
- Jester J, et al. "Meibomian gland dysfunction. I. Keratin protein expression in normal human and rabbit meibomian glands". *Investigative Ophthalmology and Visual Science* 30 (1989): 927-935.
- Shimazaki J, et al. "Ocular surface changes and discomfort in patients with meibomian gland dysfunction". *Archives of ophthalmology* 113 (1995): 1266-1270.
- Schaumberg DA, et al. "The international workshop on meibomian gland dysfunction: report of the subcommittee on the epidemiology of, and associated risk factors for, MGD". *Investigative Ophthalmology and Visual Science* 52 (2011): 1994-2005.
- Dougherty JM and McCulley JP. "Comparative bacteriology of chronic blepharitis". *British Journal of Ophthalmology* 68 (1984): 524-528.
- McCulley JP. "Blepharoconjunctivitis". *International Ophthalmology Clinics* 24 (1984): 65-77.
- Ficker L, et al. "Role of cell-mediated immunity to staphylococci in blepharitis". *American Journal of Ophthalmology* 111 (1991): 473-479.

15. Rynerson JM and Perry HD. "DEBS—a unification theory for dry eye and blepharitis". *Clinical ophthalmology* (Auckland, NZ) 10 (2016): 2455.
16. Lemp MA, et al. "Association of rosacea and keratoconjunctivitis sicca". *Archives of Ophthalmology* 102 (1984): 556-557.
17. McCulley JP, et al. "Classification of chronic blepharitis". *Ophthalmology* 89 (1982): 1173-1180.
18. Czepita D, et al. "Demodex folliculorum and Demodex brevis as a cause of chronic marginal blepharitis". *Annales Academiae Medicae Stetinensis* (2007).
19. Gao Y-Y, et al. "High prevalence of Demodex in eyelashes with cylindrical dandruff". *Investigative Ophthalmology and Visual Science* 46 (2005): 3089-3094.
20. Tighe S, et al. "Terpinen-4-ol is the most active ingredient of tea tree oil to kill Demodex mites". *Translational Vision Science and Technology* 2 (2013): 2.
21. Holzchuh FG, et al. "Clinical treatment of ocular Demodex folliculorum by systemic ivermectin". *American Journal of Ophthalmology* 151 (2011): 1030-1034. e1.
22. Salem DA-B, et al. "Evaluation of the efficacy of oral ivermectin in comparison with ivermectin–metronidazole combined therapy in the treatment of ocular and skin lesions of Demodex folliculorum". *International Journal of Infectious Diseases* 17 (2013): e343-e347.
23. Lindsley K, et al. "Interventions for chronic blepharitis". *The Cochrane Database of Systematic Reviews* 5 (2012): CD005556.
24. Romero JM, et al. "Conservative treatment of meibomian gland dysfunction". *Eye and Contact Lens* 30 (2004): 14-19.
25. Efid J. "Blocked randomization with randomly selected block sizes". *International journal of Environmental Research and Public Health* 8 (2010): 15-20.
26. Miller KL, et al. "Minimal clinically important difference for the ocular surface disease index". *Archives of Ophthalmology* 128 (2010): 94-101.
27. Foulks GN, et al. "TearLab™ osmolarity as a biomarker for disease severity in mild to moderate dry eye disease". *American Academy of Ophthalmology* (2009): P0382.
28. Pult H and Riede-Pult B. "Comparison of subjective grading and objective assessment in meibography". *Contact Lens and Anterior Eye* 36 (2013): 22-27.
29. Bron AJ, et al. "Grading of corneal and conjunctival staining in the context of other dry eye tests". *Cornea* 22 (2003): 640-650.
30. Spickett S. "Studies on Demodex folliculorum simon (1842). I. Life history". *Parasitology* 51 (1961): 181-192.
31. Lacey N, et al. "Under the lash: Demodex mites in human diseases". *The Biochemist* 31 (2009): 2.
32. Lacey N, et al. "Demodex mites-commensals, parasites or mutualistic organisms?" *Dermatology* 222 (2011): 128.
33. Lee SH, et al. "The relationship between demodex and ocular discomfort". *Investigative Ophthalmology and Visual Science* 51 (2010): 2906-2911.
34. Rufli T and Mumcuoglu Y. "The hair follicle mites Demodex folliculorum and Demodex brevis: biology and medical importance". *Dermatologica* 162 (1981): 1-11.
35. Nicholls SG, et al. "Demodex species in human ocular disease: new clinicopathological aspects". *International Ophthalmology* 37 (2017): 303-312.

Assets from publication with us

- Prompt Acknowledgement after receiving the article
- Thorough Double blinded peer review
- Rapid Publication
- Issue of Publication Certificate
- High visibility of your Published work

Website: www.actascientific.com/

Submit Article: www.actascientific.com/submission.php

Email us: editor@actascientific.com

Contact us: +91 9182824667