

## Management of Retinal Detachment in Choroideremia

Ali M Al-Halafi<sup>1</sup> and Shaaban Abd-Elhamid Mehany Elwan<sup>1,2\*</sup>

<sup>1</sup>Ophthalmology Department, Security Forces Hospital, Riyadh, Kingdom of Saudi Arabia

<sup>2</sup>Ophthalmology Department, Faculty of Medicine, Minia University, El-Minia, Egypt

**\*Corresponding Author:** Shaaban A M Elwan, Ophthalmology Department, Security Forces Hospital, Riyadh, Kingdom of Saudi Arabia and Faculty of Medicine, Minia University, El-Minia, Egypt.

**Received:** March 21, 2019; **Published:** April 26, 2019

### Abstract

**Purpose:** To report the management of retinal detachment (RD) in a male of choroideremia (CHM) with severe visual symptoms and extensive fundus mottling.

**Setting:** Security Forces Hospital, Ophthalmology Department, Riyadh, Kingdom of Saudi Arabia.

**Design:** Case report presentation.

**Observation:** This was an observational case report study. A symptomatic 34 years old Saudi male with a history of binocular CHM presented by a decrease of vision in the right eye for the last 3 weeks. He underwent routine ocular examination and review of his clinical and photographic records, optical coherence tomography (OCT). Dilated fundus examination showed a diffuse mottling with retinal detachment involving the macula with superotemporal retinal break of the right eye. Left eye showed large irregular and confluent patches of RPE atrophy in the peripapillary and parapapillary areas as well as the midperiphery and flat retina. The surgery for RD of the right eye was discussed with the patient with pros and cons. Pars Plana Vitrectomy (PPV) was done with endolaser and silicone oil injection. The second day, the vision was CF Normal IOP and the retina was flat under silicone oil. After 3 weeks, the patient came for follow up with recurrent RD involving the macula. A second surgery with cryopexy instead of endolaser was planned and it was done. The second day, the retina was flat under silicone oil and the vision was 3/60. Six months, postoperatively, the retina still flat.

**Conclusion:** Retinal cryopexy in RD of CHM may be the first option instead of laser retinopexy because of RPE pathology and difficulty in laser uptake.

**Keywords:** Choroideremia; Retinal Detachment; Blood Retinal Barrier; Cryopexy

### Introduction

Choroideremia (CHM) is a recessive X-linked chorioretinal dystrophy due to mutation in the CHM Xq21 gene which encodes the protein REP-1. The condition is a progressive, diffuse degeneration of the choroid, retinal pigment epithelium (RPE) and photoreceptors. Symptoms include bilateral nyctalopia in childhood followed by annular scotomas leading to concentric visual field loss and impairment of visual acuity, color vision and stereopsis by mid-adulthood, specifically in males. Fundus changes are observed

as non-specific pigmentary stippling and focal areas of choroidal atrophy in the mid-periphery. With degenerative changes of the RPE, window defects showing remnants of the choroidal vasculature become apparent in peripapillary areas and macula. As the disease advances, the sclera becomes visible on fundus examination in the areas of complete choroidal and retinal atrophy [1]. Retinal detachment is a common presentation of CHM due to chorioretinal atrophy and the controversies either to use LAER photocoagulation or cryopexy with retinal detachment surgery

due to RPE atrophy. In 1933, Bietti reported the use of cryogenics to produce a thermal chorioretinitis to seal a retinal hole. He used a metal probe, pre-cooled in a mixture of carbon dioxide and acetone, with application of the probe to the outer wall of the eye overlying the retinal hole [2]. Then, Deutschmann used cryosurgery in the form of solid carbon dioxide probes applied in the same fashion to treat retinal detachments [3]. Schepens, Lincoff, and others were key figures in the advancement of cryoretinopexy surgical techniques and in using cryoretinopexy with scleral buckling for retinal detachments [4-6]. Application of a cryo probe to the sclera for 5 seconds was shown to create a white area in the underlying retina and seal retinal tears and holes [3,5]. The mechanisms of cryotherapy are complex. One hypothesis is direct cellular injury from the extracellular space. The cell injury that occurs after freezing is thought to result from a high solute concentration causing cell dehydration [7]. Intracellular ice formation causing intracellular organelle and cell membrane disruption has also been implicated [8]. Another theory is that freezing may stimulate immunological injury. It is believed that the immune system becomes sensitized to the destroyed frozen tissue, and any tissue left behind is attacked by the host's own immune system after cryosurgery. However, the relevance of immunological injury is still controversial [9]. Finally, it has been theorized that freezing involves vascular injury [10]. The hypothesis is that freezing results in stasis of blood flow, particularly in the capillaries. The resulting ischemia leads to tissue necrosis. In contrast the mechanism of action of LASER retinal photocoagulation, where in light energy is converted to heat at the level of the RPE leading to protein denaturation, scarring and burns at the level of the RPE and photoreceptors. Another theory is that RPE activation following photocoagulation injury leads to cytokine production and reduction of VEGF [11].

### Differential diagnosis

CHM could be misdiagnosed as X-linked retinitis pigmentosa (XLRP), Usher syndrome type 1, Kearns-Sayre syndrome (KSS) and gyrate atrophy of the retina and choroid. The clinical manifestation and early fundus appearance of CHM resembles XLRP that also presents with nyctalopia, peripheral visual fields restrictions with greater amount of pigment migration. CHM carriers have typical patchy appearances while XLRP have bone spicules in the retinal periphery. Usher syndrome type 1, which manifests with congenital bilateral hearing loss and adolescent onset RP, could be confused with the clinical manifestations of small deletions

association of CHM. In spite of the clinical similarities, Usher syndrome is not associated with the mosaic fundus appearance seen in CHM female carriers. KSS is caused by a mitochondrial DNA deletion and presents as a triad of pigmentary retinopathy, progressive external ophthalmoplegia and onset prior to 20 years old. Fundus appearance in KSS resembles that of end-stage CHM and is characterized by severe degeneration of the choroids, RPE and retina. Finally, gyrate atrophy, which is caused by autosomal recessive mutation in the ornithine aminotransferase gene, is associated with elevated plasma concentration of ornithine. Its ophthalmoscopy findings are probably the most frequently confused with those of choroideremia but elevated levels of plasma ornithine can differentiate the two [12].

### Pathogenesis


While the biochemical and genetic abnormalities are well understood in CHM, the consequent pathogenesis of the disease remains unclear. It is still unknown whether the degeneration of retina, RPE and choroid occur independently or sequentially. Theories include degeneration of rod photoreceptors followed by degeneration of the choroid or primary RPE degeneration [13-15]. There are presently four different hypotheses. The first postulates that abnormalities in RPE result in the simultaneous degeneration of the choroid and the photoreceptors layer [16]. The second state that the RPE and photoreceptor layers degenerate independently and the choroidal degeneration being secondary to that of the RPE [17]. The third hypothesis asserts that the photoreceptors, specifically, the rods, are the primary source of degeneration [14]. In the fourth hypothesis, the choroid is the first to degenerate resulting in secondary loss of the RPE and photoreceptors [18].

### Case Report


#### Presentation

Saudi male symptomatic patient aged 34 years complaining of drop of vision of right eye over three weeks with history of night vision problems from an early age and wearing glasses for myopic correction to see details during school. However, his central vision began reducing when he was at university and has gradual progression of his central and peripheral vision. At presentation the patient complain of floaters, flashing of lights, and a shadow or curtain like in front progress toward the center of his vision. His visual Acuity was hand Motion (HM) in the right eye and 6/60 in the left eye. No

peripheral field for confrontation test. Dilated funduscopy revealed a diffuse mottling with retinal detachment involving the macula with superotemporal retinal break of the right eye. Left eye showed large irregular and confluent patches of RPE atrophy and retinal degenerations in the peripapillary and parapapillary areas as well as the midperiphery and flat retina documented with imaging (Figure 1A and 1B). Optical coherence tomography (OCT) was done and demonstrated RPE irregularities with attenuation more prominent outside the macular region.



**Figure 1A:** OD, Preoperative RD.



**Figure 1B:** OS, Preoperative CHM picture.

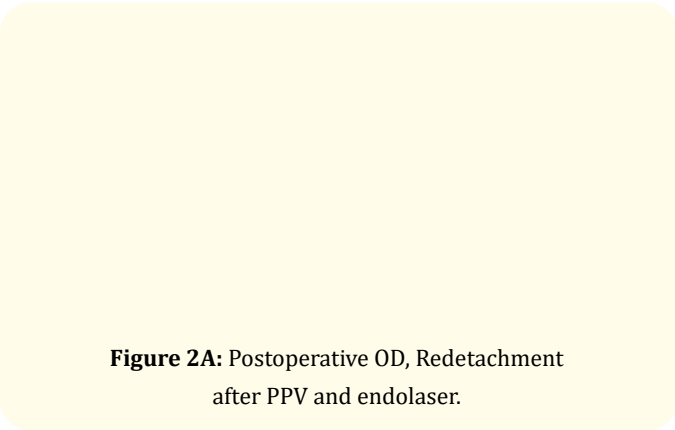
### Family history

His parents were distantly related and unaffected by the disorder but, he has five sisters and two brothers. Both of brothers are affected with the same disorder, one of his brothers is married to a first cousin and two of his children daughters have recently been diagnosed with similar disorder. This finding arose our attention for autosomal recessive inheritance disorder and for future treatment including gene therapy like as Adeno-Associated

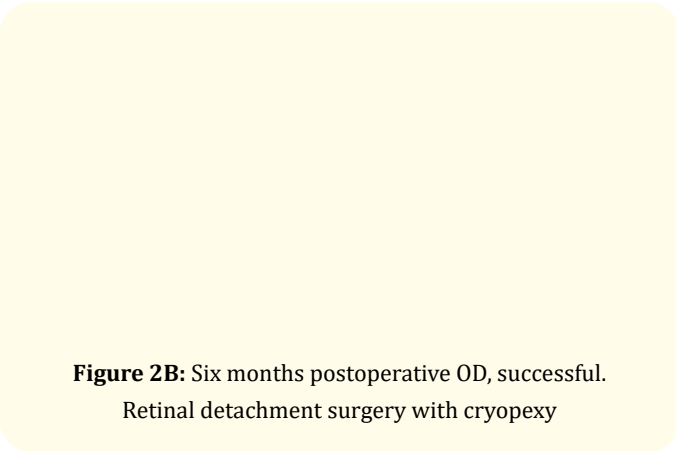
Viral Vector (AAV2) Encoding Rab Escort Protein 1 (REP1) or retinal implant, cell transplantation and genetic counseling were discussed with the patient.

### Surgery

The surgery for RD of the right eye was discussed with the patient with pros and cons and the patient signed informed consent. Pars Plana Vasectomy (PPV) was done with endolaser and silicone oil injection. The second postoperative day the patient doing well and the right eye vision was counting fingers (CF), Normal IOP and the retina was flat under silicone oil. After 3 weeks, the patient came for follow up with recurrent retinal detachment (RD) involving the macula (Figure 2A). A second surgery with cryopexy instead of endolaser was planned and it was done. The second day, the retina was flat under silicone oil. Six months, postoperatively, the retina still flat and there is no proliferative vitreoretinopathy (PVR) (Figure 2B).



**Figure 2A:** Postoperative OD, Redetachment after PPV and endolaser.



**Figure 2B:** Six months postoperative OD, successful. Retinal detachment surgery with cryopexy

### Genetic counseling

Testing for gene mutations in CHM has become available on a fee-for-service basis in a number of laboratories. With an X-linked mode of inheritance, carrier mothers transmit the disease-causing mutation to 50% of their offspring. Affected males transmit the mutation to their female offspring only, who then are all obligate carriers. Theoretically, in all cases in which a mutation has been identified, family planning, DNA banking and prenatal testing could be undertaken. Prenatal testing is based on DNA analysis of fetal cells extracted by chorionic villus sampling (at 10–12 weeks gestation) or amniocentesis (at 15–18 weeks gestation). Genetic testing and patient's DNA sample was sent to Central Manchester University Hospital to be screened at Manchester Center for Genomic Medicine and the results was documented in a retinal dystrophy mutation analysis report CHM c 1144G >TP (Glu 382 Ter) Hemizygous.

### Discussion

Choroideremia is a recessive X-linked disease that primarily affects males. Female carriers are often asymptomatic and the fundus may show the presence of pigmentary mottling. Choroideremia is characterized by progressive vision loss that mainly affects males. The first symptom of this condition is usually an impairment of night vision (night blindness) or nyctalopia, which can occur in early childhood. A progressive narrowing of the field of vision (tunnel vision) follows, as well as a decrease in the ability to see details (visual acuity). These vision problems are due to the atrophy in the retinal pigment epithelium (RPE) and photoreceptors [19]. The rod amplitude responses have been found to be generally reduced in affected males with minimally prolonged rod implicit times while cone amplitudes are initially normal or reduced [20]. In female carriers, ERG amplitudes have been found to be abnormal in only 15% of cases [14]. The nearby network of blood vessels (the choroid) shown atrophy also. The vision impairment in choroideremia worsens over time, but the progression varies among affected individuals. However, all individuals with this condition will develop blindness, most commonly in late adulthood. The prevalence of choroideremia is estimated to be 1 in 50,000 to 100,000 people. However, it is likely that this condition is under diagnosed because of its similarities to other eye disorders. Choroideremia is thought to account for approximately 4 percent of all blindness. Mutations in the CHM gene

cause choroideremia. The CHM gene provides instructions for producing the Rab escort protein-1 (REP-1). As an escort protein, a REP-1 attached to molecules called Rab proteins within the cell and directs them to the membranes of various cell compartments. Rab proteins are involved in the movement of proteins and organelles within cells (intracellular trafficking). Mutations in the CHM gene lead to an absence of REP-1 protein or the production of a REP-1 protein that cannot carry out its protein escort function. This lack of functional REP-1 prevents Rab proteins from reaching and attaching (binding) to the organelle membranes. Without the aid of Rab proteins in intracellular trafficking, cells die prematurely. The REP-1 protein is active (expressed) throughout the body, as is a similar protein, REP-2. Research suggests that when REP-1 is absent or nonfunctional, REP-2 can perform the protein escort duties of REP-1 in many of the body's tissues. Unfortunately, very little REP-2 protein is present in the retina, however, it cannot compensate for the loss of REP-1 in this tissue. Loss of REP-1 function and subsequent misplacement of Rab proteins within the cells of the retina resulting in the progressive degeneration of choriocapillaris, retinal pigment epithelium (RPE), and photoreceptors and thus the progressive vision loss characteristic of choroideremia and possible retinal detachment like what happened with our case.

In our case retinal cryopexy was the preferable choice after failure of the first attempt or reattachment using endolaser perhaps due to retinal and choroidal atrophy. It was administered under local anesthesia and the procedure involves placing a metal probe against the eye. When a foot pedal is depressed, the tip of the cryopexy probe becomes very cold as a result of the rapid expansion of very cold gases (nitrous oxide) within the probe tip. When the probe is placed on the eye the formation of ice crystals followed by rapid thawing results in tissue destruction around the retinal tear. This is followed by healing and scar tissue formation and sealing the edges of the retinal tear. This is typically done by looking into the eye while pushing gently on the outside of the eye using the cryopexy probe, producing a small area of freezing that involves the retina and the tissues immediately underneath it. Using multiple small freezes, the retinal tear was surrounded. The irritated tissue forms a scar, which brings the retina back into contact with the tissue underneath it and successful sealing of the retinal break was obtained in contrast to study of Peter, *et al.* [21] stated that cryopexy enhances dispersion of viable retinal pigment epithelium

in vitreous cavity encouraging proliferative vitreoretinopathy and also study of Edward, *et al.* [22] that concluded breakdown of blood retinal barrier (BRB) with cryotherapy in retinal detachment surgery. It does not happen in our case after 6 months follow up may be due to marked deficiency of RPE and atrophic features of choroideremia.

### Conclusion

This case report presentation emphasized that retinal cryopexy in RD of CHM patients induces a therapeutic effect and may be the first option instead of laser retinopexy because of RPE pathology and difficulty in laser uptake.

### Conflicts of Interests

The authors declare that they didn't have either conflicts of interests or financial interests and support, as well as this data have not been published before.

### Bibliography

1. IM MacDonald, *et al.* "Choroideremia". *Gene Reviews* (2015).
2. G Bietti. "Ricerche Sulle Variazione di Temperature di Alcune Zone del Bulbo Oculare per Diatermocoagulazioni Episclerali, Termocauterizzazioni e Criocausticazioni". *Bollettino d'Oculistica* 12 (1933): 1427- 1457.
3. R Deutschmann. "Die Behandlung der Netzhautablosung mit Jodtinkur und Kohlensaureschnee". *Klin Monatsbl Augenh* 94 (1935): 349.
4. JG Bellows. "Cryotherapy of Ocular Disease". JB Lippincott Co., Philadelphia (1966).
5. HA Lincoff, *et al.* "Cryosurgical Treatment of Retinal Detachment. Transactions". *American Academy of Ophthalmology and Otolaryngology* 68 (1964): 412-432.
6. CL Schepens, *et al.* "The Scleral Buckling Procedures. I. Surgical Techniques and Management". *Archives of Ophthalmology* 58.6 (1957): 797-811.
7. Lovelock JE. "The haemolysis of human red blood-cells by freezing and thawing". *Biochimica et Biophysica Acta* 10 (1953): 414-426.
8. Steponkus PL. "Role of the plasma membrane in freezing injury and cold acclimation". *Annual Review of Plant Biology* 35 (1984): 543-584.
9. Hoffmann NE, *et al.* "Investigation of the mechanism and the effect of cryoimmunology in the Copenhagen rat". *Cryobiology* 42 (2001): 59-68.
10. Fraser J and Gill W. "Observations on ultra-frozen tissue". *British Journal of Surgery* 54 (1967): 770- 776.
11. Friberg TR. "Laser photocoagulation to produce chorioretinal adhesion". Paper presented at second international conference on Pneumatic Retinopexy, Tampa, FL (1989).
12. RG Coussa and EI Traboulsi. "Choroideremia: a review of general findings and pathogenesis". *Ophthalmic Genet* 33 (2012) 57-65.
13. M. Mura, *et al.* "Clinical and functional findings in choroideremia due to complete deletion of the CHM gene". *Archives of Ophthalmology* 125 (2007): 1107-1113.
14. Syed N, *et al.* "Evaluation of retinal photoreceptors and pigment epithelium in a female carrier of choroideremia". *Ophthalmology* 108.4 (2001) 711-720.
15. JIW Morgan, *et al.* "High-resolution adaptive optics retinal imaging of cellular structure in choroideremia, Invest. *Investigative Ophthalmology and Visual Science* 55 (2014) 6381-6397.
16. Flannery JG, *et al.* "A histopathological study of a choroideremia carrier". *Investigative Ophthalmology and Visual Science* 31 (1990) 229-236.
17. Tolmachova T, *et al.* "Independent degeneration of photoreceptors and retinal pigment epithelium in conditional knockout mouse models of choroideremia". *Journal of Clinical Investigation* 116 (2006) 386-394.
18. McCulloch JC. "The pathologic findings in two cases of choroideremia". *American Academy of Ophthalmology and Otolaryngology* 56 (1950): 565-572.
19. Roberts MF, *et al.* "Retrospective longitudinal, and cross sectional study of visual acuity impairment in choroideraemia". *British Journal of Ophthalmology* 86 (2002): 658-662.

20. PA Sieving, *et al.* "Electroretinographic findings in selected pedigrees with choroideremia". *American Journal of Ophthalmology* 101(1986): 361- 367.
21. Peter A., *et al.* "Cryotherapy enhances intravitreal dispersion of viable retinal pigment epithelial cells". *Archives of Ophthalmology* 103.3 (1985): 434-436.
22. Edward H., *et al.* "Cryotherapy causes extensive breakdown of the blood retinal barrier: A comparison with argon laser photocoagulation". *Archives of Ophthalmology* 103.11 (1985): 1728-1730.

**Volume 2 Issue 4 May 2019**

**© All rights are reserved by Ali M Al-Halafi and  
Shaaban Abd-Elhamid Mehany Elwan.**