

## Strontium Beta-Irradiation: Can it Prove Strong Enough in Curbing the Ophthalmic Hydra Called Pterygium

Abhishek Onkar<sup>1\*</sup>, Saurabh Samdariya<sup>2</sup>, Puneet Pareek<sup>2</sup> and Suvarna Suman<sup>1</sup>

<sup>1</sup>Department of Ophthalmology, AIIMS Jodhpur, India

<sup>2</sup>Department of Radiation Oncology, AIIMS Jodhpur, India

\*Corresponding Author: Abhishek Onkar, Department of Ophthalmology, AIIMS Jodhpur, India.

Received: April 27, 2017; Published: May 03, 2017

### Abstract

No other ophthalmic disorder, or may be any medical disorder, has elicited so much interest as pterygium. Even though eons have passed since it was first discovered, its propensity for regrowth like tentacles of hydra, continue to perplex the ophthalmic community. Its propensity for recurrences has attracted all and the sundry and newer modalities are being propounded to prevent recurrences. This article reviews the role of radiation therapy for recurrence prevention in pterygium management.

**Keywords:** Pterygium; Ophthalmic; Metalloproteinases

Etymologically derived from the Greek word 'pterygion' meaning small wing, pterygium has been in vogue since the times of Sushruta (6th century B.C.). It is a triangular, wing-like fibro-vascular encroachment of degenerative sub-epithelial conjunctiva, straddling the limbus, onto the cornea.

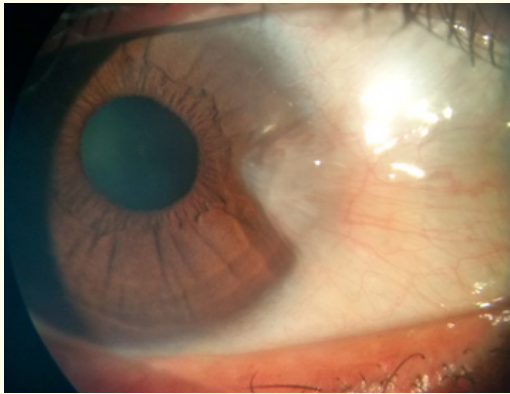


Figure 1: Pterygium in a 17-Year-Old Male.

Pterygium, with a prevalence of 0.3 to 29%, is common in the 'pterygium belt' lying 37° on either side of equator [1,2]. Chronic exposure to ultra-violet B radiations, limbal stem cell deficiency, human papilloma virus infection, p53 gene mutations and imbalance of matrix metalloproteinases (MMP) and tissue inhibitors of metalloproteinases (TIMP) have been strongly implicated in pterygium causation [3].

Whereas diagnosis and management of primary pterygium is an iotic task, managing recurrences is a titanic one.

While primary pterygium excision with conjunctival graft remains the standard procedure for prevention of recurrences with recurrence rate of 2 - 35%, many other methodologies have been used with varying degree of success. Intra-operative and post-operative mitomycin-C (0.01 - 0.04%) with recurrence rate of 3 - 38% is another very commonly used modality [4,5].

Intra-operative Dauxorubicin (0.02%), daunorubicin (0.02%), cyclosporine A (0.1%) eye-drops, thiotepa (0.05%) eye-drops and 5-fluoro-uracil (5%) are the other medical options shown to have promising results in recurrence prevention in various studies. Off-late, sub-conjunctival anti-VEGF Bevacizumab (1.25 - 2 mg) therapy has also been proposed for the aforesaid. All these agents are associated with risk of serious complications like scleral perforations, scleritis, scleral necrosis, and endophthalmitis.

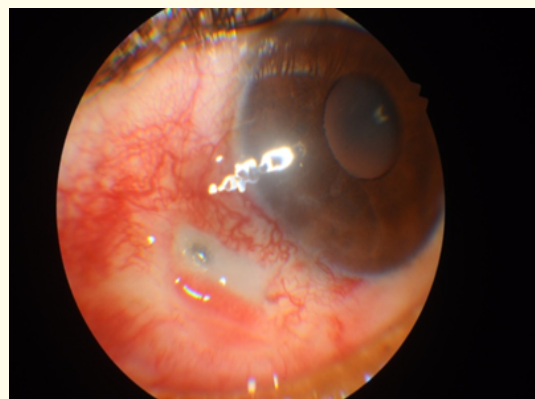
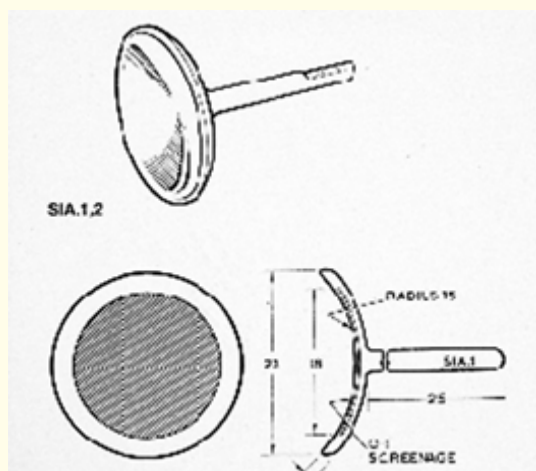


Figure 2: Scleral Perforation Secondary to Mitomycin-C Application Intra-Operatively.

### Role of beta Beta-irradiation

The standard technique is a strontium (Sr90) brachytherapy with an epibulbar plaque which has central radioactive disc and non-active rim of 2 mm.



**Figure 3:** SR-90 Epibulbar Applicator.

A total dose of 25 - 60 Gy is to be delivered in 1 - 6 fractions at a rate of 5 - 20 Gy/min. Most commonly, a dose of 30 Gy is delivered in 3 weekly fractions of 10 Gy with the first application being administered intra-operatively, or at least within 48 hours after surgery.

Regimes of beta-irradiation advocated for recurrence prevention are:

- single application of beta-irradiation
- multiple applications over consecutive days immediately in post-op period.
- multiple applications over a 2-week period.

A literature review by Ali, *et al.* (2011) of 6000 lesions treated post-operatively with beta irradiation reported an over-all recurrence rate of 15% with very few side-effects. Another 10-year review of 104 eyes done by Qin, *et al.* (2012), treated similarly, reported nil recurrence but cataract development in 5 eyes [6,7].

Cumbersome instrumentation and inconvenience of arranging its treatment account for the limited utility of this modality although the recurrence rates are comparable to post-operative mitomycin-C application [8].

Conjunctival auto-grafting and mitomycin-C are being used by all and the sundry, undermining the role of beta radiation. Though conjunctival autografting is considered the safest and most effective, it is time consuming. Time factor becomes very pertinent in developing countries where patient to ophthalmologist ratio is negatively skewed, incidence of pterygium is high and potentially blinding diseases account for the bulk of surgical time. Comparative data for beta radiation and mitomycin C are conflicting with

one study (Amano, *et al.*) suggesting superiority of mitomycin- C while others (Snibson, *et al.* and Simsek, *et al.*) giving verdict in favour of beta irradiation [9-12].

Pterygium surgery has infallibly evolved over the years. Still the quest for an ideal recurrence free modality of pterygium management remains evasive and futile. This highlights the need to have a better understanding of the aetio-pathogenesis of pterygium as well as its recurrence. Also, treatment plan should be customized for each case rather than blindly following a single technique. Ironically, though 'pterygium' means a 'small wing', over the centuries its wings have expanded beyond our understanding and imagination. This triangular enigma can truly be called the 'Bermuda triangle' of ophthalmology as it continues to baffle us all. The exhaustive review studies by Ali, *et al.* and Qin, *et al.* definitely prove the validity and utility of beta irradiation. A concerted effort on our part is required to solve this mystery and based on the encouraging reports of the studies by Snibson, *et al.* and Simsek, *et al.* Beta irradiation could well prove to be the guiding light.

### Bibliography

1. Cameron ME. "Geographic distribution of pterygia". *Transactions of the Ophthalmological Society of Australia* 22 (1962): 67-81.
2. Taylor HR, *et al.* "Corneal changes associated with chronic UV irradiation". *Archives of ophthalmology* 107.10 (1989): 1481-1484.
3. Di Girolamo N, *et al.* "Pathogenesis of pterygia: role of cytokines, growth factors, and matrix metalloproteinases". *Progress in Retinal and Eye Research* 23.2 (2004): 195-228.
4. Rocha G. "Surgical management of pterygium". *Techniques in Ophthalmology* 1.1 (2003): 22-28.
5. Cardillo JA, *et al.* "Single intraoperative application versus postoperative mitomycin C eye drops in pterygium surgery". *Ophthalmology* 102.12 (1995): 1949-1952.
6. Ali AM, *et al.* "The role of radiotherapy in the treatment of pterygium: a review of the literature including more than 6000 treated lesions". *Cancer Radiotherapie* 15.2 (2011): 140-147.
7. Qin X-j, *et al.* "Low-Dose Strontium-90 Irradiation Is Effective in Preventing the Recurrence of Pterygia: A Ten-Year Study". *PLoS One* 7.8 (2012): e43500.
8. Nishimura Y, *et al.* "Long term results of fractionated strontium 90 radiation therapy for pterygia". *International Journal of Radiation Oncology, Biology, Physics* 46.1 (2000): 137-141.
9. de Keizer RJ. "Pterygium excision with free conjunctival autograft (FCG) versus postoperative strontium 90 (90Sr) betairradiation. A prospective study". *International Ophthalmology* 21.6 (1997): 335-341.

10. Amano S., *et al.* "Comparative study of intraoperative mitomycin C and beta irradiation in pterygium surgery". *British Journal of Ophthalmology* 84.6 (2000): 618-621.
11. Snibson GR., *et al.* "A prospective randomized controlled trial of beta radiation, mitomycin C, and conjunctival transplantation in the surgical management of pterygium". *Investigative Ophthalmology and Visual Science* 37 (1996): s703.
12. Simsek T., *et al.* "Comparative efficacy of betairradiation and mitomycinC in primary and recurrent pterygium". *European Journal of Ophthalmology* 11.2 (2001): 126-132.

**Volume 1 Issue 1 June 2018**

**© All rights are reserved by Abhishek Onkar,*et al.***