Acta Scientific Otolaryngology (ISSN: 2582-5550)

Volume 8 Issue 6 December 2026

Case Report

Kimura's Disease Presenting as Bilateral Postauricular Swellings in a Young Male: A Rare Case Report

Ashwini Janerao, Amrapali Pawar*, Asmita Madhavi, Anjali Poojary and Ravi Bhurke

Department of Otolaryngology, India

***Corresponding Author:** Amrapali Pawar, Department of Otolaryngology, India.

DOI: 10.31080/ASOL.2026.08.0810

Received: October 01, 2026

Published: November 17, 2026

© All rights are reserved by **Amrapali Pawar., *et al.***

Abstract

Kimura's disease is a rare chronic inflammatory disorder that typically presents with painless head and neck swelling and is frequently associated with peripheral eosinophilia and elevated serum immunoglobulin E (IgE). We report the case of a 25-year-old man who presented with painless, progressively enlarging swellings in both postauricular regions for approximately three months. Examination showed firm, non-tender masses, with no systemic symptoms. Laboratory evaluation demonstrated eosinophilia, and serum IgE was markedly elevated at 12,000 IU/mL. Ultrasound showed enlarged lymph nodes with preserved internal architecture and increased hilar vascularity, while fine-needle aspiration cytology suggested a reactive lymph node process without establishing a definitive diagnosis. Bilateral masses were excised because of persistent swelling and the unusual symmetric presentation. Histopathological examination showed reactive lymphoid follicular hyperplasia with prominent germinal centres, dense eosinophilic infiltration, eosinophil-rich microabscesses, and increased post-capillary vessels, supporting the diagnosis of Kimura's disease. The patient recovered uneventfully and remained asymptomatic without clinical recurrence at eight months of follow-up. Given the association of Kimura's disease with renal involvement and local recurrence, long-term clinical and renal surveillance was advised. This case highlights the need to consider Kimura's disease in young patients with persistent painless postauricular swelling and eosinophilia, particularly when cytology is inconclusive.

Keywords: Bilateral Postauricular Swelling; Case Report; Eosinophilia; Head and Neck Lymphadenopathy; Histopathology; Kimura's Disease; Raised Serum IgE; Renal Involvement

Introduction

Kimura's disease (KD) is an uncommon, chronic inflammatory disorder of unclear aetiology that predominantly affects young men and commonly involves the head and neck. It typically presents with painless subcutaneous swelling or lymphadenopathy and may involve salivary glands [1-3].

The condition was first described in 1937 as eosinophilic hyperplastic lymphogranuloma and was subsequently described in greater detail by Kimura and colleagues in 1948 [1,2]. Characteristic clinical and laboratory features include painless head and neck swelling, peripheral blood eosinophilia, and elevated serum IgE [4]. The underlying pathogenesis is incompletely understood, although a T-helper 2 (Th2)-predominant immune response with eosinophilic inflammation and increased IgE production has been proposed [2,3].

Renal involvement is an important systemic manifestation and most often presents as nephrotic syndrome; reported renal

involvement has been in the range of approximately 10–20% in published series and reviews [2,5]. Because the clinical presentation is nonspecific, KD may be mistaken for reactive lymphadenitis, lymphoma, tuberculosis, or salivary gland disease. Histopathological examination is central to establishing the diagnosis [1,3,6]. Local recurrence after treatment is also well recognised [3,5].

We describe an unusual presentation of KD as bilateral postauricular swelling in a young adult male, with eosinophilia, markedly elevated serum IgE, inconclusive cytology, and diagnosis established by excisional histopathology.

Case Presentation

A 25-year-old man presented to the otorhinolaryngology outpatient clinic with swelling behind both ears that had been present for three months. The swellings had developed gradually and enlarged slowly. He reported no pain, fever, weight loss, night sweats, loss of appetite, or history suggestive of tuberculosis.

Examination revealed firm, non-tender postauricular swellings measuring approximately 3.2 × 2 × 1 cm on the right side and 2.5 × 2 × 1 cm on the left side. The overlying skin was normal and freely mobile, with no local inflammatory changes. Examination of the ears, nose, oral cavity, and neck revealed no other abnormality.

Laboratory evaluation demonstrated eosinophilia. The quantitative laboratory results reported in the case record are summarized in Table 1. Serum IgE measured 12,000 IU/mL. Urinalysis showed no proteinuria.

Laboratory parameter	Patient result	Units	Reference value
Eosinophils	Approximately 30	% of total leukocytes	1–6%*
Total serum immunoglobulin E (IgE)	12,000	IU/mL	<100 IU/mL*
Renal function (Serum Creatinine)	1	mg/dL	0.7–1.3 mg/dL

Table 1: Reported laboratory findings. KD: Kimura's disease; IgE: immunoglobulin E.

Ultrasonography demonstrated enlarged, solid, uniformly hypoechoic lymph nodes with preserved internal architecture and increased hilar vascularity. Fine-needle aspiration cytology suggested a reactive lymph node process but did not establish a definitive diagnosis.

Because the swellings were bilateral and symmetric and persisted despite observation, the bilateral masses were surgically excised. Histopathological examination of both sides demonstrated marked reactive lymphoid follicular hyperplasia with prominent germinal centres, dense eosinophilic infiltration, eosinophil-rich microabscesses, and increased small post-capillary vessels, findings consistent with KD [1,3,6].

Figure 1 shows the left postauricular swellings at presentation. Figure 2 demonstrates the characteristic microscopic findings. The patient recovered uneventfully and was advised to undergo long-term clinical and renal surveillance because of the known risk of recurrence and renal involvement [2,5]. At the eight-month follow-up, the patient remained asymptomatic, with no clinical evidence of recurrence; furthermore, renal assessment was within normal limits. Accordingly, he was advised to undergo long-term surveillance.

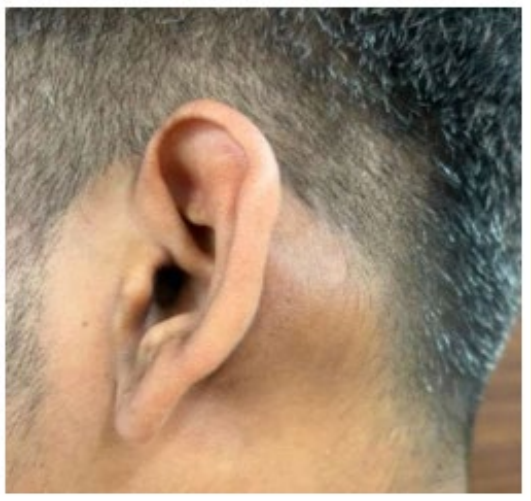

Figure 1: Left postauricular swellings at presentation.

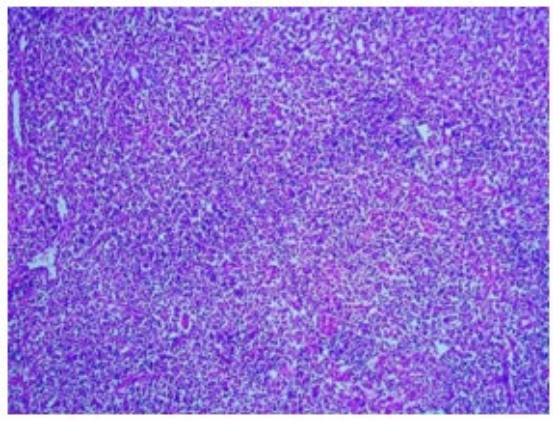

Figure 2: Histopathological appearance [H&E, 40× magnification].

Discussion

Kimura's disease is a rare benign inflammatory disorder characterised by painless head and neck swelling, eosinophilia, and elevated serum IgE [1-3]. Histopathologically, the lymph nodes show preserved architecture with follicular hyperplasia, prominent germinal centres, eosinophilic infiltration, eosinophil-rich microabscesses, and proliferation of post-capillary venules [1,6].

The head and neck are the most frequently involved sites, including cervical lymph nodes and salivary glands. Posterior auricular lymph-node involvement has been documented, but bilateral postauricular presentation is uncommon [1,2]. In our patient, the bilateral location, inconclusive cytology, eosinophilia, and markedly elevated IgE contributed to the diagnostic challenge.

Imaging findings are generally nonspecific. Ultrasonography may demonstrate enlarged hypoechoic lymph nodes with preserved architecture and increased hilar vascularity, but imaging alone cannot reliably distinguish KD from other causes of lymphadenopathy. Histopathology is therefore essential for definitive diagnosis [2,7]. The principal histopathological differential diagnosis is angiolymphoid hyperplasia with eosinophilia (ALHE). Kimura's disease shows prominent lymphoid follicles with enlarged germinal centres, dense eosinophilic infiltration, fibrosis, and increased vascularity. ALHE, in contrast, is characterised by lobular proliferation of capillary-sized vessels lined by plump epithelioid endothelial cells, with variable lymphocytes and eosinophils [1,6].

Renal involvement is an important systemic manifestation of KD and is commonly described as nephrotic syndrome. Published reports have described renal disease in approximately 10–20% of patients, supporting baseline and periodic renal assessment after diagnosis [2,5].

Surgical excision is commonly used for localised disease and provides tissue for definitive diagnosis. However, recurrence remains a recognised problem [4]. A systematic review and meta-analysis found that the risk of recurrence and the relative benefit of adjuvant therapy varied according to tumour size, symptom duration, peripheral eosinophilia, and serum IgE concentration; adjuvant therapy was favoured in patients with tumours ≥3 cm, symptom duration ≥5 years, eosinophilia ≥20%, or IgE ≥10,000 IU/mL [8]. A separate retrospective study also identified treatment modality and systemic disease as factors associated with prognosis [9].

Our patient had a lesion measuring more than 3 cm, eosinophilia of approximately 30%, and serum IgE of 12,000 IU/mL. These features overlap with recurrence-associated characteristics reported in the literature [8,9]. He was therefore counselled regarding recurrence and enrolled in long-term clinical and renal follow-up.

The educational value of this case lies in the combination of bilateral postauricular involvement, marked eosinophilia, markedly elevated serum IgE, inconclusive cytology, and diagnostic confirmation by excisional histopathology. These findings reinforce the importance of considering KD in the differential diagnosis of persistent painless postauricular swelling.

Published Cases and Selected Literature

Table 2 summarizes selected reports cited in this manuscript and the present case.

Study	Population	Site	Eosinophilia/ IgE	Treatment	Outcome/Relevance
Chen., *et al*. (2004) [1]	21 cases; predominantly male	Posterior auricular, cervical, inguinal, epitrochlear nodes; salivary-gland involvement in some patients	Peripheral eosinophilia in most cases	Not a treatment-comparison study; follow-up reported	Established clinicopathological features; posterior auricular involvement documented
Sun., *et al*. (2008) [2]	Literature review	Head and neck; subcutaneous tissues and lymph nodes	Characteristic eosinophilia and elevated IgE	Multiple modalities reported	Frequent relapse and broad treatment experience reviewed
Fouda., *et al*. (2011) [5]	Adult male case	Head and neck disease with renal involvement	Eosinophilia and elevated IgE	Steroid-based medical therapy with renal-directed management	Illustrates renal involvement and treatment considerations
Chen., *et al*. (2015) [9]	32 patients	Head and neck lesions	Clinical variables included eosinophils and systemic disease	Surgery alone, surgery + steroids, or surgery + radiotherapy	Recurrence/prognostic factors evaluated
Present case (2026)	25-year-old male	Bilateral postauricular lymph nodes	Eosinophilia ~30%; IgE 12,000 IU/mL	Surgical excision	Asymptomatic without clinical recurrence at 8 months; long-term follow-up planned

Table 2: Selected published reports relevant to the present case. References correspond to the numbered reference list [1,2,5,9].

Conclusions

Kimura's disease should be considered in the differential diagnosis of persistent, painless head and neck or postauricular swelling, particularly when eosinophilia and elevated serum IgE are present. Bilateral postauricular disease can present a diagnostic challenge when cytology is inconclusive. Histopathological examination remains central to diagnosis. Because recurrence and renal involvement may occur, appropriate treatment and long-term clinical and renal follow-up are important

Consent

Informed consent was obtained from the patient for publication of the case and clinical photographs.

Bibliography

1. Chen H., *et al*. "Kimura disease: a clinicopathologic study of 21 cases". *American Journal of Surgical Pathology* 28 (2004): 505-513.

2. Sun QF., *et al*. "Kimura disease: review of the literature". *Internal Medical Journal* 38 (2008): 668-672.

3. Abuel-Haija M and Hurford MT. "Kimura disease". *Archives of Pathology and Laboratory Medicine* 131 (2007): 650-651.

4. Zhang JZ., *et al*. "Thirty-five cases of Kimura's disease (eosinophilic lymphogranuloma)". *British Journal of Dermatology* 139 (1998): 542-543.

5. Fouda MA., *et al*. "Kimura disease: a case report and review of the literature with a new management protocol". *International Journal of Nephrology* 2011 (2010): 673908.

6. Kung IT., *et al*. "Kimura's disease: a clinico-pathological study of 21 cases and its distinction from angiolymphoid hyperplasia with eosinophilia". *Pathology* 16 (1984): 39-44.

7. "Radiopaedia: Kimura disease". (2026).

8. Lee CC., *et al*. "Treatment algorithm for Kimura's disease: a systematic review and meta-analysis of treatment modalities and prognostic predictors". *International Journal of Surgery* 100 (2022): 106591.

9. Chen QL., *et al*. "Kimura's disease: risk factors of recurrence and prognosis". *International Journal of Clinical and Experimental Medicine* 8 (2015): 21414-21420.