



## Lacrimal Gland Tumour: Adenoid Cystic Carcinoma: Case Report

**Rahul Kumar Shah<sup>1\*</sup> and Krishnappa Ramchandrapa<sup>2</sup>**

<sup>1</sup>M.C.H. Head and Neck Surgery, Department of Head and Neck Oncology, Kidwai Memorial Institute of Oncology, India

<sup>2</sup>Professor, M.C.H. Surgical Oncology, Department of Head and Neck Oncology, Kidwai Memorial Institute of Oncology, India

**\*Corresponding Author:** Rahul Kumar Shah, M.C.H. Head and Neck Surgery, Department of Head and Neck Oncology, Kidwai Memorial Institute of Oncology, India.

**Received:** February 14, 2024

**Published:** June 18, 2024

© All rights are reserved by **Rahul Kumar Shah and Krishnappa Ramchandrapa.**

### Abstract

Lacrimal gland malignancy is common in oncology practice, with adenocystic carcinoma being the most common. Clinical presentation commonly is ocular pain with high predilection of perineural spread with spread to periorbital tissue. Treatment usually require removal of eyeball in form of exenteration in majority of cases.

**Keywords:** Lacrimal Gland Tumour; MRI; Adenoid Cystic Carcinoma

### Introduction

The lacrimal gland is a common site for various neoplastic and inflammatory diseases as orbital fossa masses differential diagnosis [1-3]. Out of these ~50% are epithelial and 50% are non-epithelial in origin. Among epithelial origin, 50% are benign mixed tumor (pleomorphic adenomas), and 50% are carcinomas like- adenoid cystic carcinomas {50%}, malignant mixed tumors, primary adenocarcinomas, mucoepidermoid carcinomas, or squamous carcinomas [5-7]. Among non-epithelial origin, 50% are lymphoid tumors and 50% are infections and inflammatory-pseudotumors. Here we are presenting short case report of rare lacrimal gland adenocystic tumor.

### Case Report

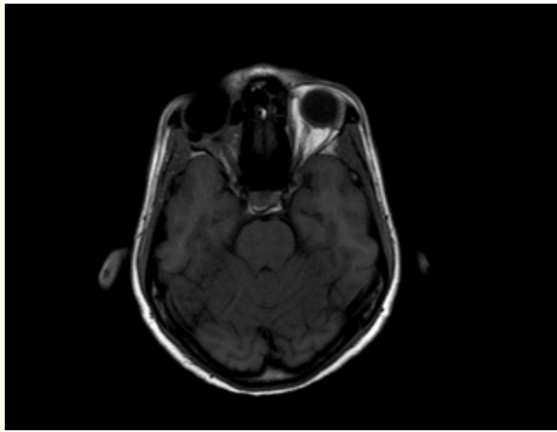
A 38 yrs. old female patient presented to us with history of pain in right eye, right sided headache since last 6 months. Patient also developed protrusion of right eye and difficulty in vision on

right side since last 2 months. Patient was first consulted by an ophthalmologist and then she was referred to us.

On examination, patient had eccentric proptosis of right eye with globe displaced inferomedially with fullness in the superotemporal area associated with mild tenderness. Visual field restriction noted on temporal side. Pre auricular and neck lymphnodes were non palpable. Rest head and neck examination was normal. Preoperative CT SCAN (plain+contrast) showed a well-defined heterogeneously enhancing lesion of 25\*21 mm in superolateral aspect of right orbit in extraconal space, displacing the right globe anteroinferiorly without evidence of internal calcification and lacrimal gland was not seen separately.

MRI (plain+ contrast) showed a well-defined altered signal intensity in superolateral aspect of right orbit in extraconal compartment, with few areas of necrosis. Lesion measure 27\*22\*26 mm with anterior proptosis of right orbit. lesion is not showing

lateral rectus infiltration. Bony remodeling of lateral wall of orbit seen. Optic nerve appeared normal. No intracranial involvement seen. USG guided FNAC was done outside and we did biopsy at our center. On microscopic examination, it showed small round cell tumor with rosette like formation. Histopathology report suggestive of tumor cells with focal tubular formation and hyalinized stroma, suggestive of salivary type of tumor of lacrimal gland origin. On immunohistochemistry, tumor cells were positive for CK, CD117 and P63 NKX2.2.- confirmatory of adenocystic carcinoma. Patient was underwent right orbital exenteration with sparing of eyelids. Histopathological examination of specimen confirmed it to be adenoid cystic carcinoma of lacrimal gland. Post op patient was stable and no any adverse event. Patient had taken radiotherapy and is now recurrence free since last 2 years.



**Figure 1:** MRI image T1 SE.

## Discussion

Adenoid cystic carcinoma (ACC) is the most common malignant tumor of the lacrimal gland and shows bimodal distribution with peak incidences in the second and fourth decades of life with no apparent sex predilection [10]. Patients with ACC usually complain of periocular pain, mild ptosis, and proptosis, along with downward and inward displacement of the globe. Pain is the predominant symptom due to perineural invasion and bony infiltration by the tumor. The tumor usually extends into the posterior orbit because of its capacity to infiltrate and its lack of true encapsulation. Computed tomography (CT) reveals a globular lacrimal gland mass with irregular borders, bony erosion, bone destruction and soft tissue calcification. Contiguous tumor extension toward the medial

orbit, apex and the temporalis fossa is typical of an adenoid cystic carcinoma. Posterior tumor extension toward the superior orbital fissure secondary to retrograde tracking along the lacrimal nerve is another well-recognized aggressive behaviour of this malignancy. On USG, it appear as a hard irregular mass with medium to high reflectivity. Five histopathologic subtypes have been identified: cribriform (Swiss cheese), sclerosing, basaloid, comedocarcinoma, and tubular (ductal). Cribriform pattern is associated with low tumor grade and better prognosis [2]. Young patient usually have this subtype [4]. Basaloid pattern shows a worse prognosis [3]. Controversy remains regarding the optimal local therapy ranging from local surgical approaches to a radical multidisciplinary intervention. Most widely used approach is orbital exenteration with or without removal of the contiguous bone, followed by external beam radiation therapy with or without chemotherapy. Despite extensive surgery and radiation therapy, the survival outcome for these patients remains dismal [8]. Local recurrence is common, seen in about 50% of patients within two years [9], with soft tissues or orbital bone as the most frequent sites. Bone and lung are common foci of distant metastases [8].

## Conclusion

Adenocystic carcinoma of lacrimal gland is most common malignancy. Treatment should consist of trimodality treatment in form of surgery, radiotherapy and chemotherapy.

## Bibliography

1. Shields JA, *et al.* "Classification and incidence of space-occupying lesions of the orbit: a survey of 645 biopsies". *Archives of Ophthalmology* 102 (1984): 1606-1611.
2. Reese AB. "Expanding lesions of the orbit. Bowman Lecture". *Transactions of the Ophthalmological Societies UK* 91 (1971): 85-104.
3. Kennedy RE. "An evaluation of 820 orbital cases". *Transactions of the American Ophthalmological Society* 82 (1984): 134-157.
4. Reese AB. "The treatment of expanding lesions of the orbit: with particular regard to those arising in the lacrimal gland. The Seventh Arthur J Bedell Lecture". *American Journal of Ophthalmology* 41 (1956): 3-11.
5. Font RL and Gamel JW. "Adenoid cystic carcinoma of the lacrimal gland: a clinicopathologic study of 79 cases". In: Nicholson DH, ed. *Ocular pathology update*. New York: Mason (1980): 271-275.

6. Goder GJ. "Tumours of the lacrimal gland". *Orbit* 1 (1982): 91-96.
7. Rootman J. "Diseases of the orbit: a multidisciplinary approach". Philadelphia: JB Lippincott (1988): 384-405.
8. Lee DA, *et al.* "A clinicopathologic study of primary adenoid cystic carcinoma of the lacrimal gland". *Ophthalmology* 92 (1985): 128-134.
9. Jakobiec FA and Font RL. "Orbit". In: Spencer WH, ed. *Ophthalmic pathology: an atlas and textbook*. 3<sup>rd</sup> edn. Philadelphia: WB Saunders; (1986): 2496-2525.
10. Wright JE. "Factors affecting the survival of patients with lacrimal gland tumours". *Canadian Journal of Ophthalmology* 17 (1982): 3-9.