



Poorly Differentiated Palatal Tumour: A Clinical Dilemma

Kanishk Mehta^{1*}, Alifiya Udaipurwala² and Megha Pandey³

¹Associate Professor, Department of Otorhinolaryngology and Head Neck Surgery, American International Institute of Medical Sciences, Udaipur, Rajasthan, India

²Assistant Professor, Department of Otorhinolaryngology and Head Neck Surgery, American International Institute of Medical Sciences, Udaipur, Rajasthan, India

³Professor, Department of Pathology, American International Institute of Medical Sciences, Udaipur, Rajasthan, India

***Corresponding Author:** Kanishk Mehta, Associate Professor, Department of Otorhinolaryngology and Head Neck Surgery, American International Institute of Medical Sciences, Udaipur, Rajasthan, India.

DOI: 10.31080/ASOL.2022.04.0504

Received: September 19, 2022

Published: October 17, 2022

© All rights are reserved by **Kanishk Mehta, et al.**

Abstract

Poorly differentiated malignancy is a rare pathological diagnosis that often puts the surgeon at the crossroads of treatment protocols. It not only presents as a dilemma for deciding the treatment but also adjuvant therapy and prognosis of the patient. Herein we present a case of poorly differentiated palatal tumour that was finally typed as Amelanotic Malignant Melanoma - spindle cell type. Oral melanoma is a rare malignancy with the tendency to metastasize and locally invade tissues more readily than other malignant tumors of the oral cavity, making it vital to report this case.

Keywords: Oral Cavity; Cell Lineage; Surgery

Introduction

Oral cavity tumours account for more than 65% of all tumours. Commonly, many tumours are difficult to categorize histologically. These tumours are labelled as poorly differentiated tumours. These tumours can be further typed by IHC, genomic study etc. Oral Malignant melanoma is one such tumour that is difficult to type on primary histopathological staining hence IHC is done to know cell lineage. It is an extremely rare entity, representing 0.2-8% of all melanomas.

Oral melanoma frequently exhibits an extremely invasive behavior, with vertical growth, high index of metastasis, and poor prognosis. Surgery, either alone or in association with radiotherapy, is the preferred treatment modality. Prognosis is poor with a

5-year survival rate varying from 0 to 55%. With the aims of better understanding and devising protocols for fellow surgeons, we report one such rare poorly differentiated oral malignancy.

Case Report

A 53-year-old female, housewife came to ENT OPD with a complaint of swelling on her palate anteriorly since 6 months. On examination, nontender nodular-proliferative swelling measuring 4 × 4 cm in dimension over anterior one-third of hard palate extending between two lateral canines and ~2 cm posteriorly over hard palate (Figure 1). It was sessile lesion with whitish slough covered floor. It had irregular margins and bled on touch. Level 2 lymphnode on left side neck was palpable 2*2 cm firm, nontender, nonmobile. Other medical history, physical examination was noncontributory.

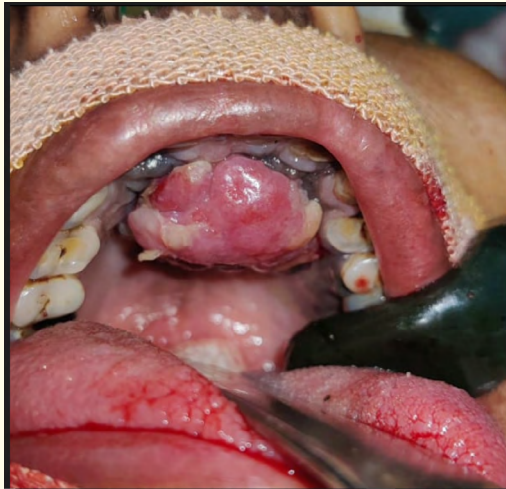


Figure 1: Clinical photograph of the primary lesion in hard palate.

Computed tomography (CT) revealed exophytic heterogeneously enhancing mass with erosion of anterior one-third of palate and inner cortex of bony maxillary alveolus at level of central incisors and lateral canine with jugular lymphadenopathy, largest 23*20 mm in left upper jugular chain. Punch Biopsy was taken which was suggestive of poorly differentiated malignancy (Figure 2).

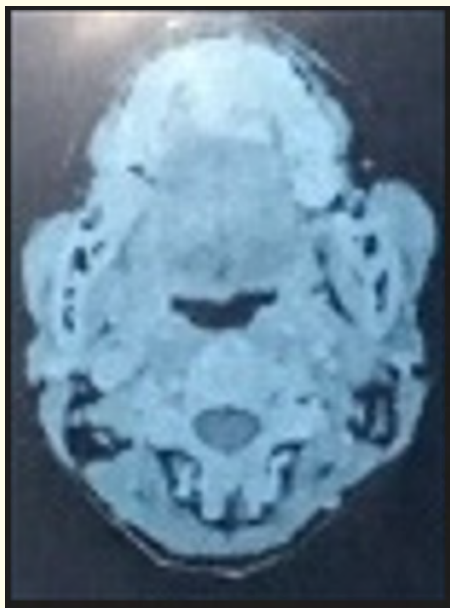

Figure 2: CT scan image showing the extent of lesion.

Wide local excision with 2 cm margin was done and upper alveolectomy was done. Left side Modified radical neck dissection type 3 was done. The lesion was sent for HPE which was suggestive of poorly differentiated malignancy with vascular and perineural invasion present and lymph node showed tumour deposits. Underlying bone was also positive for tumour infiltration. Specimen was sent for Immunohistochemistry, which was suggestive of malignant melanoma with S-100 and HMB tumor marker positive which was then referred to oncology department for further management (Figure 3).

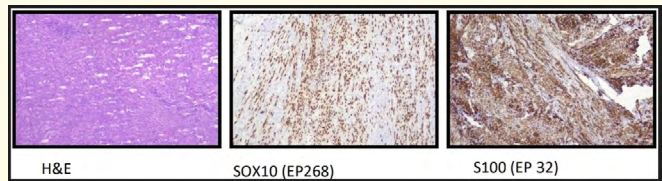


Figure 3: IHC photograph showing positive staining for Malignant Melanoma.

Discussion

Seldom in clinical practice as an Oncosurgeon, we come across poorly differentiated carcinomas. Not only do these lesions pose a hurdle for devising treatment protocols but also staging the disease, prognosis of the patient and overall outcome of treatment remains unclear. Among poorly differentiated tumours, most frequent is non-hodgkin lymphoma-34-66%, second common and potentially treatable are neuroendocrine carcinoma accounting for 10-15% cases. Other rare tumours are melanoma and sarcoma (spindle cells) collectively accounting 15% cases [1].

Primary melanomas are extremely rare and biologically aggressive malignancies involving several anatomic districts: the head and neck (55.4% of the cases), the female genital tract (18%), the anal/rectal tract (23.8%), and the urinary tract (2.8%) [2]. It represents 0.2-8% of all melanomas and 0.5% of all oral malignancies [3]. It occurs most frequently in the maxilla [3]. In head and neck lesions, this neoplasm develops from melanocytes found in the basal layer of the oral mucosa.

The etiology of mucosal melanoma remains unknown. Cigarette smoking, denture irritation and alcohol have been suggested as risk factors. There is no such history given by our patient. Also there is no history of any dental procedure done in past.

Oral malignant melanoma is commonly seen in males, with Male: Female ratio 2:1. It is also common in 5th - 6th decade of life [4]. The SEER program also suggest the mean age as 66 years and with male preponderance [5]. However our patient is of 30 years and female gender. This suggest the rarity of our case.

It's commonly found in Asian population with is consistent with our study.

Clinical presentation of oral melanoma is variable, presenting as a dark brown, bluish black or black mucosal discoloration. Pain was the most common referred symptom. Rarely, melanoma may present itself without clinical evidence of pigmentation, in which case it is termed as Amelanotic Melanoma. These lesions tend to have a worse prognosis because of delayed recognition and subsequent treatment [6], this is consistent with the case in discussion.

Contrast-enhanced CT and MRI can be used to determine the extent of the melanoma and if lymph node metastasis is present. CT is preferred to know bone involvement which was evident in our case which helps to decide extent of surgical ablation. Histologically, it resembles squamous cell carcinoma, with large polyhedral cells with eosinophilic cytoplasm and sometimes exhibiting fusiform and mixed type of cells with downward invasion into the connective tissue [4]. Immunohistochemical study is currently most widely available adjunctive tool for specific diagnosis of various poorly differentiated neoplasm. It helps to know cell lineage and site of origin in case of unknown primary. Precise diagnosis is essential because highly treatable cancers are common and effective targeted therapy can be initiated. Also a prognosis of the patient can be suggested. In case of malignant melanomas, a positive examination for S - 100, HMB -45, Melan A, tyrosinase and vimentin is usually helpful for confirmation, especially in atypically presented and a pigmented melanomas [7].

Ablative surgery with tumor-free margins remains the treatment of choice, with or without neck dissection. Also as described by Zitelli, *et al.* [8] the safety margin should be at least 1.5 cm for head and neck melanomas and 2.5 cm for melanomas larger than 3 cm in diameter. Tanaka [9] reported that primary lesion was controlled in 92.3% of cases with surgery, whereas only 53% cases had controlled primary lesion in radiotherapy group. Postoperative radiotherapy using fractions of 6 Gy twice a week

for a total dose of 30 Gy in margin positive patient and those with extensive lesion. Our patient was also treated, in accordance with above studies, with wide excision of the primary disease, upper central arch alveolectomy and ipsilateral modified radical neck dissection type III.

After surgical ablation, recurrence and metastasis are frequent events, and most patients die because of the disease in 2 years. A review of the literature indicates the 5 years survival rate to be within a broad range of 4.5-48%, but a large cluster occurs at 10-25% [10]. Our patient is under close observation.

Conclusion

Oral Malignant Melanomas are rare, but aggressive tumors with very low survival rates which can metastasize rapidly. Owing to its rarity, even non pigmented lesions in the oral cavity in young group patient should be examined with suspicion. Immunohistochemistry remains integral too in diagnosis of melanoma in the setting of poorly differentiated tumour morphology on HPE. Close patient monitoring is imperative to check for recurrence. Hence, the purpose of this manuscript.

Bibliography

1. John D Hainsworth. "Poorly defferntiated neoplasm". Cancer medicine - 6th edition (2003).
2. Patrick RJ, *et al.* "Primary mucosal melanoma". *Journal of the American Academy of Dermatology* 56 (2007): 828-834.
3. Gu GM, *et al.* "Intraoral melanoma: Long-term follow up and implication for dental clinicians: A case report an literature review". *Oral Surgery, Oral Medicine, Oral Pathology, Oral Radiology, and Endodontology* 96 (2003): 404-413.
4. Meleti M, *et al.* "Oral malignant melanoma: a review of the literature". *Oral Oncology* 43 (2007): 116-121.
5. National Cancer Institute - Surveillance, Epidemiology, and End Results (SEER) Program: Overview of the SEER Program.
6. Huvos AG, *et al.* "A clinicopathologic study of amelanotic melanoma". *Surgery, Gynecology and Obstetrics* 135 (1972): 917-920.
7. Banerjee SS and Harris M. "Morphological and immunophenotypic variations in malignant melanoma". *Histopathology* 36 (2000): 387-402.

8. Zitelli JA., *et al.* "Surgical margins for excision of primary cutaneous melanoma". *Journal of the American Academy of Dermatology* 37 (1997).
9. Tanaka N., *et al.* "Malignant melanoma in the oral region: Ultrastructural and immunohistochemical studies". *Medical Electron Microscopy* 34 (2001): 198-205.
10. Temam S., *et al.* "Postoperative radiotherapy for primary mucosal melanoma of the head and neck". *Cancer* 103 (2005): 313-319.