

## Facial Rehabilitation of a Patient with Failed Buccal Mucosal Graft Using Silicone Cheek Prosthesis - A Case Report

Devendra Kumar\*, Ravichandran Rajagopal, Harsha Kumar Karunakaran and Vivek Velayudhan Nair

Department of Prosthodontics, Kerala University of Health Sciences, India

**\*Corresponding Author:** Devendra Kumar, Postgraduate Final Year Student in the Department of Prosthodontics, Government Dental College, Trivandrum, Kerala, India.

DOI: 10.31080/ASOL.2022.04.0457

**Received:** May 06, 2022

**Published:** June 08, 2022

© All rights are reserved by **Devendra Kumar, et al.**

### Abstract

**Objective:** This article described the facial rehabilitation of a patient with failed buccal mucosal graft using silicone cheek prosthesis.

**Methodology:** Extra-oral defect in the left cheek, in which impression was made with irreversible hydrocolloid material. Wax trial done for the defect. Then the silicone prosthesis was processed using Room temperature vulcanized (RTV) material.

**Results:** The prosthesis was prepared using silicone material as it offers easy customization, less weight, tissue compatibility, easy fabrication, extrinsic and intrinsic coloring, and good dimensional stability [2]. In this present case, an extraoral prosthesis was given due to restricted mouth opening which was retained with tissue adhesive and elastic straps. Since the defect was large and tissue was movable next to defect, tissue adhesive was used as a retentive aid for the prosthesis. The seal and adaptability of the prosthesis was checked by instructing the patient to sip water during which no leakage of water was observed. The patient was satisfied due to proper color matching life-like appearance and ability to eat and drink with the silicone prosthesis *in situ*. Moreover the prosthesis alleviated the social stigma of the patient.

**Conclusion:** It is always a challenge for the prosthodontists to provide a better quality of life in case of surgically resected patient. In order to choose better aids for retention, specialists needs to familiarize all the available options used for prosthodontic rehabilitation. Thorough evaluation and proper treatment planning can give acceptable prosthesis to improves esthetics and functions of the patients.

**Keywords:** Silicone Prosthesis; Squamous Cell Carcinoma; Buccal Mucosal Graft; Maxillofacial Rehabilitation

### Introduction

Body abnormalities or any defects that compromise appearance and function, inability to lead a relatively normal life. This makes a social stigma affecting the day to day life of the patient. Surgical excision is the first choice for early cancers which do not respond to radiation and chemotherapy. Such patients requires multidisciplinary team for comprehensive care and post treatment functional outcomes. Stage I and II disease patients are having great prognosis and anticipated cure rates of 65% and 80% respectively, while poor prognosis is observed in patients with stage III or

IV disease. Surgery is the primary treatment modality for the management of oral cancer. This includes changes in articulation of speech as well as mastication. For full resection of accessible lesions, laser microsurgery is a current technique though it has its own drawbacks needs more number of complex instruments as well as technique sensitive. Postoperative management carries lots of importance as far as the prognosis of the treatment is concerned. For post-operative management of patients, multidisciplinary team of medical and radiation oncologist, oral physician, prosthodontists, dietician, maxillofacial surgeon and physical therapist are

inevitable. In replacing lost orofacial structures even before surgery, the role of prosthodontist cannot be overemphasized. If there is less possibility of satisfactory functional or cosmetic results by surgical procedures then prosthetic restoration of missing oral and facial structures is advocated. It is a challenge to give better quality of living through prosthetic rehabilitation in case of surgically resected patient. The life of patients gets better by prosthetic rehabilitation as it restores the functional as well as psychological setbacks.

### Clinical Report

A 72 years female patient reported to the Department of Prosthodontics, Dental College, Thiruvananthapuram, and Kerala. The chief complaint was an opening on the left side of the face due to failed graft of left cheek due to which inability to eat and drink. Her medical history revealed full thickness wide excision, left segmental mandibulectomy, left maxillary alveolectomy, modified radial neck dissection type II and PMMC (pectoralis major myocutaneous) flap closure for well-differentiated squamous cell carcinoma of buccal mucosa on the left side 8 months ago and post-surgery radiation therapy for one month. There was failure of flap of pectoralis major muscle placed on left cheek buccal mucosa due to medical condition and age. Due to her medical condition and age, the flap closure was not replaced by surgeon, so the defect was left open. In the extraoral examination, an opening of about 54 mm × 42 mm was revealed on the left cheek. Through opening, anterior part of oropharynx and nasopharynx were visible. Due to opening of the defect, the tongue always protrudes from the defect area with drooling of saliva as well. This defects surrounding were skin overlying the zygomatic arch superiorly, skin overlying ramus of mandible posteriorly, and by skin overlying body of mandible inferiorly. In anterior region there were more compressible tissues as there was no bony structures around that could support the skin. The patient was not able to speak and chew as she was having very less mouth opening of 1-2 mm along with many missing teeth in both arches. The feeding of patient was done with help of nasogastric tube [Figure 1]. The extraoral cheek prosthesis was planned for the patient so that it will prevent the liquid food leaking from the defect side as well as to avoid the use of nasogastric tube. This will helps in increase in the psychosocial emotions of the patient as well as life expectancy.

**Figure 1:** Failed buccal mucosal graft left cheek.

### Methodology


#### Materials and Methods

- Alginate impression materials (DPI Algitek alginate)
- Modeling wax (MAARC)
- Type III dental stone (Gem Stone)
- RTV (Room Temperature Vulcanized) silicone [Figure 5]
- Coloring pigments (MP SAI Enterprise)
- Rubber bowl
- Spatula
- Glass slab
- Tissue adhesive (Technovent) [Figure 7]
- Elastic straps.


#### Procedure

Initially patient was seated comfortably in the dental chair with the head tilted towards the right side so the impressions can be made proper. Then impressions were made with irreversible hydrocolloid impression materials by keeping the paper cup covering the defect area over that material is poured [Figure 2]. The impression was poured using Type III dental stone [Figure 3a]. A thin layer of petroleum jelly was applied on the newly made cast. Then wax pattern was made over the cast [Figure 3b]. The wax trial for cheek prosthesis was done on the patient's face so that sealing and seating was verified [Figure 4]. Minor corrections were made during the wax-up trial. The wax pattern was invested in the


dental flask with type III dental stone to avoid air bubbles and the mold prepared. Dewaxing was done. Then patient was made to sit comfortably in the natural light for shade selection. Shades were selected according to the skin texture of the patient face. The wax pattern was processed using Room Temperature Vulcanized (RTV) silicone. Silicone material was dispensed in glass slab and coloring pigments were added and mixed with spatula until matched with the skin color of the patients face. Once the color was matched and proper mixed then the material was packed in the flask. The prosthesis should be free of air bubbles. The curing was done for 24 hours at room temperature which was mentioned in the manufacturer’s instructions. After fabrication of the prosthesis, final polishing was done [Figure 6a and 6b]. The prosthesis was tried on the patient’s face for marginal adaptation, fit, contour and skin color. The prosthesis was retained using silicone adhesive [Figure 8] and elastic strap that were attached to the head cap for proper retention of the prosthesis. Here two retentive aids used for prosthesis so that whichever is convenient for the patients can be used. Instructions were given to the patient about proper removal, insertion and disinfectant of the cheek prosthesis and advised for proper cleaning of the prosthesis. Follow-up of the patient was done after 24 hours sans compliance. With the esthetic outcome of the prosthesis, patient was satisfied.




**Figure 2:** Irreversible hydrocolloid impression.




**Figure 3a:** Poured cast.



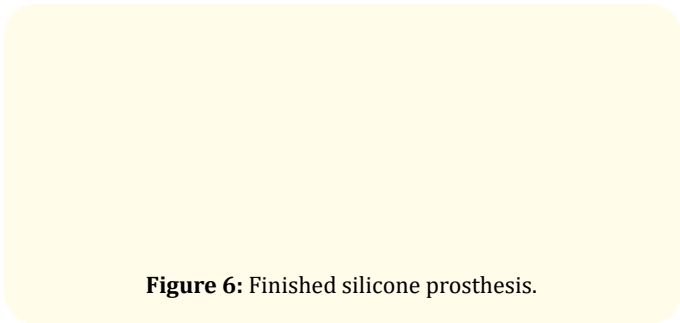
**Figure 3b:** Cast with wax pattern.




**Figure 4:** Wax trial.



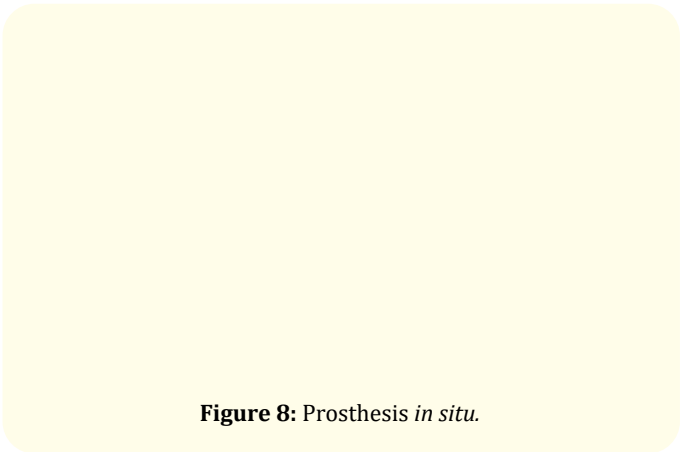
**Figure 5:** RTV Silicone with armamentarium.



**Figure 6:** Finished silicone prosthesis.



**Figure 7:** Tissue adhesive.



**Figure 8:** Prosthesis *in situ*.

### Discussion

Head and neck cancer usually affect day to day life of the patients. The oral intake of food was hampered due to the orofacial defect on the left buccal mucosa. Hence the quality of life was changed. Amid covid-19, it was difficult to wear mask over the nasogastric tube. Hence, to overcome this problem, silicone prosthesis was planned to close the defect and at the same time it gives the natural feeling with the silicone prosthesis. The prosthesis was prepared using silicone material as it offers easy customization, less weight, tissue compatibility, easy fabrication, extrinsic and intrinsic coloring, and good dimensional stability [2]. There are many ways of supporting the cheek prosthesis like magnets [2,3], headgears and spectacles which enhance the seal and esthetics of the patient. In this present case, an extraoral prosthesis was given due to restricted mouth opening and is retained with tissue adhesive or elastic straps. Since the defect was large and tissue was movable near to the defect two retentive aid options like tissue adhesive and elastic straps were given along with the prosthesis. The seal and adaptability of the prosthesis was checked by instructing the patient to drink water during which no leakage of water was observed. The patient was satisfied due to proper color matching and natural appearance of the silicone prosthesis.

### Conclusion

It is always a challenge for the prosthodontists to provide a better quality of life in case of surgically resected patient. In order to choose better aids for retention, prosthodontists needs to familiarize all the available options used for prosthodontic

rehabilitation. Thorough evaluation and proper treatment planning can give acceptable prosthesis, to improve esthetics and functions. Thus improves the quality of life of the patient despite the cumbersome rehabilitative processes which the patient has gone through.

### Declaration of Patient Consent

All appropriate patient consent forms certified. In the form the patient(s) has/have given his/her/their consent for his/her/their images and other clinical information to be reported in the journal. It has been explained to the patient that their names and initials will not be published, but anonymity cannot be guaranteed.

### Bibliography

1. Guttal KS, *et al.* "Orofacial rehabilitation of patients with post-cancer treatment - An overview and report of three cases". *Indian Journal of Cancer* 47 (2010): 59-64.
2. Venugopalan S, *et al.* "Magnetically retained silicone facial prosthesis". *Nigerian Journal of Clinical Practice* 17 (2014): 260-264.
3. Komala J, *et al.* "Early prosthetic management of maxillectomy, hemimandibulectomy patient with a lateral mid facial defect: A case report". *Journal of Indian Prosthodontic Society* 14 (2014): 321-325.
4. Bailoor DN and Nagesh KS. "Fundamentals of oral medicine and radiology". 1<sup>st</sup> ed. New Delhi: Jaypee Publishers (2005): 194-206.