



Nasal Airflow Changes After Targeted Nasal and Sinus Surgery in Children

Peter Catalano^{1*}, Michael Schlewet¹, Melih Motro², John Walker² and Ayman Fraihat³

¹Department of Otolaryngology, St. Elizabeth's Medical Center, Brighton, MA, USA

²Department of Orthodontics, Goldman School of Dentistry, Boston University, Boston, MA, USA

³Department of Otolaryngology, Sulaiman Al Habib Medical Center, Dubai, UAE

***Corresponding Author:** Peter Catalano, Chief of Otolaryngology, St. Elizabeth's Medical Center, Professor of Otolaryngology, Tufts University School of Medicine, Brighton, MA, USA.

DOI: 10.31080/ASOL.2022.04.0437

Received: March 11, 2022

Published: April 29, 2022

© All rights are reserved by **Peter Catalano, et al.**

Abstract

Background: Nasal airway obstruction in children is far more common than is currently appreciated, and is often associated with sleep disordered breathing and recurrent sinusitis. Surgical attempts to reduce this obstruction have primarily focused on adenoidectomy and turbinate reduction. However, many children have nasal obstruction despite adenoidectomy, or without enlarged adenoids. In adults, nasal surgery for obstruction has been limited to septoplasty and inferior turbinoplasty. We have used a different approach to nasal obstruction in children that involves minimally invasive targeted nasal and sinus surgery together. In this study, we evaluate these airway changes in highly symptomatic children with nasal obstruction and recurrent acute sinusitis.

Method: This retrospective pilot study is designed to evaluate the change in nasal obstruction and nasal airway dimensions in children with nasal obstruction, sleep disordered breathing, and recurrent acute sinusitis following targeted minimally invasive nasal and sinus surgery. Fourteen children who demonstrated recurrent acute sinusitis, nasal obstruction, and sleep disordered breathing as determined by history, physical exam, 3D sinus CT-scan, and NOSE scores, and did not have adeno-tonsillar hypertrophy, were included. No palatal expansion had yet been performed. CT imaging used to calculate nasal airway volumes was performed at baseline and 3 months post-surgery, and NOSE scores were used to evaluate nasal obstruction pre and 3 months after surgery.

Result: 14 consecutive patients aged 5-14 years (M 57%; F 43%) were included in this study. All patients demonstrated significant increase in nasal airway volume after surgery ($p < 0.0001$), and NOSE scores improved from an average of 59 pre-op to 8.6 post-op. There was no surgical morbidity.

Conclusion: Targeted minimally invasive nasal and sinus surgery in children with nasal obstruction, sleep disordered breathing, and recurrent acute sinusitis can produce significant improvement in nasal airflow and safely reduce disease related symptoms.

Keywords: Minimally Invasive Nasal Airway Surgery; Nasal Airflow; Nasal Breathing In Children; Pediatric Rhinology

Introduction

Nasal obstruction in children has a different phenotype and clinical presentation compared to adults, and is characterized

more by mouth breathing, sleep disturbance, bruxism, orthodontic problems, and behavioral problems such as hyperactivity/attention deficit disorders, anxiety, and learning disabilities [1]. The

dominant symptom in children is mouth breathing, which may only occur during sleep and therefore can often escape detection. Mouth breathing in children leads to abnormalities in cranio-facial development, namely a high arched and narrow palate [2], which can lead to septal deviation and a further reduction in nasal breathing. As a result, many of these children also develop recurrent acute sinusitis due to the chronic nasal congestion, septal deformities, and turbinate hypertrophy. Due to an underestimation of the prevalence and significance of these symptoms in children and concerns for surgical safety, clinicians have rarely offered nasal and sinus surgery as a possible solution.

Conflicting opinions regarding nasal surgery in pediatric population can be found in the literature, with older studies claiming potential long-term negative effects on craniofacial growth after septoplasty. However, more recent longitudinal studies have demonstrated that septoplasty is completely safe in children providing that the mucoperichondrium is preserved [3]. Sinus surgery in children has also been shown not to interfere with craniofacial growth [4].

For many decades, correction of nasal obstruction has been confined to correction of a septal deviation and reduction of inferior turbinates. However recently, with the use of modern computational fluid dynamics (CFD), researchers have accurately described actual nasal airflow patterns [5], which have prompted us to rethink how best to correct nasal obstruction. We have incorporated this information into our evaluation and surgical planning in adults and children to further improve nasal airway by targeting specific intra nasal regions that affect nasal airflow the most. These not only include the nasal septum and inferior turbinates, but also the septal swell body, middle meatus, and nasal valve. This combined surgical approach was recently shown to be very effective by Catalano, *et al.* in adults with obstructive sleep apnea [6].

In this pilot study, we applied this acquired knowledge of the nasal airway to a group of children with nasal obstruction, sleep disordered breathing, and recurrent acute sinusitis that we evaluated and treated to first define the objective changes in nasal airflow after targeted minimally invasive nasal and sinus surgery, and its effect on the most common symptoms and signs of nasal obstruction via the NOSE scale.

Study design

This is a retrospective study of 14 pediatric patients who underwent targeted minimally invasive nasal and sinus surgery due to

nasal obstruction related to sleep disordered breathing and recurrent acute sinusitis.

- **Inclusion criteria:** Children less than 16 years old with symptoms of sleep disordered breathing (nasal obstruction, mouth breathing, restless sleep, snoring) and recurrent acute sinusitis confirmed by history, physical exam, 3D sinus CT scan, and baseline NOSE scores > 25. All children were refractory to aggressive medical management with multiple oral antibiotics and topical nasal steroid sprays.
- **Exclusion criteria:** Adenoid hypertrophy, tonsil hypertrophy, acute rhinosinusitis at the time of pre-op or post-op CT-scan, use of any form of palate expander at any time, documented inhalant atopy, and NOSE scores < 25 at baseline.

Patient demographics are shown in (Table 1).

Patient #	14
Average age(years)	10.4
Minimum age(years)	6
Maximum age(years)	14
Male%	57
Female%	43
Allergic rhinitis	0
Expander	0

Table 1: Patient demographics.

History was obtained from the referring physician and parents at the first visit. We also used a baseline NOSE score that has been validated in children by Din., *et al.* [7] and Kawai., *et al.* [8]. Physical exam and 3D sinus CT were also obtained at baseline. All children had required multiple rounds of oral antibiotics and nasal steroid sprays which did not alter their frequency of recurrent sinusitis. Physical exam included endoscopic nasal exam, oral/pharyngeal exam, and ear exam. Results are shown in (Table 2).

Adenoid/tonsils Hypertrophy	0
Deviated Nasal Septum	12
Inferior turbinate hypertrophy	14
Nasal Swell Body Hypertrophy	9
Concha Bullosa (unilateral or bilateral)	5

Table 2: Physical exam and CT-sinus findings.

All 14 patients included in the study underwent targeted minimally invasive nasal and sinus surgery which included (Table 3): endoscopic septoplasty, bilateral radiofrequency reduction of the nasal swell body, bilateral inferior turbinate radiofrequency reduction, bilateral uncinectomy, bilateral anterior ethmoidectomy, with unilateral or bilateral concha bullosa resection when present. The post-operative follow-up visits were in 3 weeks and 3 months.

	Surgery done	Septal swell body RFA
1	Uncinectomy/a. ethmoidectomy/septoplasty/turbinates reduction	Y
2	Uncinectomy/a. ethmoidectomy/septoplasty/turbinates reduction	N
3	Uncinectomy/a. ethmoidectomy/turbinates reduction	Y
4	Uncinectomy/a. ethmoidectomy/turbinates reduction	Y
5	Uncinectomy/a. ethmoidectomy/septoplasty/turbinates reduction/concha resection	Y
6	Uncinectomy/a. ethmoidectomy/septoplasty/turbinates reduction	Y
7	Uncinectomy/a. ethmoidectomy/septoplasty/turbinates reduction	Y
8	Uncinectomy/a. ethmoidectomy/septoplasty/turbinates reduction	Y
9	Uncinectomy/septoplasty/turbinates reduction/concha resection	N
10	Uncinectomy/a. ethmoidectomy/turbinates reduction	Y
11	Uncinectomy/a. ethmoidectomy/septoplasty/turbinates reduction/concha resection	N
12	Uncinectomy/a. ethmoidectomy/septoplasty/turbinates reduction	Y
13	Uncinectomy/a. ethmoidectomy/septoplasty/turbinates reduction	Y
14	Uncinectomy/a. ethmoidectomy/turbinates reduction/concha resection	Y

Table 3: Procedures performed for each patient.

Endoscopic nasal debridement was done at their 3-week post-op visit. At the 3-month post op visit, a thorough endoscopic nasal exam was done, and any post-op complications were recorded. No steroid medications were permitted in the post-operative period.

At 3 months post-op parents were again asked to answer the same NOSE questionnaire regarding the child’s breathing and sleep quality (Table 4). All children were asked to assist their parents in answering the NOSE scale questions.

Degree of Obstruction	Pre-op	Post-op
Extreme	2	0
Severe	8	0
Moderate	3	0
Mild	1	10
None	0	4

Table 4: NOSE scores.

3-D sinus CT-scan was obtained again at the 3-month post-operative visit for comparison. No septal hematoma, recurrent sinus infections, nasal cavity adhesions, or middle meatal adhesions were observed in any of the patients during the 3-month follow-up period.

Pre-op and post-op scans of the 14 patients included in the study were processed through Mimics software and images of the nasal cavity airway were segmented (Figure 1 and 2). Pre-op and post-op nasal airway volumes were calculated for each patient for comparison. NOSE scores at baseline were compared to those at 3 months.

Results

14 pre-op scans and 14 post-op scans were segmented and processed through Mimics software, and 3D models were reconstructed in order to calculate nasal cavity volumes. Each pre-op

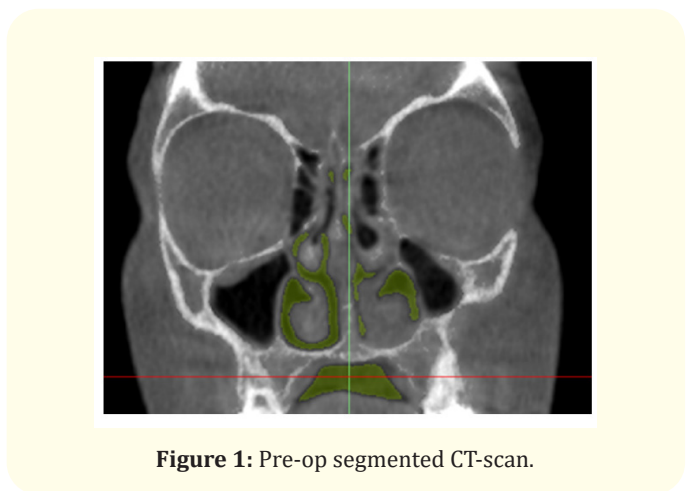


Figure 1: Pre-op segmented CT-scan.

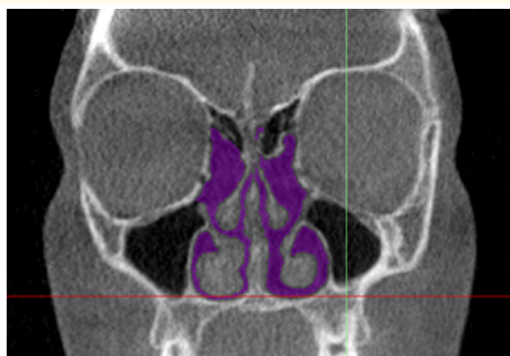

Figure 2: Post-op segmented CT-scan.

and post-op nasal cavity volume were paired for a given patient and differences in volumes were calculated.

Average pre-op nasal volume was 9419.4 mm³ (STDEV 2986.5). Average post-op nasal volume was 13483.3 mm³ (STDEV 4200.2). Average difference in volume post operatively was 4063 mm³ (Figure 3).

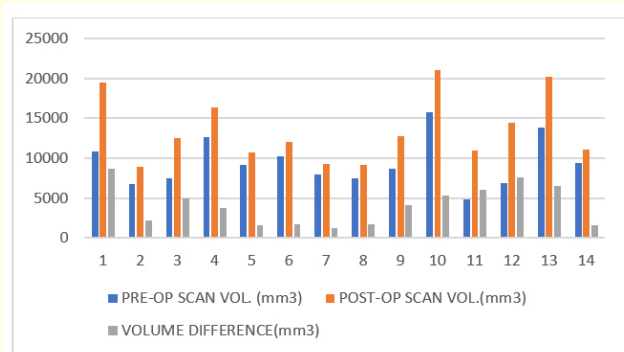


Figure 3: Volume changes (mm³).

Percentage of volume increase post operatively was also calculated and ranged from 16% to 124% with the average being 47.2% (Figure 4).

A paired t-test was utilized and showed a significant difference between pre-op and post-op nasal airway volumes (P < 0.0001).

The baseline pre-op NOSE scores showed 2 patients to have extreme nasal obstruction, 8 were severe, 3 were moderate, and 1

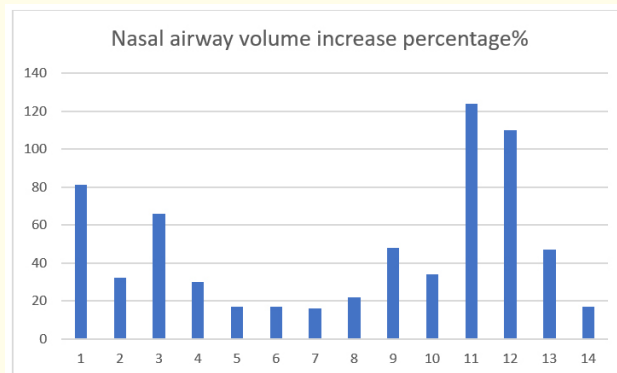


Figure 4: Volume Change as a % of Baseline.

was mild. The average pre-op NOSE score for this cohort was 59 (severe obstruction). The 3-month post-op NOSE scores showed 10 patients with persistent mild nasal obstruction, and 4 had resolved all nasal obstruction. The average 3-month post-op NOSE score was 8.6 (mild obstruction). Results are shown in (Table 4).

The 3-month post op NOSE scores showed significant improvement in all 14 patients. No new or worsening symptoms were reported.

Discussion

Nasal obstruction in children, often manifesting as sleep disordered breathing, has been proven to cause long term physical and psychological morbidity including inadequate somatic growth, hyperactivity and attention deficit, cranio-facial growth restriction, poor school performance, fatigue, irritability, bed wetting, and more [2]. Nasal obstruction in children during sleep is often overlooked despite distinctive symptoms and signs reported by parents such as snoring, mouth breathing, bruxism, interrupted sleep, or active sleep. Furthermore, children can also exhibit constant daytime symptoms of nasal obstruction such as difficulty breathing during exertion, and constant mouth breathing. Most studies in the literature attribute the problem to adenoid and/or tonsillar hypertrophy, and ignore nasal airway obstruction due to other causes.

For many years, adenoidectomy with or without inferior turbinoplasty was the main surgical treatment option offered by physicians for children with nasal obstruction. This philosophy relied on inconsistent data regarding the ability for nasal surgery to cor-

rect this condition, and the risks of such surgery in children on craniofacial growth, leaving many children with symptomatic nasal obstruction until adulthood. Correction of nasal obstruction in adulthood is often less effective because of the craniofacial growth limitations affecting bony confines of the nasal airway.

The importance of nasal breathing on cranio-facial development was first shown by Harvold’s experiments in baby rhesus monkeys [9]. He showed that if you obstruct the nose of baby primates, they become mouth breathers and develop narrow jaws, a high-arched palate, an open bite, and malocclusion. The classic “adenoid facies” we see in children with the same condition. Interestingly, EMG records of orofacial muscles also demonstrated an abrupt pattern of rhythmic discharges, different from the continuous low amplitude and desynchronized discharges that are normally seen. At the end of the six-month trial period, the monkeys were allowed to breathe through their nose again, and a normal EMG pattern was restored and facial growth resumed. Thus, nasal breathing while asleep is very important to stimulate proper palatal growth and activate reflexes that maintain the tonicity of the muscles responsible for upper airway stabilization [10]. Hence, it is of great importance to correct mouth breathing in human children early to avoid any potential impact on craniofacial and upper airway development that often have long-term consequences.

It is also important to note that many recent studies have shown that septoplasty in children is not associated with nasal or facial growth restriction as initially thought, as long as the septal mucoperichondrium is preserved [3]. Even more, it has been shown that not performing septoplasty in children with a symptomatic nasal septal deviation may lead to dental malocclusion, abnormal facial growth and long-term respiratory morbidity [11,12].

Septoplasty and inferior turbinate reduction alone can improve nasal breathing, but is it enough? Modern computational fluid dynamics (CFD) have redefined normal airflow patterns in the human nasal cavity [5]. The studies have shown that airflow arcs through the nose from the nostril region, with the majority of the flow through the middle meatus [13]. Furthermore, Xiong, *et al.* showed a 13% increase in airflow through the middle meatus after uncinectomy and anterior ethmoidectomy alone, highlighting the importance of the upper airflow pathway [14].

These findings rebut the old teaching that only inferior nasal septal deviations and inferior turbinate hypertrophy are responsible for nasal obstruction, and the subsequent nasal surgery that

focused only on the less important inferior nasal airway. Catalano, *et al.* showed a significant decrease in AHI of nearly 50% after targeted nasal and sinus surgery in patients with any degree of OSA by combining middle meatal surgery and swell body reduction with septoplasty and inferior turbinoplasty [6]. This surgical approach was used to treat the children in this study.

In the light of this new information, our approach to the treatment of nasal airway insufficiency in children, especially those with recurrent sinusitis, is to assess the anatomic structures along this nasal airflow arc. These include the internal nasal valve, entire septum, septal swell body, middle meatus, all 4 main turbinates, and the nasopharynx. Our standard surgical technique [15] used in this study includes septoplasty (when indicated) with preservation of mucoperichondrium; inferior turbinate reduction; uncinectomy and anterior ethmoidectomy; and nasal swell body ablation. No tonsil or adenoid hypertrophy as present in this cohort. Nasal valve surgery is extremely rare in children and was not performed in this study.

As CFD simulation software was not available for this study, we did the segmentation of high-resolution sinus CT scans and reconstructed them in 3-D models using Mimics software to calculate nasal airway volumes. One could then estimate indirectly the increase in nasal airflow based on the Hagen-Poiseuille law for fluid flow rates:

$$F = \pi Pr^4 / 8nL$$

Where:

F = Flow rate;

L = Length of the tube;

P = Pressure difference along tube;

n = Fluid viscosity

R⁴ = 4th power of the radius of the tube.

Volume = Length x Width x Height

While the nasal cavity is not a simple geometric object like a box, length and height are unchanged after surgery, leaving width as the only true variable. Therefore, as the width or “r” is increased from our nasal procedure, one can see the impact on airflow using the Hagen-Poiseuille law above.

From the first equation we can conclude that flow rate is directly proportional to the fourth power of the radius, so even a minimal increase in the radius will significantly increase the flow

rate. Thus, we can indirectly estimate a significant increase in nasal airflow with even a minimum increase in nasal cross-sectional area. To give further explanation, one needs to appreciate that other components of the equation are fixed, and the only variable is “r” - the radius. Direct measurement of nasal airflow using CFD would definitely provide us with a more objective assessment of nasal airflow for each patient, but this technology was not available for this study.

However, in lieu of CFD or rhinomanometry, pre and post-op NOSE scores were used instead as a validated instrument for the evaluation of nasal obstruction in children [7,8]. The change in average NOSE scores was dramatic and showed a highly significant change before and after surgery. The fact that not all children were completely asymptomatic may be related to muscle memory and habitual oral breathing that will take longer than 3 months to correct. These children may also need myofunctional retraining therapy to become pure nasal breathers. Overall, these data show significant post-surgical improvement in the signs and symptoms of nasal obstruction that are very common in children.

It is important to explain why nasal airway obstruction may only be seen during sleep. This is directly related to a gravitational fluid shift from the swell body and turbinates when the child is upright during the day, thus making these structures smaller in size and thus increasing nasal airflow. However, when these same children lie down to sleep, the loss of the gravitational advantage allows fluid to return to and increase the size of the swell body and turbinates. This fluid shift may occur within 30 to 90 minutes after being supine, which is why many parents report that their children with nasal obstruction and sleep disordered breathing like to sleep with their head elevated during sleep.

Lastly, all the children in this study had recurrent acute sinusitis in addition to nasal obstruction. Their inflammatory sinus condition was treated aggressively with antibiotics and nasal steroid sprays by their pediatricians without resolution. In fact, this was the main reason for referral, as the symptoms of nasal obstruction were often overlooked by the pediatrician. All children in this study also had skin testing for atopy and were negative. We purposely chose children without atopy to avoid additional confounders to the outcomes.

Conclusion

Children with nasal obstruction, sleep disordered breathing, and recurrent acute sinusitis (without adenoid hypertrophy)

showed significant improvement in their nasal airway obstructive symptoms after targeted minimally invasive nasal and sinus surgery. Nasal airflow as seen by significantly improved NOSE scores, and nasal cavity volume, as shown by 3-D nasal cavity reconstructed models, improved in every child.

Conflict of Interest

Authors declare no conflict of interest and no financial disclosure. Raw data is available with request. IRB approval was received. IRB # HW210. St. Elizabeth’s Medical Center IRB.

Bibliography

1. Huang YS and Guilleminault C. “Pediatric Obstructive Sleep Apnea: Where Do We Stand?”. *Advances in Otorhinolaryngology* 80 (2017): 136-144.
2. Joosten KE, et al. “How do we recognize the child with OSAS?”. *Pediatric Pulmonology* 52.2 (2017): 260-271.
3. Lawrence R. “Pediatric septoplasty: A review of the literature”. *International Journal of Pediatric Otorhinolaryngology* 76.8 (2012): 1078-1081
4. Senior B., et al. “Quantitative impact of pediatric sinus surgery on facial growth”. *Laryngoscope* 110.11 (2011): 1866-1870.
5. De Yun Wang, et al. “Impacts of Fluid Dynamics Simulation in Study of Nasal Airflow Physiology and Pathophysiology in Realistic Human Three-Dimensional Nose Models”. *Clinical and Experimental Otorhinolaryngology* 5.4 (2012): 181-187.
6. Peter J Catalano, et al. “Middle Meatal and Nasal Surgery for Obstructive Sleep Apnea: An Effective New Paradigm for Reducing the Apnea-Hypopnea Index”. *Acta Scientific Otolaryngology* 2.10 (2020): 37-43.
7. Din H., et al. “Psychometric Evaluation of the Nasal Obstruction Symptom Evaluation Scale for Pediatric Patients”. *Otolaryngology-Head and Neck Surgery* 162.2 (2020): 248-254.
8. Kawai K., et al. “Validation of NOSE Scale in Pediatric Patients”. *Laryngoscope* (2021).
9. P Harvold, et al. “Primate Experiments on Oral Respiration”. *American Journal of Orthodontics* 79 (1981): 359-372.
10. Torre C and Guilleminault C. “Establishment of nasal breathing should be the ultimate goal to secure adequate craniofacial

- and airway development in children". *Journal of Pediatrics (Rio J)* (2017).
11. D'Ascanio Lancione C., *et al.* "Craniofacial growth in children with nasal septum deviation: a cephalometric comparative study". *International Journal of Pediatric Otorhinology* 74 (2010): 1180-1183.
 12. Can IH., *et al.* "Acoustic rhinometry in the objective evaluation of childhood septoplasties". *International Journal of Pediatric Otorhinology* 69 (2005): 445-448De.
 13. Kai Zhao., *et al.* "What is normal nasal airflow? A computational study of 22 healthy adults". *International Forum of Allergy and Rhinology* 4.6 (2014): 435-446.
 14. Xiong Guanxia., *et al.* "Numerical flow simulation in the post-endoscopic sinus surgery nasal cavity". *Medical and Biological Engineering and Computing* 46 (2008): 1161-1167.
 15. Catalano Peter J. "The minimally invasive sinus technique: Concepts and controversies". *Operative Techniques in Otolaryngology-Head and Neck Surgery* 17.3 (2006): 189-196.