



Mastoid Pneumatization and its Influence in Temporal Bone Fractures in Head Trauma Patients

Jose L Treviño-Gonzalez^{1*}, Guillermo E Ortega-Fanjon¹, Karla M Santos-Santillana¹, German A Soto-Galindo¹, Yehuda J Garcia-Gutierrez² and Natalia Villarreal-del Bosque²

¹Otolaryngology and Head and Neck Surgery Division, School of Medicine and University Hospital "Dr. Jose E. González", Universidad Autónoma de Nuevo León, Monterrey, Nuevo Leon, Mexico

²Radiology Division, School of Medicine and University Hospital "Dr. Jose E. González", Universidad Autónoma de Nuevo León, Monterrey, Nuevo Leon, Mexico

***Corresponding Author:** Jose L Treviño-Gonzalez, Otolaryngology and Head and Neck Surgery Division, School of Medicine and University Hospital "Dr. Jose E. González", Universidad Autónoma de Nuevo León, Monterrey, Nuevo Leon, Mexico.

DOI: 10.31080/ASOL.2022.04.0406

Received: January 14, 2022

Published: February 28, 2022

© All rights are reserved by **Jose L Treviño-Gonzalez., et al.**

Abstract

Objective: Temporal bone fractures secondary to head trauma is a frequent cause of otorhinolaryngological consult with a reported incidence of 14-22%. The external pressure inflicted on the temporal bone produces a fracture line that commonly follows anatomically vulnerable paths such as suture lines and air cells damaging vital structures harbored within the temporal bone. Multiple studies have demonstrated a protective function of other pneumatized cranial spaces; however, the role of mastoid air cells as a shock observer with protective qualities has lacking evidence. This study aims to correlate the previous findings and determine if temporal bone pneumatization is associated with the severity of temporal bone fractures.

Patients and Methods: We conducted a retrospective study of randomly selected consecutive patients admitted to the University Hospital "Dr Jose E. Gonzalez" from March 2020 to March 2021.

Results: A total of 96 HCT were evaluated. The patients mean age was 36.1 ± 16.1 . A total of 91.4% (n = 85) patients were male. The most common type of pneumatization pattern of the temporal bone was type 3 (32.7%, n = 34). Mastoid and tympanic tegmen were involved in 26.9% of cases (n = 28). Fracture extension through the mastoid and tympani tegmen was observed in 46.7% and 26.7% of patients with type 1 pneumatization, respectively. A statistical difference was observed in tegmen tympani involvement between pneumatization groups (p = 0.0467).

Conclusion: In our study, an extensive pneumatization of the temporal bone was associated with a decreased fracture involvement of mastoid and tympani tegmen.

Keywords: Temporal Bone; Skull Fractures; Anatomic Variation; Traumatic Brain Injury; Ear

Abbreviations

TB: Temporal Bone; TBF: Temporal Bone Fracture; TBI: Traumatic Brain Injury; HCT: Head Computed Tomography

Introduction

Temporal bone fractures (TBF) secondary to head trauma is a frequent cause of otorhinolaryngological consult with a reported incidence of 14-22% [1]. The external pressure inflicted on the temporal bone (TB) produces a fracture line that commonly follows anatomically vulnerable paths such as suture lines and air cells damaging vital structures harbored within the temporal bone. Cranial nerves VII - XI, cochlea, labyrinth, ossicles, tympanic membrane, carotid artery, and jugular vein are all vulnerable to trauma in TBF. Fractures of TB are associated with several comorbidities such as conductive hearing loss, sensorineural hearing loss, cerebrospinal fluid leaks, cranial nerve palsies, and vascular injuries and can have drastic consequences if not recognized and treated promptly and effectively [2].

Little is known about the physiological function of the temporal bone air cell system, however, multiple theories have been proposed and studied, such as temperature and pressure regulation, sound resonance, cranial vault weight distribution and shock absorber with protective effects over vital structures [3]. Multiple studies have demonstrated a protective function of other pneumatized cranial spaces; however, the role of mastoid air cells as a shock absorber with protective qualities has lacking evidence. Paranasal sinus pneumatization has been found to play a protective role in head and facial trauma, reducing ocular injuries and overall mortality [4,5]. Kang, *et al.* correlated the degree of temporal bone pneumatization with clinical sequelae associated with TBF identifying a negative correlation in the incidence of otic - capsule violation and the severity of hearing impairment in patients with TBF [6].

This study aims to correlate the previous findings and determine if temporal bone pneumatization is associated with the severity of temporal bone fractures in patients with head trauma in a tertiary referral hospital.

Materials and Methods

Subjects

We conducted a retrospective study of randomly selected consecutive patients admitted to the University Hospital "Dr Jose E. Gonzalez" from March 2020 to March 2021. The emergency department physician diagnosed traumatic brain injury according to the International Classification of Diseases and Related Health Problems, 10th revision classification (ICD). Patients were considered for inclusion if they were aged 18 years or older and had the diagnosis of temporal bone fracture due to a traumatic brain injury. Exclusion criteria included previous history of traumatic brain injury (TBI), TBF, chronic ear pathology, and previous otologic or skull base surgery, gunshot wounds and penetrating injuries.

Data collection and variables

A total of 96 non-contrast head computed tomography (HCT) were evaluated. Images were obtained from the database of the University Hospital "Dr. Jose E. González" Diagnostic Radiology Department. Images were acquired using a 64-slice CT (GE Medical Systems light speed VCT, Waukesha, WI, EUA) with tube voltage of 120 kV, effective mAs of 18, and a field of view of 142 x 278 mm. Acquired images contained 5 mm axial slices and sagittal and coronal reconstructions in a high-definition bone window. All scans were evaluated by three investigators, including otolaryngologists and head and neck radiologists. Each evaluator independently evaluated the HCT images of the selected patients. Evaluators were blinded to each other's responses, and disagreements were resolved by overall consensus.

The following variables were evaluated in each HCT:

- Temporal bone pneumatization was classified into four groups according to the degree of pneumatization in relation to the sigmoid sinus proposed by Han, *et al.* [7] (Figure 1).
- Temporal bone fractures were classified according to the traditional classification [8,9]. Longitudinal fractures run parallel to the petrous ridge. Transverse fractures run perpendicular to the petrous ridge. Oblique fractures cross the petrotympanic fissure. Mixed temporal fractures include both longitudinal and transverse components. Comminuted fractures were defined as a broken or splintered with three or more fragments.

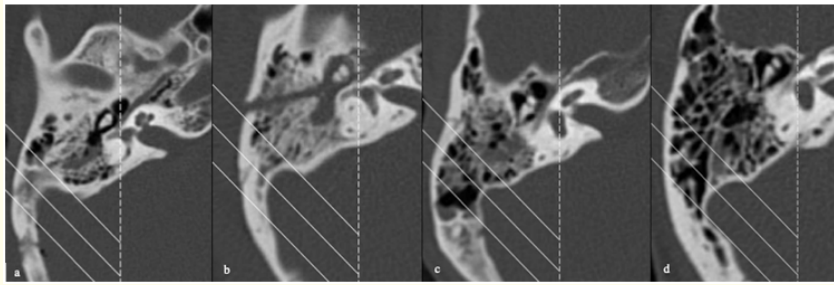


Figure 1: Axial: view of the types of pneumatization of the right temporal bone according to Han., et al. A, Type 1 temporal bone pneumatization. B, Type 2 temporal bone pneumatization. C, Type 3 temporal bone pneumatization. D, Type 4 temporal bone pneumatization.

- Otic capsule involvement was categorized according to Little and Kesser classification in otic capsule violating and otic capsule sparing [10] (Figure 2 A).
- Fracture involvement of adjacent structures included: tegmen tympani, mastoid tegmen (Figure 2B), incudomalleolar joint, carotid canal, facial nerve, and jugular foramen.

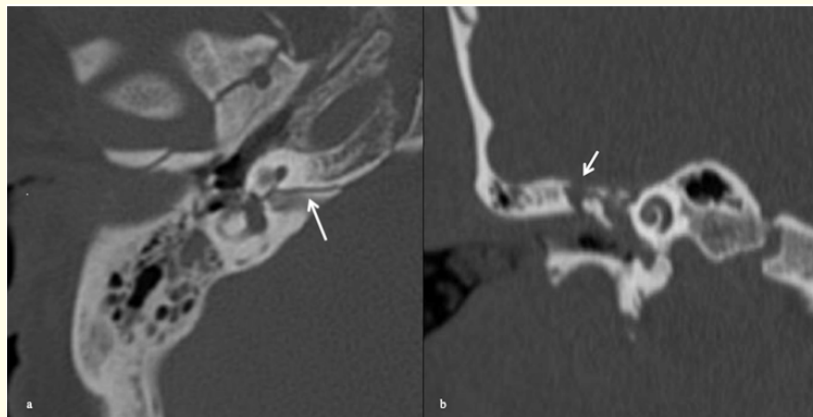


Figure 2: A, Axial view of right temporal bone otic capsule violating fracture (white arrow). B, Coronal view of right temporal tegmen tympani fracture (white arrow).

Ethics and protection of patients

The research protocol was approved by the local Research and Institutional Ethics Committee. The authors assert that all procedures contributing to this work comply with the ethical standards of the relevant national and institutional guidelines on human experimentation and with the Helsinki Declaration of 1975, as revised in 2008.

Statistical analysis

The statistical analysis was performed using the R software (R Foundation for Statistical Computing, Vienna, Austria). Categorical and continuous variables were reported as percentages and frequencies or means and standard deviations, respectively. We used the Chi-squared test for categorical variables, while the U Mann-Whitney test was performed for continuous variables. Association

between variables was investigated by Chi-squared test. A p value <0.05 was statistically significant.

Results and Discussion

Demographic and descriptive data

A total of 96 HCT were evaluated. The patients mean age was 36.1 ± 16.1. A total of 91.4% (n = 85) patients were male. Bilateral temporal fractures were observed in 11.8% (n = 11) of patients (Table 1). The most common type of pneumatization pattern of the temporal bone was type 3 (32.7%, n = 34), followed by type 4 (29.7%, n = 29) and type 2 (25%, n = 26). Longitudinal type of temporal fractures was the most commonly observed (51.9%, n = 54). In comparison, comminute (4.8%, n = 5), oblique (6.7%, n = 7), and mixed (7.7%, n = 8) types were observed in a minority of patients. Involvement of otic capsule was observed in 6.7% of patients (n = 7). Overall, Mastoid and tympanic tegmen were involved in 26.9% of cases (n = 28) (Table 2).

	Overall (N = 93)
Gender	
Female, n (%)	8 (8.6%)
Male, n (%)	85 (91.4%)
Age	
Mean (SD)	36.3 (16.1)
Affected temporal bone	
Left, n (%)	44 (47.3%)
Right, n (%)	38 (40.9%)
Bilateral, n (%)	11 (11.8%)

Table 1: Demographic characteristics of the studied population.

Fracture involvement and type of temporal bone pneumatization

A higher number of otic capsule, incudomalleolar joint, jugular foramen, facial nerve, and tegmen tympani involvement was observed in patients with type 1 temporal bone pneumatization. Fracture extension through the mastoid and tympani tegmen was observed in 46.7% and 26.7% of patients with type 1 pneumatization, respectively. A statistical difference was observed in tegmen tympani involvement between pneumatization groups (p = 0.0467) (Table 3).

	Overall (N = 104)
Temporal bone pneumatization	
Type 1, n (%)	15 (14.4%)
Type 2, n (%)	26 (25.0%)
Type 3, n (%)	34 (32.7%)
Type 4, n (%)	29 (27.9%)
Temporal bone fracture classification	
Longitudinal, n (%)	54 (51.9%)
Transverse, n (%)	30 (28.8%)
Oblique, n (%)	7 (6.7%)
Mixed, n (%)	8 (7.7%)
Comminute, n (%)	5 (4.8%)
Adjacent structures involvement	
Otic capsule	7 (6.7%)
Incudomalleolar joint	13 (12.5%)
Carotid canal	9 (8.7%)
Jugular foramen	6 (5.8%)
Facial nerve canal	20 (19.2%)
Tegmen tympani	28 (26.9%)
Mastoid tegmen	28 (26.9%)

Table 2: Types of temporal bone pneumatization, classification of temporal bone fractures, and involvement of adjacent structures.

Discussion

TBI is a cause of skull base fractures and TBF as a result of high-energy trauma cinematics [11]. TBF are commonly associated with complications such as facial nerve injury, neurosensorial hearing loss, cerebrospinal fluid leakage, among others [12]. Previous studies have correlated the degree of TB pneumatization with the extension and complications of TBF [6]. Our study found an increased incidence of tegmen tympani involvement in type 1 and type 2 TB pneumatization. However, no statistical difference was observed in other affected structures between distinct types of TB pneumatization.

The development of temporal bone CT has facilitated the assessment of TB pneumatization and fractures. Han., *et al.* proposed a classification system for TB pneumatization according to the degree of pneumatization in relation to the sigmoid sinus [7]. Pre-

	Temporal bone pneumatization				P-value
	Type 1 (N = 15)	Type 2 (N = 26)	Type 3 (N = 34)	Type 4 (N = 29)	
Otic capsule					
No	13 (86.7%)	25 (96.2%)	32 (94.1%)	27 (93.1%)	0.699
Yes	2 (13.3%)	1 (3.8%)	2 (5.9%)	2 (6.9%)	
Incudomalleolar joint					
No	12 (80.0%)	24 (92.3%)	30 (88.2%)	25 (86.2%)	0.71
Yes	3 (20.0%)	2 (7.7%)	4 (11.8%)	4 (13.8%)	
Jugular foramen					
No	14 (93.3%)	25 (96.2%)	32 (94.1%)	27 (93.1%)	0.966
Yes	1 (6.7%)	1 (3.8%)	2 (5.9%)	2 (6.9%)	
Carotid canal					
No	13 (86.7%)	24 (92.3%)	31 (91.2%)	27 (93.1%)	0.905
Yes	2 (13.3%)	2 (7.7%)	3 (8.8%)	2 (6.9%)	
Facial nerve canal					
No	11 (73.3%)	20 (76.9%)	26 (76.5%)	27 (93.1%)	0.259
Yes	4 (26.7%)	6 (23.1%)	8 (23.5%)	2 (6.9%)	
Tegmen Tympani					
No	8 (53.3%)	16 (61.5%)	27 (79.4%)	25 (86.2%)	0.0467
Yes	7 (46.7%)	10 (38.5%)	7 (20.6%)	4 (13.8%)	
Mastoid tegmen					
No	11 (73.3%)	16 (61.5%)	26 (76.5%)	23 (79.3%)	0.47
Yes	4 (26.7%)	10 (38.5%)	8 (23.5%)	6 (20.7%)	

Table 3: Types of temporal bone pneumatization associated with fracture involvement of adjacent structures.

vious studies have shown heterogeneous evidence regarding the most common types of TB pneumatization. Distinct studies have reported type 1 and type 2 pneumatization as the most common types, consistent with our findings [6,13-15]. Nevertheless, variations in the prevalence of TB pneumatization may be explained due to different classification systems applied.

The role of TB pneumatization has been proposed as a pressure buffer, gas reserve, and shock absorption space. Additionally, these varying degrees of pneumatization have been implicated in the pathogenesis of distinct pathologies of the TB, including cholesteatoma, otitis media complications, and TBF. Previous studies have demonstrated the protective effect of an extensive TB pneumatization in TBF. Kang, *et al.* observed a decreased violation of the otic

capsule and severity of neurosensorial hearing loss after trauma in well-pneumatized TB [6]. Our study showed a significant increase in tegmen tympani involvement in type 1 TB pneumatization, with no statistical difference observed in otic capsule, incudomalleolar joint, jugular foramen, facial nerve injury between TB pneumatization groups.

TBF have been traditionally classified as transverse, longitudinal, oblique, and mixed. However, this classification system is not correlated with complications, clinical sequelae, and quality of life. Historically, transverse fractures have been associated with an increased risk of complications compared with longitudinal fractures. A new classification proposed by Little and Kesser [10], attempts to predict the clinical outcomes of TBF regarding the frac-

ture involvement of the otic capsule. Otic capsule-violating fractures commonly affect the jugular foramen, internal auditory canal, foramen lacerum, labyrinth, and facial canal [16]. Violation of the otic capsule was associated with an increased presentation of facial nerve injury, neurosensorial hearing loss, and cerebrospinal fluid leakage. Little and Kesser showed a 5-fold increase in facial nerve injury, an 8-fold increase in cerebrospinal fluid leak, and a 25-fold increase in neurosensorial hearing loss [10].

Injury of adjacent neural, vascular, and sensory structures have been associated with an important impairment of post-trauma quality of life in TBF. Montava, *et al.* showed a 12-month persistence of balance issues, hypoacusia, and tinnitus [17]. TBI and TBF are often associated with maxillofacial and skull base fractures increasing the risk of complications. Additionally, TBF are associated with intracranial injuries in up to 90% of cases, including subarachnoid hemorrhages, brain edema, herniation, brain contusions, among others [16].

Our study has strengths that should be considered. The HCT evaluation was blinded and performed by otolaryngologists and head and neck radiologists with strict criteria and standard classification of the variables. However, fine-slice temporal bone CT were not evaluated in this study. The retrospective design of the study limits its applications and the mechanism of trauma was not studied in our population.

Conclusion

In this study, a type 3 and type 4 TB pneumatization showed a tendency to fewer injury of adjacent neural, vascular, and sensory structures in TB fractures due to TBI.

Multidisciplinary evaluation of TBF is crucial due to frequently associated lesions. A significant increase in tegmen tympani involvement in type 1 and type 2 TB pneumatization was observed in our population. Imaging examination is crucial for an accurate diagnosis of TBF patterns and types of TB pneumatization to evaluate and predict associated complications.

Acknowledgements

None.

Conflict of Interest

The authors have no competing interests to declare that are relevant to the content of this article.

Bibliography

1. Brodie HA, *et al.* "Management of complications from 820 temporal bone fractures". *The American Journal of Otolaryngology* 18.2 (1997): 188-197.
2. Baugnon, *et al.* "Skull base fractures and their complications". *Neuroimaging Clinics of North America* 24.3 (2014): 439-465.
3. Magnuson B. "Functions of the mastoid cell system: auto-regulation of temperature and gas pressure". *The Journal of Laryngology and Otolaryngology* 117.2 (2003): 99-103.
4. Kellman RM, *et al.* "The paranasal sinuses as a protective crumple zone for the orbit". *The Laryngoscope* 119.9 (2009): 1682-1690.
5. Celiker M, *et al.* "Controversy about the protective role of volume in the frontal sinus after severe head trauma: larger sinus equates with higher risk of death". *The British Journal of Oral and Maxillofacial Surgery* 58.3 (2020): 314-318.
6. Kang TK, *et al.* "The potential protective effects of temporal bone pneumatization: A shock absorber in temporal bone fracture". *PloS One* 14.5 (2019): e0217682.
7. Han SJ, *et al.* "Classification of temporal bone pneumatization based on sigmoid sinus using computed tomography". *Clinical Radiology* 62.11 (2007): 1110-1118.
8. Gurdjian ES, *et al.* "Deformations of the skull in head injury studied by the stresscoat technique, quantitative determinations". *Surgery, Gynecology and Obstetrics* 83 (1946): 219-339.
9. Ghorayeb B Y and J W Yeakley. "Temporal bone fractures: longitudinal or oblique? The case for oblique temporal bone fractures". *The Laryngoscope* 102.2 (1992): 129-134.
10. Little SC, *et al.* "Radiographic classification of temporal bone fractures: clinical predictability using a new system". *Archives of Otorhinolaryngology-Head and Neck Surgery* 132.12 (2006): 1300-1304.

11. Johnson Freedom., *et al.* "Temporal bone fracture: evaluation and management in the modern era". *Otolaryngologic clinics of North America* 41.3 (2008): 597-618.
12. Kanona H., *et al.* "A large case series of temporal bone fractures at a UK major trauma centre with an evidence-based management protocol". *The Journal of Laryngology and Otology* 134.3 (2020): 205-212.
13. Jadhav AB., *et al.* "Classification and volumetric analysis of temporal bone pneumatization using cone beam computed tomography". *Oral Surgery, Oral Medicine, Oral Pathology and Oral Radiology* 117.3 (2014): 376-384.
14. Bronoosh P., *et al.* "Temporal bone pneumatisation: a computed tomography study of pneumatized articular tubercle". *Clinical Radiology* 69.2 (2014): 151-156.
15. Dexian Tan A., *et al.* "Classification of Temporal Bone Pneumatization on High-Resolution Computed Tomography: Prevalence Patterns and Implications". *Otolaryngology--head and Neck Surgery: Official Journal of American Academy of Otolaryngology-Head and Neck Surgery* 159.4 (2018): 743-749.
16. Kurihara YY., *et al.* "Temporal Bone Trauma: Typical CT and MRI Appearances and Important Points for Evaluation". *RadioGraphics* 40.4 (2020): 1148-1162.
17. Montava M., *et al.* "Temporal bone fractures: sequelae and their impact on quality of life". *American Journal of Otolaryngology* 36.3 (2015): 364-370.

Assets from publication with us

- Prompt Acknowledgement after receiving the article
- Thorough Double blinded peer review
- Rapid Publication
- Issue of Publication Certificate
- High visibility of your Published work

Website: www.actascientific.com/

Submit Article: www.actascientific.com/submission.php

Email us: editor@actascientific.com

Contact us: +91 9182824667