

## An Update of Bronchoscopy in Pediatric Practice-Review

### Md Atiar Rahman\*

Associate Professor of Pediatric Pulmonology, Department of Pediatrics,  
Bangabandhu Sheikh Mujib Medical University, Dhaka, Bangladesh

**\*Corresponding Author:** Md Atiar Rahman, Associate Professor of Pediatric Pulmonology, Department of Pediatrics, Bangabandhu Sheikh Mujib Medical University, Dhaka, Bangladesh. **E-mail:** atiar777@yahoo.com

**Received:** June 15, 2021

**Published:** July 07, 2021

© All rights are reserved by **Md Atiar Rahman.**

### Abstract

Bronchoscopy is an invasive procedure for examination of air passages and lungs. It helps both for diagnosis as well as intervention of airway disease in children and adult. This procedure can be performed by rigid or flexible bronchoscope on the needs of patients and choice of the expertise. It can help direct visualization of airways, to obtain biopsy material, Broncho alveolar lavage (BAL) fluid from lungs and distal airways and help to diagnose various pulmonary diseases. Foreign body removal is another indication of bronchoscopy in children. Recently interventional bronchoscopic procedure has now been developed for treatment of laser therapy, balloon dilatation and stenting of airway in children. Though bronchoscopy is a safe procedure, but sometimes obstruction of airway may require special attention during procedure. The aim of this review is to outline update of bronchoscopic procedure for diagnostic, therapeutic and intervention of airway disease in children.

**Keywords:** Bronchoscopy; Children; Airway Disease; Rigid; Flexible; Broncho Alveolar Lavage (BAL)

### Introduction

Pediatric bronchoscopy is commonly practiced in diagnostic, therapeutic and good number of modern and advanced interventions in children.

Both rigid bronchoscope (RB) and flexible bronchoscope (FB) are used in Pediatric age group depending on the needs and indication of patients. The pediatric airway is not the same like adults because of smaller in size, soft in consistency and position of epiglottis [1]. Therefore, type of bronchoscopy should be decided not only for indications but also considering these structural differences.

A flexible bronchoscope is a thin flexible tube with a camera which we can directly visualize inside the air passages and lungs. A small suction channel, which can help us for suction and collecting

samples or biopsy material and delivering medicine directly to the airway or lung. Flexible fiber optic bronchoscope is a major diagnostic tool commonly used in pediatric practice for diagnosis of airway anomalies, Broncho alveolar lavage for diagnostic and therapeutic purposes, interventions and also foreign body removal [2,3].

Flexible Bronchoscopy is carried out under mild sedation or sometimes under general anesthesia. During the procedure, patient can remain normal breathing or positive pressure ventilation if needed. Breathing is also maintained by laryngeal mask, nasopharyngeal or endotracheal tube also [4-6].

Rigid Bronchoscopy is always done under general anesthesia in an operating theatre for bronchial dilation, stenting, laser therapy, removal of granulation tissue around stent and also foreign body.

The main advantage of RB is to secure the airway and allows for assisted ventilation during the procedure. RB is 3 to 7 mm in diameter and 20 - 50 cm in length. External diameter of RB is selected according to the weight of the child (Table 1) [7].

Weight (kg)	External diameter (mm)	Internal diameter (mm)	Size number
< 3	4.2	3.5	2.5
3 - 6	5	4.3	3
6 - 15	5.7	5	3.5
15 - 20	6.7	6	4
20 - 25	7.8	7.1	5
25 - 25	8.2	7.5	6

**Table 1:** Diameters of RB.

**Methods**

**Data extraction**

I performed a systematic review of the literature, focusing Pediatric Bronchoscope with foreign body extraction, balloon dilation and occlusion, laser-assisted procedures, usage of airway stents, microdebridors, cryotherapy, endoscopic intubation, and application of drugs and other liquids. I using the MEDLINE (accessed via Pub Med) and Scopus databases. I first looked for systematic literature reviews, and then randomized controlled trials (RCTs); if such studies were not available, searched for observational studies, published between 1996 and 2020 in English, regardless of impact factor. In cases of limited pediatric evidence, position statements from the adult literature were also consulted. For the literature searches, the main keywords child\* or pediatric, and bronchoscopy were used in addition to other relevant specific keywords.

**Result and Discussion**

**Indications of bronchoscopy**

There are a good number of indications that we have recommended a child for bronchoscopy. These are listed in table 2.

**Evaluating the airway anatomy and dynamics**

There are several causes like laryngomalacia, Tracheobronchomalacia with persistent stridor indicating examination of the airways to reach the diagnosis and in case of atypical presentation like noisy breathing, unexplained hemoptysis are also strong indication to perform bronchoscopy [6-9].

Exploration of airways
Persistent stridor
Persistent wheezing
Hemoptysis
Suspicion of foreign body
Persistent of recurrent atelectasis
Persistent of recurrent pneumonia
Localized pulmonary hyperlucency
Problems with tracheostomy or other artificial tubes
Obtaining biological samples (BAL, bronchial biopsy, brushing)
Pneumonia in immunosuppressed patients
Chronic interstitial pneumonia (hemosiderosis, eosinophilic pneumonia, etc.)
Obstruction in bronchial lumen
Aspiration to lungs
Therapeutic procedures
Aspiration of endobronchial secretions
Difficult intubations
Selective intubations

**Table 2:** Indications of bronchoscopy.

**Fiber optic flexible bronchoscope (FFB)**

Presence of endobronchial infections, granulations, tumors, anatomical abnormalities can be confirmed by FFB. FFB along with dynamic CT helps in diagnosis of dynamic of airway and obstructions like excessive dynamic airway compression (EDAC). Apart from anatomical evaluation, FFB also helps in collection of Broncho alveolar lavage fluid and biopsy material for microbiological, pathological examination of certain diseases.

Any radiological finding on chest x-rays non resolving with medication and unexplained symptoms is strong indication for Flexible Bronchoscopy [9]. Air trapping on chest x-ray due to any cause should be evaluated with FB. During Flexible Bronchoscopy, mild sedation is needed to see airway dynamics especially in laryngomalacia, tracheomalacia and bronchomalacia patient [8-10].

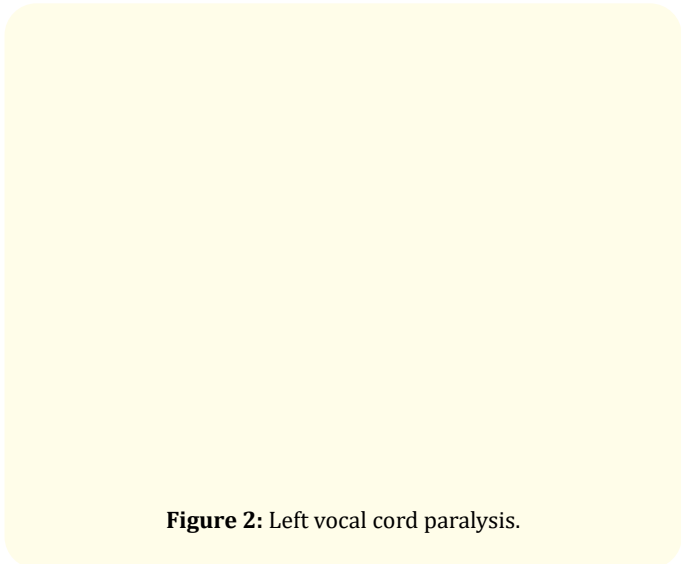
Noisy breathing is an indication for endoscopic procedure when it is progressive or causing apneas, difficulty in feeding, or growth retardation [11]. It has been practiced to do endoscope/

bronchoscope even having severe stridor. Stridor may be caused by laryngomalacia like collapse of cuneiform cartilage, long tubular epiglottis shown in figure 1 with hemangioma or tracheomalacia, vocal cord paralysis are also indication of Bronchoscopy [12,13]. Children with Chiari malformation having breathing difficulties due to vocal cord paralysis, improves after decompression surgery by interventional bronchoscopy [14]. Vocal cord dysfunction was evaluated by bronchoscopy recently in atypical asthma in children and adolescents and paradoxical inspiratory narrowing of the vocal cords also has been observed during bronchoscopic procedure in pediatric patients as well [15,16].



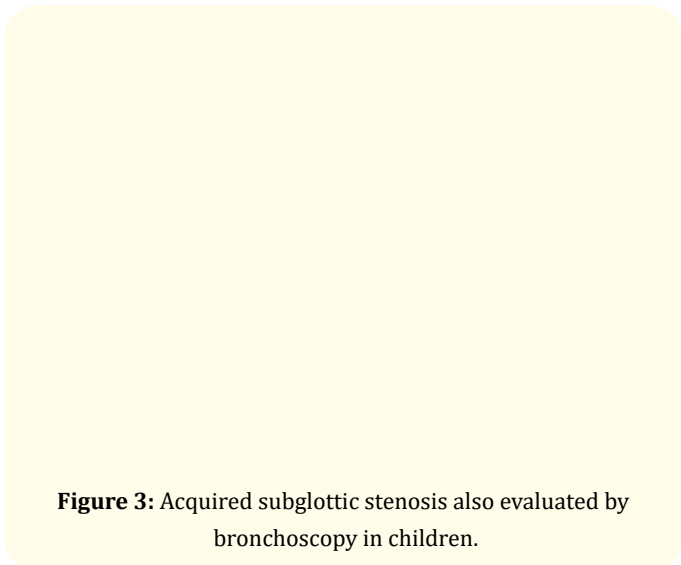
**Figure 1:** Inspiratory collapse of cuneiform cartilages (A), anterior collapse of the cuneiform cartilages (B) and long tubular epiglottis (C).

The vocal cord paralysis is another frequent cause of stridor (Figure 2). Which need to do bronchoscopy to explore the underlying causes. Vocal cord paralysis secondary to Arnold-Chiari syndrome is also found. The unilateral vocal cord paralysis is also found due to iatrogenic repair of cardiovascular disorders, trauma or infections.



**Figure 2:** Left vocal cord paralysis.

Acquired subglottic stenosis is also a frequent cause of stridor, usually secondary to long time intubation (Figure 3). The incidence of acquired subglottic stenosis is increasing due to improved care of premature newborn.



**Figure 3:** Acquired subglottic stenosis also evaluated by bronchoscopy in children.

### Obtaining biological samples

BAL is the most common method for collection of sample from distal airways and alveolar surfaces. Saline/ distilled water is introduced into distal airways and aspirated as lavage for laboratorial examination especially tuberculosis, pneumonia and cystic fibrosis. BAL fluid is more useful to evaluate infectious and inflammatory process of the airways [17].

The indications of BAL are [5]:

- Diagnosis of suspected infection;
- Pulmonary infiltrates;
- Dyspnea;
- Hypoxia;
- Tachypnea;
- Recurrent and/or persistent pulmonary infiltrates;
- Interstitial infiltrates;
- Diffuse alveolar infiltration;
- Pulmonary hemorrhage;
- Alveolar proteinases;
- Suspected aspiration;
- Lung transplant;
- Hyper eosinophilic lung disease.

BAL ideally should be obtained before starting treatment but can be still informative when the patient is unresponsive to treatment or deteriorating despite of adequate treatment.

Presence of significant number of macrophages laden with lipid and pepsin in BAL support the diagnosis of aspiration [18]. Both BAL and trans bronchial biopsy are sometime used to distinguish rejection from infection in lung transplant patient [19]. Finally, BAL is also used for therapeutic removal of mucus plugs, blood clots and bronchial casts [20].

### The rigid bronchoscope

There are various kinds of rigid bronchoscopes with a variety of sizes and lengths are used in Pediatric practice A variety of telescopes are used during rigid bronchoscopic procedure for inspection of all lobar or distal segments. The principal advantage of the rigid bronchoscope is complete control of the airway; maintain

oxygenation, spontaneous respiration and to assess the degree of collapse lung or diameter of air passages. Heavy hemorrhage or tenacious secretions are sometime challenge during bronchoscopic procedure which can be managed by withdrawing the telescope and proper suctioning by passing suction catheters directly through the bronchoscope with maintaining oxygenation [21,22].

### Laser therapy of airway stenosis

Interventional endoscopy/ bronchoscopy like laser, dilation, stenting was commonly done in the larynx, trachea and bronchus due to polyp, growth, stenosis, hemangioma and severe malacia. The optimal treatment of subglottic hemangioma is tracheotomy recommended by some groups [21,22] others have reported the application of intralesional steroids in children during laryngoscopy followed by intubation for some days [23,24]. Careful CO<sub>2</sub> laser resection of hemangioma is usually done to avoid tracheostomy or intubation in most children [25,26]. The other indication of lasers for the droning of thyroglossal or laryngeal cysts, cicatricial subglottic narrowing or stenosis, large subglottic cyst, lesions even in the larynx of neonates, and in the trachea of older children [21,22,27]. CO<sub>2</sub> laser is comparatively better than with Neodym YAG lasers because of less scarring [26-28].

Lasers have been done to remove granulation tissue or infectious tumors (e.g. nontuberculous mycobacterial granulomas [29]), and cicatricial obstructing lesions in the trachea [30]. Bronchogenic cysts also have been incised endoscopically with lasers [31,32].

### Therapeutic indications

The therapeutic indications of bronchoscopy in children are to maintenance airway patency. RB is superior to FB to remove foreign bodies and other interventional procedures. FB is used to remove foreign bodies in small and peripheral airways [19]. RB has several disadvantages over FB such as requiring general anesthesia, assisted ventilation, larger instruments and greater variety of forceps [3]. Most of the foreign bodies are non-radiopaque but some of them can be easily seen in chest X-rays. When clinical suspicion of foreign body's inhalation, on the basis of history and evidence based witness bronchoscopy is indicated regardless of negative radiologic and clinical findings. Plastic bronchitis with bronchial casts in the tracheobronchial tree may causing partial or complete airway obstruction needed serial Rigid Bronchoscopy, when medi-

cal treatment failed [20]. Rigid bronchoscopy in conjunction with surgery can also do in congenital or acquired tracheoesophageal fistulae [23,24].

### Endoscopic/bronchoscopic drug application

When surgical removal through bronchoscope cannot cure the papillomatosis, then intralesional application of interferon or cidofovir and photodynamic therapy is currently being practiced in some advanced centre [30-32].

### Bronchial biopsy

Bronchial biopsy is performed in research studies in asthma, recurrent wheezing, and cystic fibrosis in the children and has the diagnostic value in infectious, non-infectious granulomatous diseases (tuberculosis, sarcoidosis), endobronchial tumors and chronic fungal diseases etc.

Some endoscopists has been preferred flexible bronchoscope than rigid one. A flexible bronchoscope having diameter of (4.9 mm OD) is also used for biopsies because a 2.0 mm instrumentation channel is needed for most biopsy forceps. Standard 1.8 mm diameter forceps are used to obtain bronchial samples, but 1.1 forceps have also been successfully used. We have to keep in mind that the size of the samples obtained with the 1.1 forceps are obviously smaller, and the success rate of the technique is low because of smaller size. In general, the technique is well tolerated and no or less risk of bleeding or pneumothorax has been reported. The risk of major bleeding increases in biopsies of much vascularized lesions. In these cases, 1 - 2 ml of adrenalin at 1/10.000 should be introduced before or during this procedure.

### Tran's bronchial biopsy

Tran's bronchial biopsy (TB) is a procedure performed to obtain lung fragments, but in children is not yet established.

### Contraindications to bronchoscopy

There are no absolute contraindications for bronchoscopy but having clear indication, proper equipment and expertise are mandatory to perform a safe procedure. Relative risk factors for this procedure are cardiovascular instability, bleeding diathesis (thrombocytopenia or hypoproteinemia), severe bronchospasm and hypoxemia [5].

### Complications of bronchoscopy

Discomfort, coughing, fever, hypoxia, bleeding, air leak from the lungs.

Rarely, the airway may be damaged by the bronchoscope, particularly if the lung is already severe inflamed or diseased. If the lung is punctured, it may cause an air leak syndrome (called pneumothorax).

Both FB and RB are almost safe procedures and complications depend on the patient's risk factors. Main complications are [3]:

- Laryngeal spasm;
- Hypoxemia;
- Bronchospasm;
- Trauma and obstruction of airway due to edema;
- Hemorrhage;
- Pneumothorax;
- Fever and infections.

### Summary

Bronchoscopy plays an integral role in the diagnosis and treatment of air passages and lung disease. In appropriately selected patients, foreign body removal, laser therapy, balloon dilation and airway stenting treatments provide immediate relief from airway obstruction. BAL fluid, biopsy material also helps to explore some common and rarer diseases. The selection of cases and treatment plan depend on a case-by-case basis after thorough airway assessment, underlying disease and its natural history, clinical condition of the patient.

### Bibliography

1. Pérez-Frías J., *et al.* "Pediatric bronchoscopy guidelines". *Archivos de Bronconeumología* 47 (2011): 350-360.
2. Swanson KL., *et al.* "Flexible bronchoscopy management of airway foreign bodies in children". *Chest* 121 (2002): 1695-1700.
3. Farrell PT. "Rigid bronchoscopy for foreign body removal: anesthesia and ventilation". *Pediatric Anesthesia* 14 (2004): 84-89.

4. Bailey AG, et al. "Anesthetic management of infants requiring endobronchial argon laser surgery". *Canadian Journal of Anesthesia* 39 (1992): 590-593.
5. Wood RE and Daines C. "Bronchoscopy and Broncho alveolar lavage in pediatric patients". In: Wilmott RW, Bush a, Boat TF. Editors. *Kending and Chernick's Disorders of the Respiratory Tract in Children*. Eight edition. Philadelphia: Saunders (2012): 94-109.
6. Masters IB and Cooper P. "Pediatric flexible bronchoscopy". *Journal of Paediatrics and Child Health* 38 (2002): 555-559.
7. Hitter A, et al. "Rigid bronchoscopy". In: Prifitis KN, Anthracopoulus MB, Eber E, et al. editors. *Pediatric Bronchoscopy: Progress in Respiratory Research*. Basel: Karger 38 (2010): 83-94.
8. Boudewyns A, et al. "Clinical practice: an approach to stridor in infants and children". *European Journal of Pediatrics* 169 (2010): 135-141.
9. Woods RK, et al. "Vascular anomalies and tracheoesophageal compression: a single institution's 25-year experience". *The Annals of Thoracic Surgery* 72 (2001): 434-438.
10. Wood RE and Prakash UB. "Pediatric flexible bronchoscopy". In: Prakash UB. editor. *Bronchoscope*. New York: Raven Press (1994): 345-350.
11. Mancuso RF. "Stridor in neonates". *Pediatric Clinics of North America* 43 (1996): 1339-1356.
12. Muller-Holve W, et al. "Neonatal asphyxia immediately following birth due to thyroglossal cyst blocking the larynx". *Zeitschrift fur Geburtshilfe und Perinatologie* 179 (1975): 147-142.
13. Gonzalez C, et al. "Synchronous airway lesions in infancy". *Annals of Otolaryngology and Laryngology: SAGE Journals* 96 (1987): 77-80.
14. Linder A and Lindholm CE. "Laryngologic management of infants with the Chiari II syndrome". *International Journal of Pediatric Otorhinolaryngology* 39 (1997): 187-197.
15. Niggemann B, et al. "Vocal cord dysfunction in three children misdiagnosis of bronchial asthma?" *Pediatric Allergy and Immunology* 9 (1998): 97-100.
16. Ferris RL, et al. "Functional laryngeal dyskinesia in children and adults". *Laryngoscope* 108 (1998): 1520-1523.
17. Balough K, et al. "The relationship between infection and inflammation in the early stages of lung disease from cystic fibrosis". *Pediatric Pulmonology* 20 (1995): 63-70.
18. Colombo JL and Hallberg TK. "Recurrent aspiration in children: lipid-laden alveolar macrophage quantitation". *Pediatric Pulmonology* 3 (1987): 86-89.
19. Belpre JA, et al. "Chronic lung allograft rejection". *Proceedings of the American Thoracic Society - ATS Journals* 6 (2009): 108-121.
20. McKenzie B, et al. "Airway management for unilateral lung lavage in children". *Anesthesiology* 70 (1989): 550-553.
21. Tierney PA, et al. "Acquired subglottic cysts in the low birth weight, pre-term infant". *The Journal of Laryngology and Otolaryngology* 111 (1997): 478-481.
22. Sie KC, et al. "Subglottic hemangioma: ten years' experience with the carbon dioxide laser". *Annals of Otolaryngology and Laryngology: SAGE Journals* 103 (1994): 167-172.
23. Meeuwis J, et al. "Subglottic hemangiomas in infants: treatment with intralesional corticosteroid injection and intubation". *International Journal of Pediatric Otorhinolaryngology* 19 (1990): 145-150.
24. Hughes CA, et al. "Management of congenital subglottic hemangioma". *Journal of Otolaryngology* 28 (1999): 223-228.
25. Fischer-TruÈstedt C, et al. "Subglottische HaÈmangiome bei 46 Kindern, Klinikund Therapieergebnisse". *Monatsschr Kinderheilkd* 148 (2000): 304.
26. Cotton RT and Tew TL. "Laryngeal stenosis following carbon dioxide laser in subglottic hemangioma. Report of three cases". *Annals of Otolaryngology and Laryngology: SAGE Journals* 94 (1985): 494-497.

27. Garabedian EN, *et al.* "The carbon dioxide laser in tracheo-bronchial diseases in children. A prospective study of 11 cases". *Ann Otolaryngol Chir Cervicofac* 106 (1989): 206-209.
28. Rimell FL, *et al.* "Pediatric Fiberoptic laser rigid bronchoscopy". *Otolaryngology-Head and Neck Surgery* 114 (1996): 413-417.
29. Piedimonte G, *et al.* "Mediastinal lymphadenopathy caused by Mycobacterium avium-intra cellulare complex in a child with normal immunity: successful treatment with anti-mycobacterial drugs and laser bronchoscopy". *Pediatric Pulmonology* 24 (1997): 287-291.
30. Snoeck R, *et al.* "Treatment of severe laryngeal papillomatosis with intralesional injections of cidofovir". *Journal of Medical Virology* 54 (1998): 219-225.
31. Pransky SM, *et al.* "Intralesional cidofovir for recurrent respiratory papillomatosis in children". *Archives of Otorhinolaryngology-Head and Neck Surgery* 125 (1999): 1143-1148.
32. Shikowitz MJ, *et al.* "Efficacy of DHE photodynamic therapy for respiratory papillomatosis: immediate and long-term results". *Laryngoscope* 108 (1998): 962-967.

**Volume 3 Issue 8 August 2021**

© All rights are reserved by Md Atiar Rahman.