



A Paradoxical Intruder Disfiguring the Face: Nasal Benign Fibrous Histiocytoma

BP Belaldavar¹, Rajesh Radhakrishna Havaladar², Vijayalaxmi M Dhorigol³, Kavya Garg^{4*} and Sneha A Sankaran⁴

¹Department of ENT and Head and Neck Surgery, KAHER's J. N. Medical College, Belagavi, Karnataka, India and College of Medicine, Shaqra University, KSA

²Department of ENT and Head and Neck Surgery, KAHER's J. N. Medical College, Belagavi, Karnataka and Fellow - Head and Neck Oncosurgery, B.J. Government Medical College and Sassoon General Hospital, Pune, Maharashtra, India

³Department of Pathology, KAHER's J. N. Medical College, Belagavi, Karnataka, India

⁴Department of ENT and Head and Neck Surgery, KAHER's J. N. Medical College, Belagavi, Karnataka, India

***Corresponding Author:** Kavya Garg, Post Graduate Resident, Department of ENT and Head and Neck Surgery, KAHER's J. N. Medical College, Belagavi, Karnataka, India.

Received: April 24, 2021

Published: May 05, 2021

© All rights are reserved by **Kavya Garg., et al.**

Abstract

Benign fibrous histiocytoma is an uncommon presentation in the head and neck region. Composing of fibrous and histiocytic elements, these tumor are known to recur in almost a third of the cases if not excised completely. We hereby report a case of Benign Fibrous Histiocytoma (BFH) of the nasal dorsum completely removed by external approach. Although clinically the possibility of this diagnosis was not suspected, the procedure was tailor made right from the incision to excise the lesion in toto leading to no residual tumor or any morbidity. Knowledge of the possibilities of rare pathologies presenting as benign cysts should not be ignored in the head and neck.

Keywords: Benign Fibrous Histiocytoma; Nose; Head and Neck

Introduction

Benign Fibrous Histiocytoma (BFH) is known to have its origin from undifferentiated mesenchymal stem cells. These cells have the potential to differentiate into two different lineages: fibroblastic and histiocytic. The amount of these two variants differs greatly in different tissues [1].

The extremities, orbit, retro peritoneum, pelvis, knee and head and neck are areas that can be affected [2-4]. The examination findings may be suggestive of a pathology involving the nasal cavity, paranasal sinuses, oral cavity thus causing distortion of the symmetry of the face, proptosis or a periorbital mass [1]. In a series of

21 cases described by Fletcher in 1990, only one case was known to affect the subcutaneous face. The others involved other areas of the head and neck; involvement of the external nose near the dorsum has not been found to be reported in recent literature [5].

We hereby report an interesting case report of BFH at an unusual location in the head and neck that has not been known to be reported in recent literature.

Case Report

A 24 year old male patient presented with a swelling over the nose since 1 year. Initially it was of the size of a grain which gradu-

ally progressed to the present size as shown in image 1.

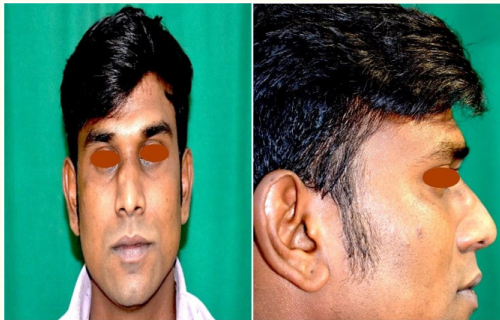

Image 1: Photographs showing the swelling over the right lateral side of nasal dorsum.

There was no history of trauma. Also, there were no complaints of nasal obstruction or discharge from the swelling.

On examination a solitary ovoid swelling was present on the right side over dorsum of the nose about 1.5 cm from nasojugal crease and at the junction of nasal bone and upper alar cartilage, measuring 1 x 0.5 cm which was not crossing the midline and not moving with respiration. It was non-tender with well-defined margins. Skin was pinchable. The slip-sign was positive and Furstenberg Test was negative. No altered perception of sensation over the dorsal tip area. Eye examination was normal.

Diagnostic nasal endoscopy did not reveal any intra nasal abnormality and there was no communication visualised from the swelling with the roof of the nasal cavity.

Ultrasonography of the external nose over the swelling revealed that the swelling was seen to arise from the subcutaneous plane. Computed Tomography plain and contrast did not reveal any intra-nasal communication and the lesion was reported to be localised to the dorsum of the nose. The patient underwent excision of the lesion through external approach and to our surprise 2 small cysts were visualized attached to each other with fibrotic bands in between. The whole mass was separated from the underlying nasal bone and the cephalic part of the upper cartilage which were found to be intact (Image 2A and 2B).

On Gross examination, the cut surface of the mass was not cystic as expected but solid and greyish pink. Histopathology confirmed a startling diagnosis of benign fibrous histiocytoma characterised

by presence of spindle cells arranged in short fascicles and vague storiform pattern, histiocytes admixed with multinucleated Touton giant cells in a background of few lymphocytes as seen in image 3a and 3b.

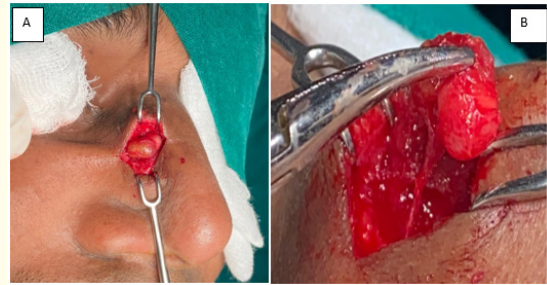

Image 2A and 2B: Intraoperative images.

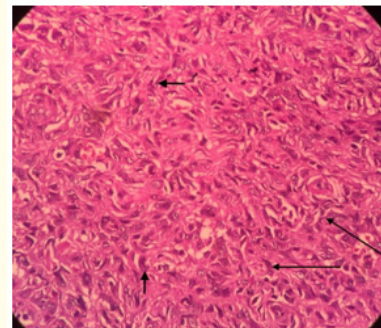


Image 3A: Benign fibrous histiocytoma: Spindle cells in vague storiform pattern (large arrow) and short fascicles (small arrow); (H&E Stain; x100).

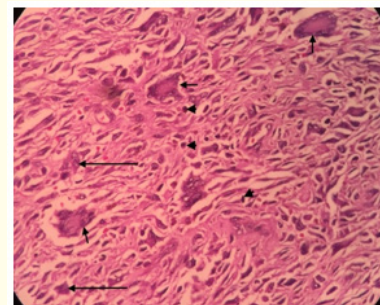


Image 3B: Benign fibrous histiocytoma: Multinucleate touton giant cells (Small arrow); histiocytes (Large arrow); lymphocytes (Arrow head). (H&E Stain; x100).

Ethical clearance

Patient consent and permission to use the clinical photographs and findings of the case for the purpose of scientific publication: Obtained.

Discussion

Benign fibrous histiocytoma (BFH) can involve bone, skin, mucosa and deeper soft tissues. The etiology is postulated to be either due to chronic infection, trauma or immunosuppression to name a few but its still a matter of considerable ambiguity [6,7]. The clinical presentation depends upon the location, time period and etiology [8].

Usually, it can occur at any age and there is some literature evidence that suggests that males are more commonly affected than females in a ratio of 2.5:1. Males above 25 years (mean age 40 years) are commonly affected [9].

The challenges faced while planning a complete excision of this mass began with the approach. Even though the histological diagnosis was not available before the surgery, as a matter of cosmetic concern, initially an open rhinoplasty approach was planned to excise the lesion [10].

However, since the lateral extent of the mass was clinically almost approximating with the frontal process of the maxilla and anticipating the possibility of incomplete excision of the mass, a direct incision approach was planned instead of open rhinoplasty approach in order not to transgress the nasal dorsal architectural structures and not to leave any residual part of the mass thus curtailing the possibility of recurrence.

As both soft and hard tissues can be sites for BFH, fibrohistiocytic tumours of the soft tissues are further classified as cutaneous and non-cutaneous varieties and those of the hard tissues are known as fibrohistiocytic tumours of the bone [9].

When histiocytes predominate it is called as a histiocytoma. A spectrum exists between the amount of fibrous tissue and histiocytes in a given lesion thus making it difficult to sub-classify these lesions. It has been discussed by Townsend, *et al.* [11] that histiocytes have the property to become fibroblastic which was characteristically observed in our case as well by the presence of dense fibrous tissue amidst the two small parts of the lesion as seen in image 2A and 2B.

Way back in 1990, Fletcher CD had described that histologically these lesions are usually better delineated from the ones that affect the skin. They are known to appear monomorphic and have a storiform pattern with occasional pericytoma like vascular pattern, xanthoma cells and multinucleate giant cells with hyaline or myxoid degeneration of the stroma. Occasionally small areas of necrosis might be seen [5].

BFH is less likely to recur if excised completely. When excised along with the underlying perichondrium or periosteum as done in this case could probably decrease the possibility of relapse [12]. Metastasis is rare and therefore the prognosis of a total excision is good [13]. Therefore, wide local excision with histological clear margins is preferred as the procedure of choice for such uncommon, unusual lesions presenting in areas with such least predilection such as the dorsum of the nose [14]. The fact that this mass was located over the nose and not at any other body part, carried significant importance from the aesthetic point of view. This has in fact made the patient present to the Otolaryngologist. Hence removal in toto with as much cosmetic care as possible is also a matter to be equally stressed upon as recurrence locally is something that cannot be afforded and would lead to detrimental results. The recurrence rate of BFH is about 31% when incompletely excised [15].

Conclusion

Mesenchymal tumors such as BFH composed of fibroblasts and histiocytes can very easily be misdiagnosed at the early stage. Although, the definitive diagnosis relies on histopathology of the lesion excised, the knowledge of such lesions existing although in a small number of cases in the head and neck region is of paramount importance to the novice head and neck surgeon in order to plan and tailor the incision keeping the sole moto of complete clearance of the disease thus preventing recurrence and the comorbidities associated with it.

Conflict of Interest

The authors declare that there is no conflict of interest.

Bibliography

1. Perzin Karl H and Yao-Shi Fu. "Non-Epithelial Tumors of the Nasal Cavity, Paranasal Sinuses and Nasopharynx: A Clinico-Pathologic Study XI. Fibrous Histiocytomas". *Cancer* 45.10 (1980): 2616-2626.

2. Fletcher CDM, *et al.* "Pathology and Genetics of Tumours of Soft Tissue and Bone". 3rd edition, 5, WHO Classification of Tumours IARC Publications (2002).
3. Singh B., *et al.* "Malignant fibrous histiocytoma of the head and neck". *Journal of Cranio-Maxillo-Facial Surgery: Official Publication of the European Association for Cranio-Maxillo-Facial Surgery* 21.6 (1993): 262-265.
4. Otsuka K., *et al.* "Treatment of mandibular malignant fibrous histiocytoma during pregnancy". *Journal of Oral and Maxillofacial Surgery: Official Journal of the American Association of Oral and Maxillofacial Surgeons* 59.2 (2001): 220-224.
5. Fletcher CD. "Benign fibrous histiocytoma of subcutaneous and deep soft tissue: a clinicopathologic analysis of 21 cases". *The American Journal of Surgical Pathology* 14.9 (1990): 801-809.
6. Skoulakis CE., *et al.* "Subcutaneous benign fibrous histiocytoma of the cheek. Case report and review of the literature". *Acta Otorhinolaryngologica Italica: Organo Ufficiale Della Societa Italiana di Otorinolaringologia e Chirurgia Cervico-Facciale* 27.2 (2007): 90-93.
7. Alonso del Hoyo J., *et al.* "Fibro-histiocytome de la cavité buccale [Fibrohistiocytoma of the oral cavity]". *Revue de Stomatologie et de Chirurgie Maxillo-Faciale* 77.2 (1976): 481-483.
8. Prasanna K. "Oral Benign Fibrous Histiocytoma - A Review of Literature from 1964-2016". *Advances in Dentistry and Oral Health* 8.5 (2018): 555748.
9. Prasanna Kumar D., *et al.* "Benign Fibrous Histiocytoma: A Rare Case Report and Literature Review". *Journal of Maxillofacial and Oral Surgery* 15.1 (2016): 116-120.
10. Xiao Zhixian., *et al.* "38-year-old woman with nasal congestion: A rare case of septum-originated benign fibrous histiocytoma". *Medicine* 98.23 (2019): e15815.
11. Townsend GL., *et al.* "Fibrous histiocytoma of the paranasal sinuses. Report of a case". *Archives of Otolaryngology (Chicago Ill: 1960)* 98.1 (1973): 51-52.
12. Yu XW., *et al.* "Pleomorphic adenoma of nasal septum: 5 cases reports and the literature review". *J Otolaryngol Eye Shand Univ* 27 (2013): 90-91.
13. Gleason Briana C and Christopher D M Fletcher. "Deep "benign" fibrous histiocytoma: clinicopathologic analysis of 69 cases of a rare tumor indicating occasional metastatic potential". *The American Journal of Surgical Pathology* 32.3 (2008): 354-362.
14. Soon Alexander K., *et al.* "Fibrous Histiocytoma of the Conjunctiva". *Ophthalmic Plastic and Reconstructive Surgery* 33.5 (2017): e133.
15. Font RL and Hidayat AA. "Fibrous histiocytoma of the orbit. A clinicopathologic study of 150 cases". *Human Pathology* 13.3 (1982): 199-209.

Assets from publication with us

- Prompt Acknowledgement after receiving the article
- Thorough Double blinded peer review
- Rapid Publication
- Issue of Publication Certificate
- High visibility of your Published work

Website: www.actascientific.com/

Submit Article: www.actascientific.com/submission.php

Email us: editor@actascientific.com

Contact us: +91 9182824667