



Facial Palsy: The Right Time for the Right Choice

Della Monaca M, Giorgio Barbera, Andrea Cassoni, Andrea Battisti, Paolo Priore, Ingrid Raponi*, Valentina Terenzi, Filippo Giovannetti and Valentino Valentini

Oncological and Reconstructive Maxillo-facial Surgery Department, Policlinico Umberto I, Sapienza University of Rome, Viale del Policlinico, Rome, Italy

***Corresponding Author:** Ingrid Raponi, Oncological and Reconstructive Maxillo-facial Surgery Department, Policlinico Umberto I, Sapienza University of Rome, Viale del Policlinico, Rome, Italy.

Received: November 20, 2020

Published: April 26, 2021

© All rights are reserved by **Ingrid Raponi, et al.**

Abstract

Aim: The aim of this study is to propose our experience and our protocol in post-operative facial palsy.

Methods: A retrospective study about 32 patients was done. Timing of the palsy onset, surgical indications and the results using Facegram were analyzed.

Results: The mean improvement for acute palsy evaluate with Facegram analysis of corner of the mouth excursion during smile was 41,30%. In the mid-term paralysis the measured improvement was 29,12%. Finally in the long - term facial palsy treated with functioning muscle transplantation was 34,30%.

Conclusion: Facial nerve reconstruction should be addressed routinely in every patient who undergoes facial nerve resection or develop palsy after otologic or brain surgery.

Keywords: Facial Palsy; Right Time; Right Choice

Introduction

Postoperative facial paralysis is not a rare event in head and neck surgery and is also observed relatively frequently after neurosurgical, oral and/or maxillofacial surgical procedures [1]. Resection of malignant head and neck tumors often requires extensive procedures or in the case of tumors located near the facial nerve, could also include facial nerve sacrifice [2]. The subsequent facial palsy is severely disabling by a functional point of view: patients have in fact disturbances in eye protection, eating and drinking. Other disorders that can affect the quality of life of these patients are psychological and aesthetic ones. Treatment of these kind of lesions requires a comprehensive understanding of the cause of the palsy, patient's characteristics and the timing of the onset of the paralysis [3]. In particular, the latter is the key point in the selec-

tion of the best treatment. In this article, the authors present their experience in the management of patients with postoperative facial paralysis.

Materials and Methods

From 2010 to 2015, 68 patients with unilateral facial palsy were admitted to our Department. Retrospective review of clinical chart was conducted. Sex, etiology of the palsy, time elapse from the onset of the palsy and follow-up were analyzed. In order to obtain powerful data, we admitted in this study patients who had a complete radiological documentation and with a follow up of 12 months at least. The outcome of the different surgical procedures administered, was objectified with FACEgram by analyzing the excursion of the mouth corner during the smile. FACEgram is a software de-

veloped at Massachusetts Ear and Eye Infirmary that automatically analyzes and compares face movements and key points in the opposite side of the face. To obtain consistent patient samples, we classified facial palsies based on the results of the electrophysiological study and the time elapsed from the onset of paralysis to the first surgical procedure administered. We defined as acute those paralysis treated within 72 hours of their onset: it is mainly caused by oncological resections. Other palsies, arisen from more than 4 months, were defined chronic facial paralysis. We further divided the latter group in two other classes based on the type of the surgical procedures administered; mid-term paralysis (less than 18 months) in which “baby-sitter” procedure was performed (cross facial nerve graft with sural nerve graft and masseteric-facial nerve cooptation) and long-standing paralysis (more of 18 months) in which a functioning free of pedicled muscle flap was used [3].

Results

From 2010 to 2015, 68 patients with unilateral facial palsy were admitted to our Department; 32 of these patients met inclusion criteria of our study. Patients population consists of 19 women (59,38%) and 13 men (40,62%). The etiology of the palsy was represented by 16 post acoustic neurinoma resections (50%), 6 post brain malignancies ablation (18,75%), 8 post parotid neoplasia resection (25%) and, finally, 2 post parotid benign lesion surgery (6,25%). Eleven patients with short-term palsy (34%) were treated with direct neurorrhaphy between the two facial stumps or, when this is not feasible, an interpositional graft was placed (Figure 1). In 13 patients with mid-term paralysis (41%), the “baby-sitter” procedure was performed (Figure 2). Finally, the 8 patients with long-term paralysis (8%) underwent facial reanimation with a functioning free or pedicled muscle flap (Figure 3). The mean improvement for acute palsy evaluate with Facegram analysis of corner of the mouth excursion during smile, was of 41,30%. In the mid-term paralysis the measured improvement was 29,12%. Finally, improvement in the long-term facial palsy treated with functioning muscle transplantation was of 34,30%.

Discussion

In facial nerve surgery the “TIME factor” is the most appropriate guide for rehabilitation procedures. This is due to the progressive and irreversible denervation atrophy which the facial mimic

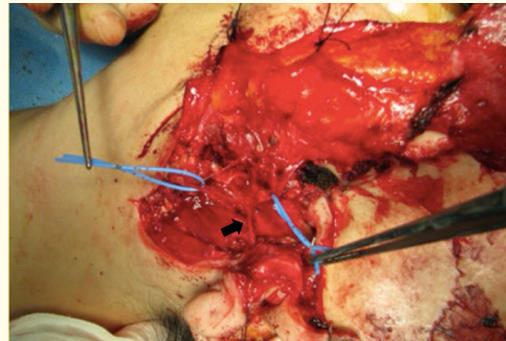


Figure 1: Intra-operative direct neurorrhaphy: blue vessel loops hold two of the branches of facial nerve (black arrow).

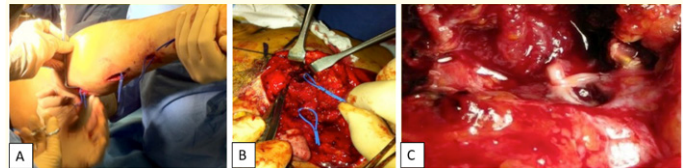


Figure 2: Intra-operative baby-sitting procedure. A: sural nerve harvest; B: blue vessel loops hold the masseteric nerve and the main trunk of the facial nerve; C: magnified view of the neurorrhaphy.

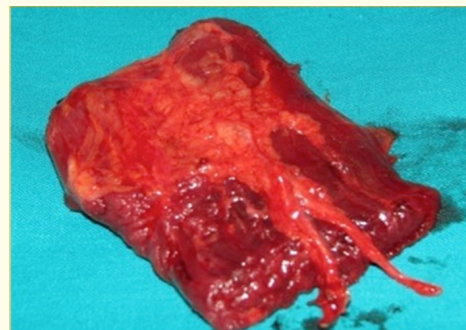


Figure 3: Gracilis free flap with its neuro-vascular pedicle.

muscles undergo day by day. A delay in treatment or an excessively wait-and-see therapeutic attitude, are the main factors negatively affecting the prognosis of facial nerve palsy. Immediate exploration and surgical repair is the best therapeutic option in cases where the facial nerve has an anatomical lesion, if there is no certainty of its integrity, or when must be dissected or sacrificed for oncological reasons. In these cases a direct tension free neurotomy or with an interpositional graft, should be considered the best therapeutic option to obtain a rapid recovery. Since muscle atrophy is different and unpredictable in each individual, mid-term paralysis still poses a challenge for functional facial surgery. These differences may be caused by residual contractions, synkinesis or different localization of the nerve damage. Nowadays the best surgical rehabilitative technique is the “babysitter” procedure introduced first by Terzis [4,5]. The original technique consisted in two distinct surgical times; nowadays, modern multiple reinnervation techniques are performed in a single surgical step in which the affected facial nerve is anastomosed with a facial branch on the healthy side, with the interposition of sural nerve graft and with the masseteric nerve of the affected side. In this way, the masseter nerve guarantees rapid recovery and the maintenance of good muscular trophism while the contralateral facial nerve guarantees emotional movement. The use of masseter nerve has been demonstrated to be safe with a low rate of complications [6]. According with our experience and our data, we believe that the baby-sitter procedure should be address within 12 - 14 months of the onset of the palsy; after that period, outcomes become more unpredictable and unsatisfactory [7]. When the paralysis has been present for more than 18 months (long-term paralysis) more complex procedures are required such as the transposition of pedunculated muscle flaps or the transplantation of free flaps [8,9]. Preoperative facial nerve weakness and advanced age are not contraindications to facial nerve repair. Furthermore, as recently demonstrated, postoperative radiotherapy does not appear to prevent successful recovery of facial function after rehabilitative surgery [10]. Finally, the authors want to emphasize the need to foresee a possible resection or damage of the facial nerve during some head and neck procedures to provide, where possible, a contextual nerve repair with the aim to guarantee better outcomes.

Conclusion

In conclusion facial nerve reconstruction should be addressed regularly in every patient who undergoes facial nerve resection or develops paralysis after ear, maxillo-facial or brain surgery.

Authors' Contributions

Barbera G and Della Monaca M and Valentini V: Conception and design of the study and data interpretation.

Raponi I, Terenzi V and Priore P: Made substantial contributions in data analysis and English revision.

Cassoni A, Battisti A and Giovannetti F: Performed data acquisition, as well as provided technical, and practical support.

Availability of Data and Materials

Data supporting our findings cannot be shared at the moment for temporary Institutional reason.

Financial Support and Sponsorship

None.

Conflicts of Interest

All authors declared that there are no conflicts of interest.

Ethical Approval and Consent to Participate

Not applicable.

Consent for Publication

Written informed consent was obtained for publication of intra-operative picture at the time of surgery.

Bibliography

1. Hohman MH and Hadlock TA. “Etiology, diagnosis, and management of facial palsy: 2000 patients at a facial nerve center”. *Laryngoscope* 124 (2014): 283-293.
2. Rivas A, et al. “A model for early prediction of facial nerve recovery after vestibular schwannoma surgery”. *Otology and Neurotology* 32 (2011): 862-863.
3. Bianchi A, et al. “Facial reanimation after nerve sacrifice in the treatment of head and neck cancer”. *Current Opinion in Otolaryngology and Head and Neck Surgery* 20 (2012): 114-119.

4. Terzis JK and Noah ME. "Analysis of 100 cases of free - muscle transplantation for facial paralysis". *Plastic and Reconstructive Surgery* 99 (1997): 1905-1921.
5. Terzis JK and Konofaos P. "Nerve transfers in facial palsy". *JAMA Facial Plastic Surgery* 24 (2008): 177-193.
6. Cassoni A., et al. "Masseter-facial neurotomy for facial palsy reanimation: What happens after masseter denervation? Histomorphometric and stomatognathic functional analysis". *Journal of Cranio-Maxillofacial Surgery* 48.7 (2020): 680-684.
7. Biglioli F., et al. "Mixed facial reanimation technique to treat paralysis in medium - term cases". *Journal of Cranio-Maxillofacial Surgery* 46.10 (2018): 868-874.
8. Hadlock T. "Evaluation and management of the patient with postoperative facial paralysis". *Archives of Otorhinolaryngology-Head and Neck Surgery* 138 (2012): 505-508.
9. Roy M., et al. "Effectiveness and safety of the use of gracilis muscle for dynamic smile restoration in facial paralysis: A systematic review and meta-analysis". *Journal of Plastic, Reconstructive and Aesthetic Surgery* 72.8 (2019): 1254-1264.
10. Yi CR., et al. "Quantitative analysis of the impact of radiotherapy on facial nerve repair with sural nerve grafting after parotid gland surgery". *Journal of Cranio-Maxillofacial Surgery* 48.8 (2020): 724-732.

Assets from publication with us

- Prompt Acknowledgement after receiving the article
- Thorough Double blinded peer review
- Rapid Publication
- Issue of Publication Certificate
- High visibility of your Published work

Website: www.actascientific.com/

Submit Article: www.actascientific.com/submission.php

Email us: editor@actascientific.com

Contact us: +91 9182824667