Acta Scientific Otolaryngology (ASOL)

Volume 1 Issue 2 October 2019

Research Article

Visual Outcomes and Factors Affecting the Outcome After Transsphenoidal Excision of Pituitary Macroadenoma

Heli H Vasani[1], Vaidik M Chauhan[2]*, Mitali Bharoliya[3], Kalpesh B Patel[4] and Jaimin K Shah[5]

[1]Third Year Resident, Department of ENT and Head and Neck Surgery, Civil Hospital, Ahmedabad, India

[2]Senior Resident, Department of ENT and Head and Neck Surgery, Civil Hospital, Ahmedabad, India

[3]Second Year Resident, , Department of ENT, B.J Medical College, Ahmedabad, India

[4]Associate Professor and Head of Unit-Department of ENT and Head and Neck Surgery, Civil Hospital Ahmedabad, India

[5]Associate Professor and Head of Department, Neurosurgery, Civil Hospital, Ahmedabad, India

***Corresponding Author:** Vaidik Chauhan, Senior Resident, Department of ENT and Head and Neck Surgery, Civil Hospital, Ahmedabad, India.

Received: September 06, 2019; **Published:** September 25, 2019

Abstract

Aims and Objectives: To study the visual outcome in patients operated for pituitary adenoma via transnasal trans sphenoidal endoscopic surgery.

Materials and Methods: From January 2015 to November 2017, 125 patients underwent surgical resection of pituitary adenoma via Transnasal Transsphenoidal Endoscopic approach at Civil Hospital, Ahmedabad performed by combined team of otorhinolaryngologic and neurosurgeon. From this we retrospectively collected the cases with visual impairment due to compression of optic chiasma by pituitary macroadenoma. We noted the MRI findings, Opthalmological Assessment was done of all the patients preoperatively. Post operative visual outcome was assessed.

Results: Visual acuity improved in 116 of 156 eyes (58 of 78 patients-74.35%), unchanged in 32 eyes (16 patients-20.51%) and worse in 8 eyes (4 patients -5.12%). Visual field improved in 120 of 156 eyes (60 patients), unchanged in 36 eyes (18 patients), worse in none. Factors such as age of the patient, tumor volume, pre-operative visual acuity, duration since the visual symptoms are significant contributors in affecting the post-operative visual outcome.

Conclusion: Endoscopic Transnasal Transphenoidal excision of pituitary macroadenoma has been effective in reducing the postoperative morbidity, hospital stay, tumor volume reduction due to recent advances in video endoscopic technology leading to better operative field during surgery. Post-operative visual outcome improvement shows effectiveness of this approach.

Keywords: Pituitary Macroadenoma; Transphenoidal Trannsnasal Endoscopic Approach; Visual Acuity; Visual Field; Perimetry; Optic chiasma

Introduction

Pituitary adenomas make up to 10 to 15% of intracranial tumour [1]. Visual disturbances associated with pituitary tumors depend on the tumor volume, location, and hormonal activity of the tumor as well as the position of the chiasma as it relates to the sella turcica [2-4]. Visual field testing is essential if there is suprasellar extension and the tumour reaches optic chiasm. Documentation of the visual fields will demonstrate if the tumour is causing visual impairment and provides a record which can be used to show the effects of surgery on the loss. Visual field defects, optic disc pallor, blurry vision, loss of colour vision, oculomotor disturbances are seen in these patients.

Transsphenoidal surgery in which surgeon enters sphenoid sinus and floor of sella turcica is now preferred in vast majority of the patients. Morbidity is significantly lower and has replaced transcranial, transfrontal approach due to better visual, neurological, masticatory function improvement [5].

Relation of pituitary gland to optic chiasm

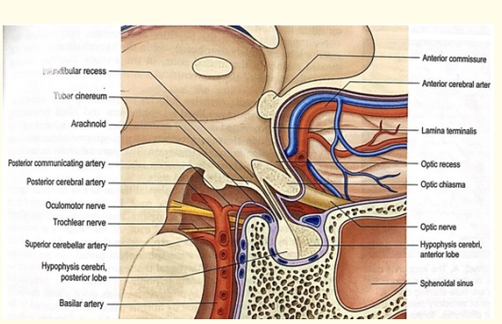

Figure 1: Anatomical relationship between pituitary gland and optic chasma.

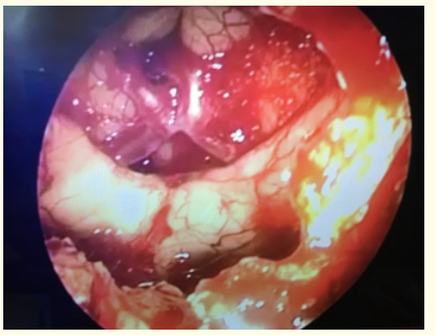

Figure 2: Intraoperative photo showing optic chiasm lying superiorly with anterior communicating artery.

The optic nerves, chiasm and tracts are closely associated with the pituitary gland. The nerves come from orbital apices between the anterior and middle clinoid processes on each sides, just above the carotids and merge as the chiasm anterior to the pituitary stalk. The chiasm then divides into the optic tracts, which pass either side of the stalk to head posterolaterally around the cerebral peduncles. The optic chiasm sits 12-14 mm above the sella turcica, therefore lesions of pituitary must reach in three dimension to cause visual symptoms [6].

Visual acuity, visual field testing, confrontation testing, pupillary reaction, optic disc pallor, ocular movements were measured pre-operatively and post operatively. The pituitary adenomas with suprasellar extension, their volume, duration of visual impairment pre-operatively and their correlation with improvement in visual function post operatively was measured.

Materials and Methods

From January 2015 to November 2017, 125 patients underwent surgical resection of pituitary tumours via Transnasal Transsphenoidal Endoscopic approach at Civil Hospital, Ahmedabad performed by combined team of otorhinolaryngologist and neurosurgeon. From this we retrospectively collected the cases with visual impairment due to compression of optic chiasma by pituitary macroadenoma.

Inclusion criteria

- Preoperative visual impairment (defined by decreased visual acuity, visual field impairment)
- Histologically proven pituitary adenoma postoperatively
- Pre and post operation MRI and visual status available

Exclusion criteria

- Patients with ocular media opacities, cataracts, glaucoma, optic neuritis, or pathologies affecting visual field
- Unfit patients for ocular examination

Among 125 patients 86 patients had visual impairment and 78 patients met our inclusion criteria. 42(53.84%) patients were males and 36(46.15%) patients were females (sex ratio:1.166) mean age at surgery was 50.02(46.77-53.27), all tumors were macroadenomas (>10mm).

Radiological examination

Preoperative MRI was done for evaluation of the size of the pituitary adenoma and a CT scan was also done to preoperatively study nasal fossa, sinus and skull base anatomy and for surgical navigation guidance. The measurement of 3 tumour diameters - width, length and height, and the formula 0.5~ width x length x height also provided an adequate estimation of the tumour volume which was symmetrical. Tumor which is irregular in shape volume can be calculated based on MRI measurements, using an ellipsoid model (volume = $4/3 \times \pi \times 1/2\ d1 \times 1/2\ d2 \times 1/2\ d3$) where d1, d2 and d3 are the maximum tumor diameter in the orthogonal spatial axes [7].

Ophthalmological examination

Visual acuity

Visual acuity is an indicator of retinal function and is an appreciation of form sense. Patient is asked to read Snellen's test types at 6 m line and his visual acuity is recorded, if he can't see top line he is asked to move towards the chart and distance at which he is able to read is recorded as 5/60,4/60,3/60,2/60. If he is not able to read at 1m,he is asked to count finger, when he fails that he is asked to appreciate hand movements and when he isn't able to appreciate that perception of light is tested [8].

Visual field

The extent of normal visual field is superiorly 500,nasally 600,inferiorly 700 and temporally 900. Perimetry with red colour object is particularly useful in chiasmal compression. Perimetry is the procedure of choice. Automated perimetry test visual field by static method which involves presenting a stimulus at a predetermined position for a present duration with varying luminance [9].

Procedure

All the patients had a visual evaluation preoperatively and one week and 3 months postoperatively including measurement of visual acuity (VA) and/or visual field (VF) by The Octopus TM automated perimeter consisted of a hemispheric screen of 0.5 m radius upon which a stationary Goldmann III target was projected in a randomized sequence. The threshold level of stimulus intensity at which the patient identified the target was recorded at fixed intervals across a designated region of the visual field. Before each perimetric examination, the illumination of the background was standardized. The 76 test points (Program 31 or 33) within the central 30° field were spaced at 6° intervals and intersected both the horizontal and vertical meridians; appropriate near correction was used. Using the Delta program supplied with the Octopus, fields were analyzed statistically by quadrants, deleting the physi-

ological blind spot.. VA impairment was expressed snellen notation as well as in LogMAR notation(LogMAR 0 corresponding to a perfect vision and LogMAR 2.0 to a very low vision). Improvement in visual acuity was defined as a difference of at least 0.3 in logMAR notations.

Ranges of vision loss	Visual acuity			Linear scales
	Decimal	U.S. notation	6 m notation	Log MAR
Range of normal vision	1.6	20/12	6/4	-0.2
	1.25	20/16	6/5	-0.1
	1.0	20/20	6/6	0
	0.8	20/25	6/7.5	0.1
Mild visual impairment (near normal Vision)	0.63	20/32	6/10	0.2
	0.5	20/40	6/12	0.3
	0.4	20/50	6/15	0.4
	0.32	20/63	6/18	0.5
Moderate visual impairment	0.25	20/80	6/24	0.6
	0.2	20/100	6/30	0.7
	0.16	20/125	6/36	0.8
	0.125	20/160	6/48	0.9
Severe impairment	0.1-0.06	20/200-20/300	6/60	1.0-1.2
	0.05	20/400	3/60	1.3
Profound impairment	0.04-0.02	20/500-20/1000	2/60	1.4-1.7
Near blindness	Less	Less	1/60 or less	1.8-1.9
blindness	0.0	NLP	NLP	2.0

Table 1: Ranges of visual acuity loss (ICD-9,ICD-10, ICD-9 CM) [10,11].

SIPAP classification for suprasellar pituitary tumour extension [12].

- **Grade 0:** No bulging of the adenoma into the suprasellar space. The outline of the diaphragm of the sella is smooth.
- **Grade 1:** The adenoma bulges upwards into the suprasellar cistern but without reaching the optical chiasm.
- **Grade 2:** It reaches the optical chiasm but without displacing it.
- **Grade 3:** The adenoma displaces and usually stretches the chiasm to a variable degree. The anterior part of 3rd ventricle is obliterated more or less as the tumour deforms and elevates its anterior floor. The anterior horm of the lateral ventricles may be partially compressed, but there is no hydrocephalus caused.
- **Grade 4:** Obstructive hydrocephalus of one or both lateral ventricles caused by tumour extension due to compromised CSF flow through foramen of Monro.

Visual function-anatomic relationships suggest that tumor extension 10 mm above the diaphragm sellae is necessary for anterior visual pathway to get affected. Visual recovery occurs due to decompression effect of surgery, it occurs in three phases. In the first phase which is seen after one week of surgery improvement is seen due to better nerve conduction, second phase seen in 6 months postoperatively recovery occurs due to remyelination changes, third phase improvement which is seen after a year of surgery occurs as these changes persists over time [13].

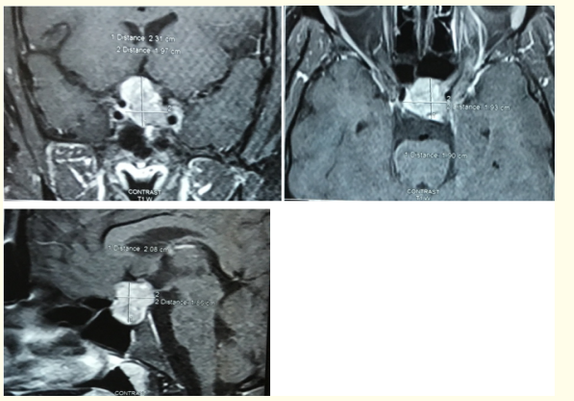

Figure 3: Preoperative MRI showing auprasellar extension of pituitary macroadenoma.

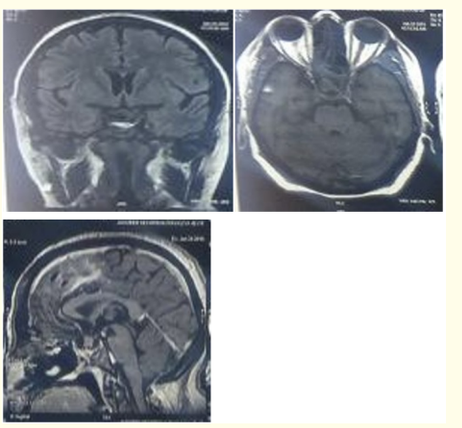

Figure 4: Postoperative MRI done after endoscopic transnasal transphenoidal excision.

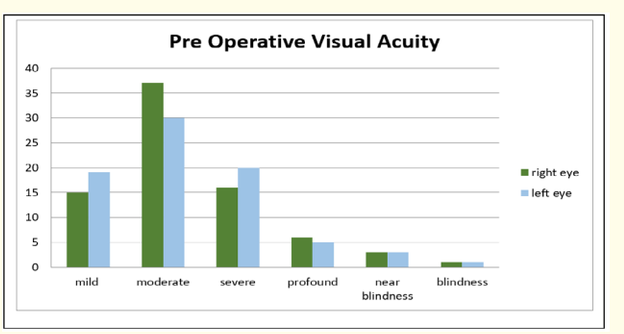

Chart 1: Preoperative visual acuity.

Results

Tumor volume

Pre-operative tumor volume was 11.00 ± 8.88 cm^3 (p<0.001). Post-operative tumor volume was 4.87 ± 3.88 cm^3 (p<0.001). More than 70% reduction of the tumor volume was achieved in 68% of the cases and near total tumor resection (>90%tumor volume reduction) was achieved in 28% of the total cases.

Visual acuity and visual field post-operatively

Visual acuity improved in 116 of 156 eyes (58 of 78 patients-74.35%), unchanged in 32 eyes (16 patients-20.51%) and worse in 8 eyes(4 patients -5.12%). Macroadenomas typically start compressing the crossing fibers of the chiasm first, creating the typical bitemporal hemianopsia. VA changes are caused by compression of the macular fibers at a later stage of the disease [14,15].

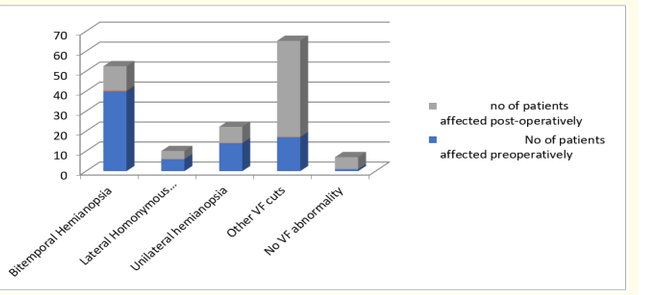

Chart 2: Types of visual field defect pre-operatively and post-operatively.

Number of EYES	Pre-operative VA	VA immediate post-op	VA after 3 months	VA after 6 months	VA after 1 year
16	6/24	6/12	6/12	6/12	6/12
12	6/18	6/18	6/18	6/18	6/18
16	6/36	6/36	6/36	6/36	6/36
50	6/48	6/24	6/18	6/18	6/18
30	6/60	6/48	6/48	6/36	6/36
4	6/60	6/60	6/60	6/60	6/60
10	2/60	6/60	6/60	6/60	6/60
4	HM	CF	CF	CF	CF
2	PL	HM	HM	HM	CF
2	NLP	PL	PL	HM	HM
2	6/12	6/60	6/60	6/48	6/24

Table 2: Preoperative and postoperative visual acuity.

Visual field improved in 120 of 156 eyes (60 patients), unchanged in 36 eyes (18 patients), worse in none.

Factors affecting the outcome

- Preoperative visual status-Eyes that had VA better than 6/48 showed better results postoperatively -89% of these eyes reported improvement while only 60% eyes with VA less than 6/60 showed good results postoperatively.
- Age-younger patients had better results postoperatively, this was not related to the fact that old patients had poor eye status as young patients with worse preoperative visual status also showed better outcome than older patients [14].
- Duration-patients with duration of visual symptoms for less than 6 months fared better (88% of this patients achieved improved VA) than patients with visual symptoms for more than 6 months (68% of this patients achieved improvement post operatively) [15].
- Preoperative visual field cut without loss of visual acuity showed better prognosis.
- Patients with visual field defects had mean suprasellar extension of 14.5mm (12.5-16.5).

Limitations

In our study we did measurement of visual field defect separately for each eye which does not give accurate measurement of binocular visual field. We also used static perimetry instead of kinetic perimetry.

Conclusion

Neurosurgical approach to pituitary tumors evolved from the microscopic approach to the endoscope assisted, and lastly to pure endonasal endocopic approaches. In the context of pituitary tumors, it has revolutionized the extent and quality of the visualization and increased the limits of surgical access to the sella and suprasellar area. The perceived limitations of the endoscopic approach such as the existence of a learning curve, and the two-dimensional vision of the endoscope can be easily overcome by working in a multidisciplinary team [16]. The endoscopic approach has been shown to be having a significantly higher gross total resection rate when compared with microscopy, particularly for pituitary tumors with cavernous sinus invasion [17], and fewer recurrences as well as better visual outcomes.

Bibliography

1. Juraschka K., *et al*. "Endoscopic Endonasal Transsphenoidal Approach to Large and Giant Pituitary Adenomas: Institutional Experience and Predictors of Extent of Resection". *Journal of Neurosurgery* 121 (2014): 75-83.
2. Kapoor S Acromegaly. *The New England Journal of Medicine* 356 (2007): 1274-1275.
3. Lee JP., *et al*. "The volume of tumor mass and visual field defect in patients with pituitary macroadenoma". *Korean Journal of Ophthalmology* 25 (2011): 37-41.
4. Kan E., *et al*. "Visual field defects in 23 acromegalic patients". *International Ophthalmology* 33 (2013): 521-525.
5. Koutourousiou M., *et al*. "Endoscopic Endonasal Surgery for Giant Pituitary Adenomas: Advantages and Limitations". *Journal of Neurosurgery* 118 (2013): 621-631.
6. Gulsen S., *et al*. "Characterization of the anatomic location of the pituitary stalk and its relationship to the dorsum sellae, tuberculum sellae and chiamatic cistern". *Journal of Korean Neurosurgery Society* 47 (2010): 169-173.
7. Davies BM., *et al*. "Assessing Size of Pituitary Adenomas: A Comparison of Qualitative and Quantitative Methods on MR". *Acta Neurochirurgica* (Wien) 158 (2016): 677-683.
8. Levenson JH and Kozarsky A. "Visual Acuity". In: Walker HK, Hall WD, Hurst JW, editors. Clinical Methods: The history, Physical, and Laboratory Examinationa, 3rd Edition, Boston: Butterworths (1990).
9. Spector RH. "Visual Fields". In: Walker HK, Hall WD, Hurst JW. Clinical Methods: The History, Physical, and Laboratory Examinations. 3rd Edition, Boston: Butterworth (1990).
10. Visual standard-Aspects and Ranges of vision loss ICO report –Sydney ; April 2002 table 3 Ranges of Visual Acuity loss in ICD-9, ICD-10 in ICD-9-CM.
11. Visual standard-Aspects and Ranges of vision loss ICO report –Sydney ; April 2002 table Ranges of field loss And O and M ability table 7.
12. L Edal., *et al*. "SIPAP: A new MR classification for pituitary adenomas". *Acta Radiologica* 38 (1997): 30-36.
13. Kerrison JB., *et al*. *American Journal of Ophthalmology* 130 (2000): 813-820
14. Barzaghi LR., *et al*. "Prognostic factors of visual field improvement after trans-sphenoidal approach for pituitary macroadenomas: Review of the literature and analysis by quantitative method". *Neurosurgery Review* 35 (2012): 369-378.
15. Dutta P., *et al*. "Visual outcome in 2000 eyes following microscopic transphenoidal surgery for pituitary adenomas: Protracted blindness should not be a deterrent". *Neurology India* 64 (2016): 1247-53.
16. Schaberg MR., *et al*. "Microscopic versus endoscopic transnasal pituitary surgery". *Current Opinion in Otolaryngology and Head and Neck Surgery* 18 (2010): 8-14.
17. Dhandapani S., *et al*. "Cavernous sinus invasion in pituitary adenomas: Systematic review and pooled data meta-analysis of radiological criteria and comparison of endoscopic and microscopic surgery". *World Neurosurgery* (2016).

Volume 1 Issue 2 October 2019