



Endoscopic Ear Surgery- A Study of 50 Cases

Vaidik M Chauhan^{1*} and Rajesh Vishwakarma²

¹Senior Resident, Department of ENT Head and Neck Surgery, B.J Medical College, Civil Hospital Ahmedabad, India

²Professor and Head, Department of ENT Head and Neck Surgery, B.J Medical College, Civil Hospital Ahmedabad, India

***Corresponding Author:** Vaidik M Chauhan, Senior Resident, Department of ENT Head and Neck Surgery, B.J Medical College, Civil Hospital Ahmedabad, India.

Received: August 21, 2019; **Published:** September 06, 2019

Abstract

Introduction: It has been in the last three decades that the ENT specialty has developed rapidly. New technology has made surgery minimally invasive, safe and able to achieve excellent results. With surgical methodologies moving towards minimally invasive technique and smaller incision, surgery may lessen the hands on approach with which we are familiar, but this will benefit patients care and reduce inpatients stay.

Objective: We describe our initial experience with endoscopic ear surgeries and to clear the ventilation routes of middle ear with better visualization of anatomy, to evaluate operative time, healing time, to evaluate postoperative hearing improvement, to study graft taken up rate.

Material and Method: In this Prospective trial done All patients with tympanic membrane perforation attending ENT OPD Civil Hospital Ahmedabad in whom Endoscopic Ear Surgery was planned, during December 2015 to December 2017 were selected for the study. Firstly a complete ENT examination was done to arrive at the correct diagnosis. Then eligible patients for tympanoplasty were subjected to endoscopic tympanoplasty procedures. The pure tone audiometry of the patients was done both preoperatively and in follow up periods.

Result: In our study most common age affected was 17-30 yrs, commonest symptoms was Otorrhea. The mean average air- bone conduction gap is 28dB. All patients underwent endoscopic tympanoplasty we found that there is 88% graft taken up rate, with an average operative time was 60 to 90 min. No major complication observed in study and average post-operative healing time is between 30 to 40 days.

Conclusion: The main story of endoscopic ear tympanoplasty is that of the re- discovering of the ear canal as the most logical, direct, and natural access point to tympanic membrane and middle ear cleft. Endoscopic ear surgery preserves much of normal anatomy as possible by minimizing unnecessary dissection of bone and soft tissue. Wide angle, and magnified view provided by endoscope and ability to easily negotiate through EAC and provide uninterrupted image overcomes most of the disadvantage of microscope. In terms of morbidity and postoperative recovery endoscope produced promising results. Thus, Endoscopic tympanoplasty can be a good alternative of microscopic tympanoplasty.

Keywords: Tympanoplasty; Endoscope; CSOM; Temporalis Fascia

Introduction

It has been in the last three decades that the ENT specialty has developed rapidly. New technology has made surgery minimally invasive, safe and able to achieve excellent results.

With surgical methodologies moving towards minimally invasive technique and smaller incision, surgery may lessen the hands on approach with which we are familiar, but this will benefit patients care and reduce inpatients stay.

The introduction of the binocular operating microscope was a landmark in modern otology as it changed the scope and character of ear surgery.

The endoscope offers a new perspective of cholesteatoma and related surgical procedures; it increases the surgeon's understanding of the disorder and its extension through the temporal bone and provides a wide field of view of the middle ear compared to the microscope.

Even though it has been two decades since endoscopy was first used to explore mastoid cavities, the endoscope is used infrequently for surgical management of ear disease; most otologists have not felt compelled to master the newer endoscopic techniques.

In addition, there has been a focus on using smaller diameter endoscopes for ear surgery which is counter-productive, as it eliminates the main (and possibly only) advantage of endoscopy *i.e.* wide field of view compared to that of the microscope.

Aims and Objective

We describe our initial experience with endoscopic ear surgeries and to clear the ventilation routes of middle ear with better visualization of anatomy, to evaluate operative time, healing time, to evaluate postoperative hearing improvement, to study graft taken up rate.

Material and Methods

Source of data

All patients with dry central perforation attending the OPD at Civil Hospital, Ahmedabad who had wide external auditory canal during December 2015 to December 2017.

- Sample size: 50 CASES
- Selection criteria.

Inclusion criteria

1. All patients with Inactive mucosal type with healthy middle ear mucosa.
2. Inactive Mucosal type (COM) with conductive hearing loss
3. Patient having wide external auditory canal - (without pulling pinna you can see whole of tympanic membrane and external auditory canal).

Exclusion criteria

1. Patients having a active mucosal type COM with unhealthy mucosa
2. Suspected ossicular disease and extensive cholesteatoma.
3. Patients having narrow external auditory canal- (in which even after pulling pinna backward, upward cannot see external auditory canal and tympanic membrane).

Method of collection of data

- All patients with tympanic membrane perforation attending ENT OPD Civil Hospital Ahmedabad in whom Endoscopic Ear Surgery was planned, and who were willing to undergo the surgery, during December 2015 to December 2017 were selected for the study. Firstly a complete ENT examination was done to arrive at the correct diagnosis.
- Then eligible patients for tympanoplasty were subjected to endoscopic tympanoplasty procedures.
- The pure tone audiometry of the patients was done both preoperatively and in follow up periods after 3 months.

Instruments

0-degree, 30 degrees and 2.7 mm diameter, 160mm working length rigid oto-endoscope. used. The recording equipment consisted of an endoscopic camera which was connected to the endoscope, a Television Monitor and an external video grabber card which was used to record the procedure. The monitor was placed on the other side of the table, across the patient's head. All the procedures were performed directly seeing the monitor.

- Routine ear surgery and Curved Suction elevator instruments were used.

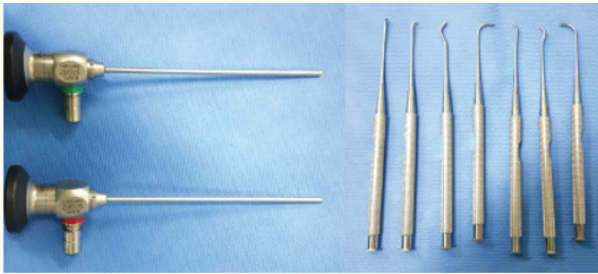


Figure 1: 0 And 30 degree oto-endoscope with curved suction elevators.

Surgical technique

Parts preparation

For the patients in whom

- Tragal Cartilage graft was planned - No shaving of the mastoid region.
- Temporalis fascia graft was planned- shaving of mastoid region only 1 inch above hairline.
- Facia lata graft was planned – Shaving of lateral side of thigh of opposite side of operating ear.
- In every patient graft was taken in randomized bases.

Premedication

The patient was premedicated half an hour prior to the procedure with 30mg Pentazocine, 25mg Phenergan and 0.6mg Atropine given intramuscularly.

All procedures were performed under Local Anesthesia.

Position of the patient

The patient was placed in the supine position with the head partially rotated to the opposite side. Endoscopy can be done either single handed technique or double handed technique.

In double handed technique the endoscope was held by the endoscope holder justtache as shown in figure.

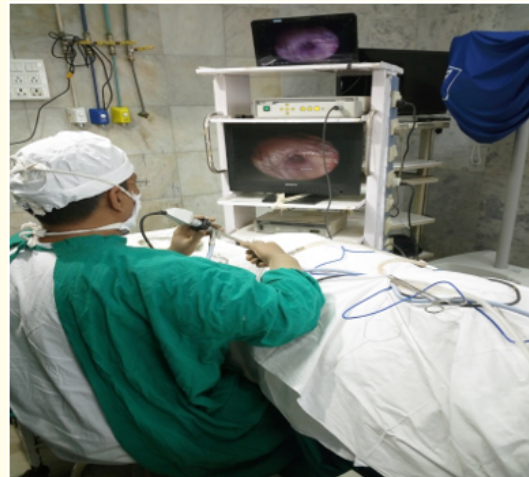

Figure 2: One handed Technique.



Figure 3: For 2 handed technique Justtache endoscope holder.

Infiltration

The postauricular and canal infiltration with 2% Xylocaine with 1: 2,00,000 adrenaline The canal wall infiltration was done under Endoscopic guidance using a 2ml syringe with 26 gauge lever lock needle with the terminal 1 cm angulated towards the bevel.

Harvesting of graft

For the closure of Tympanic membrane perforation, following types of Grafts were used

- Temporalis fascia autograft: In most of the patients the approx 1 inch horizontal temporal incision above the hairline was used so that the postoperative scar due to the incision was hidden behind the hair.
- Tragal Perichondrium
- Fascia lata

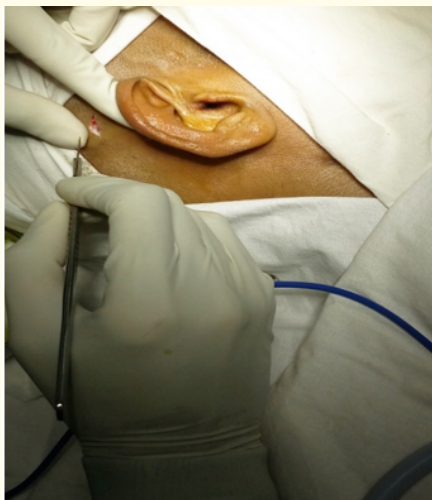

Figure 4: 1 cm Incision for temporalis fascia.

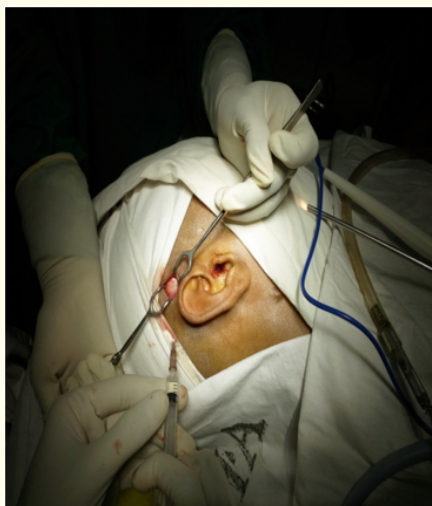

Figure 5: Taking Temporalis graft.

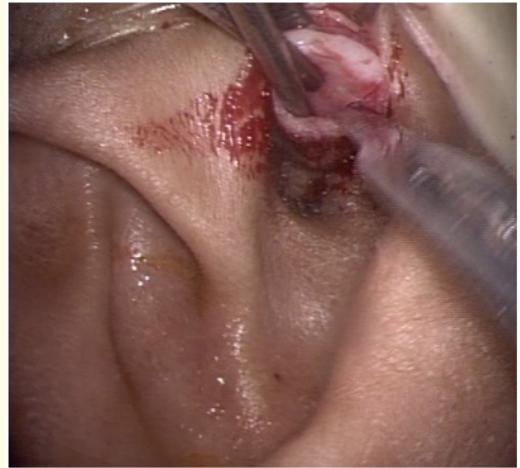


Figure 6: Taking Tragal Cartilage graft.

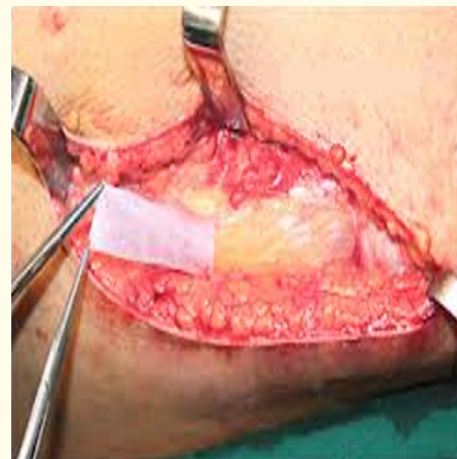

Figure 7: Fascia lata graft.

Inspection

The Endoscope was introduced into the external auditory canal. Any difficulty in introduction of the Endoscope was noted. Also, any obstruction to the vision was noted. The Tympanic membrane with its perforation was visualized. Middle ear was examined through the perforation.

Freshening of the perforation margins

Freshening of the perforation margins was done using a wide curved pick.

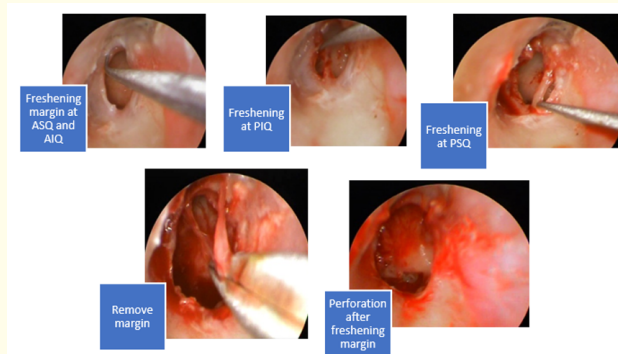


Figure 8: Freshening of margin.

Incision and flap elevation

A 11 O'clock to 1 o'clock incision was taken in the posterior canal wall skin about 5mm away from the annulus. The Tympanomeatal flap was elevated as follows

- In the patients in whom Overlay method of Tympanoplasty was used, the external auditory canal skin along with the Epithelium covering the Tympanic membrane was elevated as a single flap.
- In the patients in whom Underlay method of Tympanoplasty was used, the external auditory canal skin along with the Epithelium and the fibrous layer of the Tympanic membrane were elevated as a single flap preserving the mucosa on the inside.

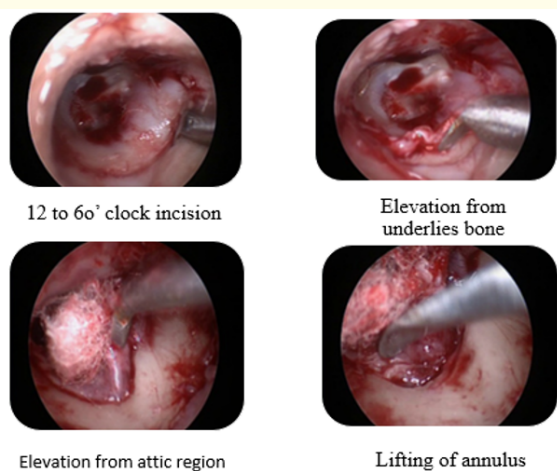


Figure 9: Elevation of flap.

(Figure 9)

Middle ear inspection

The middle ear findings were noted with reference to the following

State of the Ossicles i.e. Malleus, Incus and the Stapes. State of the Incudomalleal and Incudostapedial joints. The Eustachian tube opening, the oval and the round windows, the facial recess and the sinus tympani were also visualised. The round window reflex was visualized to confirm the continuity of the ossicular chain.

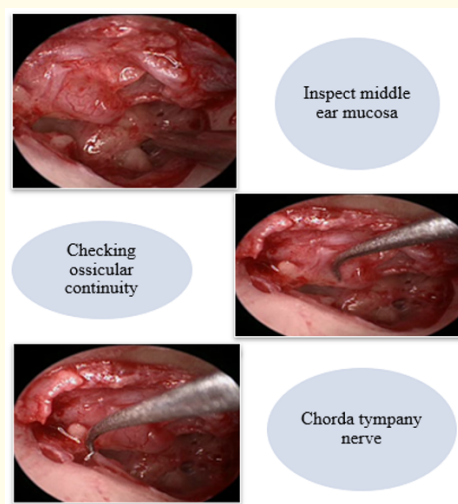


Figure 10: Middle ear inspection.

Graft placement

- In underlay technique, the graft is placed under the fibrous layer hugging the handle of malleus.
- In overlay technique, the graft is placed over the fibrous layer hugging the handle of malleus.

Repositioning the tympanomeatal flap

The flap is repositioned to its original position and margins placed in approximation circumferentially. Gel foam pieces soaked in antibiotics are placed over the skin flap to keep the skin in approximation to graft. Only a small dressing was given to cover the external auditory canal. The patients were put on oral antibiotics and analgesics for one week. The patients were discharged the same evening. Supra auricular sutures were removed on the tenth postoperative day.

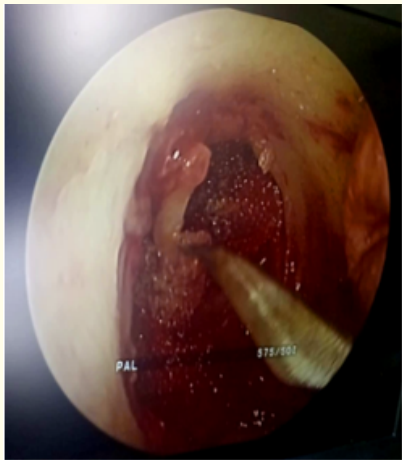


Figure 11: Packing with Gel foam.

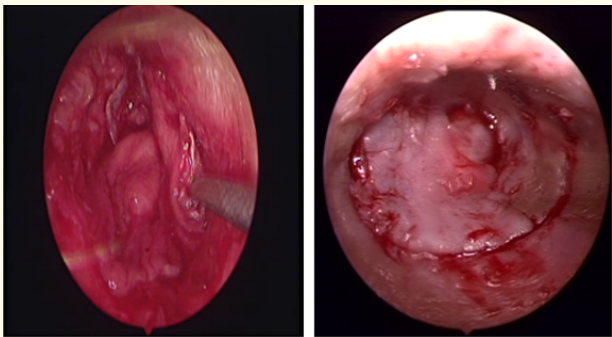
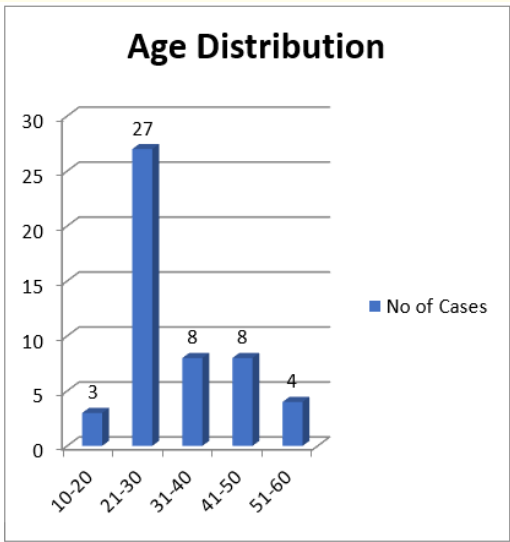


Figure 12,13: Graft placement of temporalis fascia and tragal cartilage.

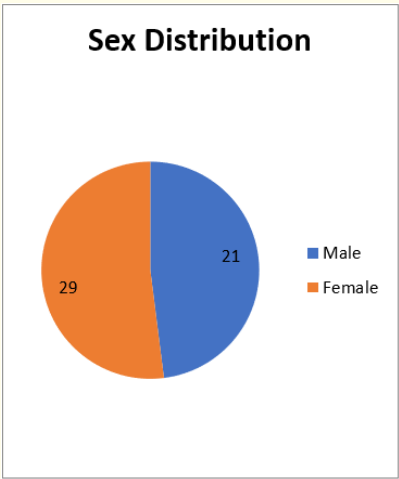


Chart 1,2

Observations and Results

Age and Sex distribution (Chart 1 and 2)

As seen in table I and chart I majority of the patients fall within the age group of 21-30 years.

Size of perforation and mean hearing loss as seen in chart 3 and chart 4 most of the patients had medium sized of perforation.

- **Small Perforation:** Involving one quadrant of tympanic membrane only.
- **Medium Perforation:** Involving two quadrants of tympanic membrane only.
- **Large perforation:** Involving more than two quadrants of tympanic membrane only.

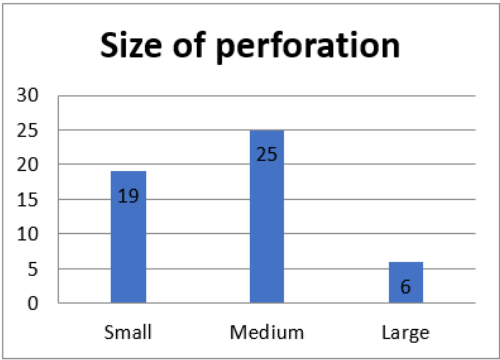


Chart 3

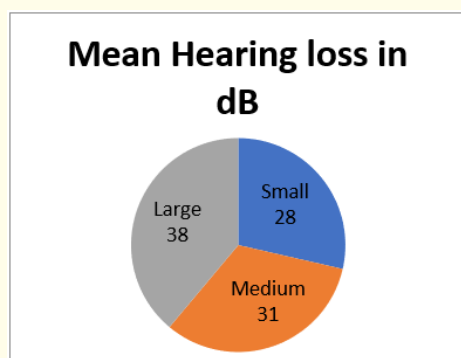


Chart 4

Graft materials as seen in chart 5 Most of patients tragal perichondrium was used as graft followed by temporalis fascia and then fascia lata.

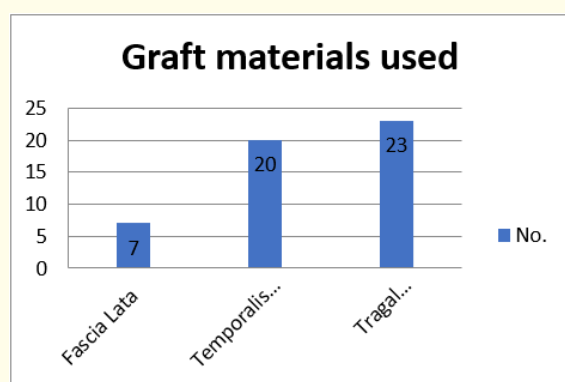


Chart 5

Graft wise hearing improvement

Maximum improvement in hearing was achieved in patient whom fascia lata were used as a graft followed by temporalis fascia and tragal perichondrium.

Difference in hearing loss between pre-op and follow up stage is statistically highly significant (P value <0.01) Actual p value: 8.6E-31 by paired t-test.

Correlation of the size of the perforation with the graft take up rate (Chart 7).

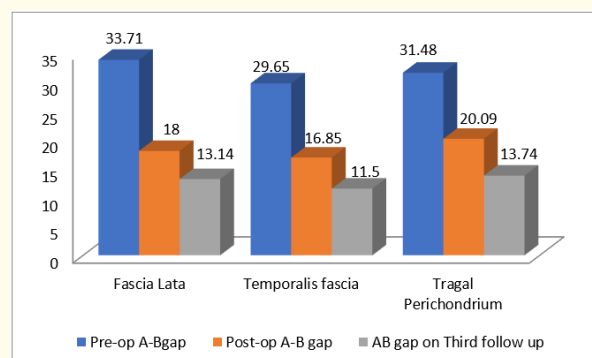


Chart 6: Graft wise hearing improvement.

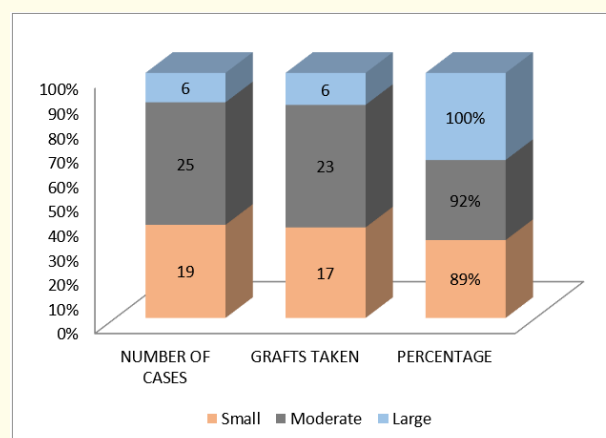


Chart 7

As seen in graph and we found that the graft take rates were 100% with large perforations (in all the 6 of the 6 perforations). In 23 of the 25-medium sized perforation the graft took well amounting to 92% whereas in only 17 (89%) out of 19 small perforation the graft took fully.

Technique vs graft take (Chart 8)

Success rate of endoscopic ear surgery (Chart 9)

Failures and complications

In our study of 50 cases of endoscopic ear surgeries we have had four case of graft failure. Two of these four patients had persistent otorrhea, one had uncontrolled diabetes, and other one had accidental ear injury so graft failure occurred.

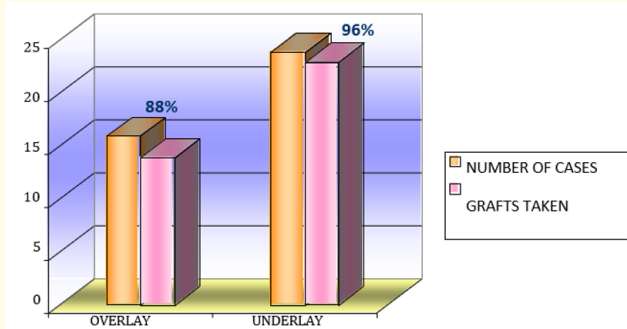


Chart 8

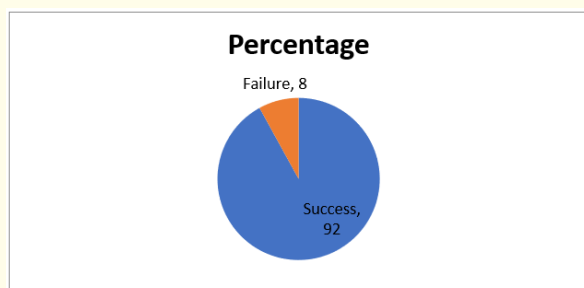


Chart 9

Discussion

Preliminaries

Age

70% of our patients were aged between 10-30 yrs. This is consistent with the occurrence of chronic suppurative otitis media.

Sex

Male: Female ratio was 1:1.1

Advantages of endoscopes

1. One will see through the T.V. monitor so the magnification is very high.
2. As the surgeon sees the monitor there is no neck strain.
3. The assistant and the observers are also seeing the same image as the surgeon.

4. When somebody is operating under guidance, the guide knows what is exactly going on and can specifically guide that step of the procedure on the monitor. So it is a good teaching and learning device.
5. Recording on VCR or on computer is possible. This helps in self-learning keeping records, in presentations and in convincing patients for surgery.
6. The wide angle vision is possible just by withdrawing the scope, while close up magnified vision is possible by just going closer.
7. Vision beyond the shaft of the instruments is possible so instruments do not interfere with the vision like in the microscope.
8. Angled scopes and also tilting and angling of the scopes helps in visualizing areas not in axis of the ear canal. So one can visualize recesses in the canal wall.
9. Thus the hidden areas which are exposed by the endoscopes are as follows: Sinus tympani, Facial recess, attic, anterior recess, and Eustachian tube and the ossicular chain
10. There is no need of repeated tilting of the head or repeated adjustments like in the microscope.
11. When shifting from one area to the other like in elevation of flap, it gives a continuous movie camera type of picture by moving easily to the site of interest in contrast to static vision of the microscope.
12. The mobility of the endoscopic camera is much better than a microscope with its fixed heavy stand. So one can carry it anywhere for surgery along with a portable T.V.
13. The young budding E.N.T. surgeon can use the endoscope camera setup for all his nasal and otologic surgery thus avoiding the need for the initial additional investment on a costly microscope.

Overcoming disadvantages of endoscope

The disadvantages of the endoscope can be overcome as follows:

1. Bleeding and the frequency of suction is avoided by- Proper preoperative preparation to make the ear dry. Using more adrenaline.

2. Fogging of the scope by the blood in the ear canal is avoided by repeated dry cotton balls cleaning of the ear and by repeated dipping in saline solution.
3. The caloric effect by xenon light source and the powerful 300 watts bulb is more.
4. This can be overcome by lesser light intensity 150 watts bulb, using intermittently when needing close-up vision, by repeated dip in saline and finally by using the scope at a distance. The weight of the camera is not so much. Using a stand would reduce maneuverability namely, close-up to wide angle, continuous movie effect and also the angling and tilting. Thus one has to use his left hand always to hold the scope.

Review of Literature and comparison of our study with other studies

Graft take rates with trans canal approach

Author	Take Rate
Sheehy and glasscock [1]	97.5%
Glasscock [2]	91%
Packer, <i>et al.</i> [3]	88%
Kacker [4]	50%
Gibb and Chang [5]	86.7%
Singh, <i>et al.</i> [6]	93.3%
Indorewala [7]	96.5%
Our study	92%

Table 1: Graft taken up rate in our study vs other studies.

Authors	Technique	Graft Take
Tarabichi [8]	Overlay	100%
	Underlay	94%
El Guindy [9]		91.7%
Anup raj [10]		90%
Our study	Overlay	88%
	Underlay	96%

Table 2: Graft take rates of various authors using endoscopic trans canal approach.

As seen in table 2. we find that the graft take rate of various authors [8-10] using an endoscopic permeal approach have been 100% and 94% [8], 91.7% [9], 90% [10]. Our graft take rate of 88% in overlay technique and 96% in underlay technique was comparable to others using endoscopic permeal approach.

Advantages with underlay

We have found the following advantages with the Underlay technique

1. Getting an Underlay plane (between the fibrous layer and mucosa) is easier and faster than getting an overlay plane (between the epithelium and fibrous layer).
2. Elevation and separation are easier and faster than in the overlay plane.
3. No fear of residual epithelium.
4. No fear about clearance of epithelium from ingrowing edge of perforation.
5. Good exposure of middle ear for ossicular inspection.
6. Gelfoam in the middle ear supports graft during placement, prevents the anterior slipping of the graft and adhesions
7. Good overlap is achieved on both sides of the graft viz. on the undersurface it is provided by the mucosa and on the outer surface by the skin with the fibrous layer providing vascularity.
8. Good bony support if the graft is spread 1-2 mm onto the bony canal wall all around (6, 7 and 8 prevents the medialization of the graft.)
9. No fear of reduction of middle ear space.
10. Hugging the handle of malleus prevents lateralization of the graft.
11. No risk of anterior slipping of the graft owing to the overall good support.
12. Epithelium with the fibrous layer is more sturdy and easier to reposition than epithelium alone.
13. Healing is faster
14. This technique is suitable for all type of perforations except tympanosclerosis.

Conclusion

The main study of endoscopic ear tympanoplasty is that of the re- discovering of the ear canal as the most logical, direct, and natural access point to tympanic membrane and middle ear cleft. Endoscopic ear surgery preserves much of normal anatomy as possible by minimizing unnecessary dissection of bone and soft tissue. Wide angle, and magnified view provided by endoscope and ability to easily negotiate through EAC and provide uninterrupted image overcomes most of the disadvantage of microscope. In terms of morbidity and postoperative recovery endoscope produced promising results. Thus, Endoscopic tympanoplasty can be a good alternative of microscopic tympanoplasty.

Bibliography

1. Sheehy JL and Glasscock ME. "Tympanic membrane grafting with temporalis fascia". *Archives of Otolaryngology* 86 (1967): 391.
2. Glasscock ME III. "Tympanic membrane grafting with fascia: overlay vs. undersurface technique". *Laryngoscope* 83 (1973): 754-770.
3. Packer P, *et al.* "What's best in myringoplasty: underlay or overlay, dura or fascia?" *The Journal of Laryngology and Otology* 96 (1982): 24-41.
4. Mawson SR and Lord I. "Tympanoplasty in Britain". *Annals of Otolaryngology* 81 (1972): 686-689.
5. Gibb AG and Chang S-K. "Myringoplasty (a review of 365 operations)". *The Journal of Laryngology and Otology* 96 (1982): 915-930.
6. Singh M., *et al.* "Comparative study of the underlay and overlay techniques of myringoplasty in large and subtotal perforations of the tympanic membrane". *The Journal of Laryngology and Otology* 117 (2003): 444-448.
7. Indorewala ST. "Dimensional stability of the free fascia grafts: clinical application". *Laryngoscope* 115 (2005): 278-282.
8. Tarabichi M. "Endoscopic middle ear surgery". *Annals of Otolaryngology, Rhinology and Laryngology* 108 (1999): 39-46.
9. El-Guindy A. "Endoscopic transcanal myringoplasty". *The Journal of Laryngology and Otology* 106 (1993): 493-495.
10. Raj A and Meher R. "Endoscopic transcanal myringoplasty: a study". *Indian Journal of Otolaryngology* 53.1 (2001): 47-49.

Volume 1 Issue 1 September 2019

© All rights are reserved by Vaidik M Chauhan and Rajesh Vishwakarma.