

Visual Snow: One Case and Schizophrenia, Grave's Disease, Vitamin B₁₂**Paul T E Cusack***

23 Park Ave, Saint John, NB E2J 1R2, Canada

***Corresponding Author:** Paul T E Cusack, 23 Park Ave, Saint John, NB E2J 1R2, Canada.**Received:** March 18, 2024**Published:** April 01, 2024© All rights are reserved by **Paul T E Cusack**.**Abstract**

This paper is a desktop case study of one patient who has among other deficiencies a case of visual snow. He also is allergic to the sun and has had schizophrenia. We also consider what may be a cause of schizophrenia viz Vitamin B12 deficiency. Schizophrenia could also be caused by having a mother who has Grave's Disease (overactive thyroid).

Keywords: Visual Snow; Floaters; Occipital Lobe; Vitamin B12; Vitamin B9 (Folate); Schizophrenia; Grave's Disease


Introduction

In this paper, we consider one patient who has visual snow as well as a host of other health problems, most notably schizophrenia.

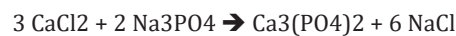
A 56-year-old male patient has visual snow in his vision. His snow is in the shape of a crescent like the letter "C" and occurs more frequently lately. He also has floaters, and 10% cataracts. He is near sighted and has scar tissue in the center of both eyes. He is light sensitive and has an allergy to sunlight. He has after vision as well. The patient does not have migraines, nor bruxism, but he does have anxiety (panic attacks) for which he is medicated with clonazepam. The patient also drinks 3-4 cups of coffee per day with copious sugar added. He doesn't consume alcohol. He uses a computer screen. The patient also takes anti psychotic medication for schizophrenia (20 mg per day Olanzapine). In the last 2 years, he was diagnosed with Barrett's Esophagus. The patient has anemia.

Lately, he noticed his eyesight failing while using his computer. Within the last 6 months, he has had rotary vertigo, and binocular vision. He also has had a couple of instances where he couldn't focus his eyes. It was temporary. The last time he had that occur was when he was taking SSRI Prozac to treat depression.

He doesn't presently have diabetes, but his medications are known to cause it. He has low blood pressure and feels fatigue often. He has irregular sleeping habits.



Stomach Acid → Gastromina Zollinger-Ellison Syndrome



Calcium salt + Phosphorus → Bacteria metabolism

Calcium moderates nerve impulse. Gastromina results from acetic acid. Acetic acid (Vinegar) contributes to acne.

Gastrin is secreted by the G cells. G cells are primarily found in the pyloric antrum but can also be found in the duodenum and the pancreas [1,2]. The primary function of gastrin is to induce the release of hydrochloric acid (HCl) from the parietal cells located in the fundus of the stomach. Parietal cells are responsible for hydrochloric (HCl) secretion along with intrinsic factor that binds to vitamin B₁₂ and helps with its uptake in the terminal ileum. Other functions of gastrin include stimulating the growth of gastric mucosa and gastric motility and promoting gastric emptying. These mechanisms of the gastrointestinal tract (GIT) are up-regulated by the vagus nerve of the parasympathetic nervous system (PNS), which carries out the majority of its functions by the release of neurotransmitter Acetylcholine (Ach), and to a lesser extent gastrin releasing peptide (GRP) protein. On the contrary, the functions of GIT are down-regulated by the activation sympathetic nervous system (SNS), which carries out its functions mostly via neurotransmitter epinephrine. Source Wikipedia.

Epinephrine is the cause of panic attacks. Acetylcholine is produced from tryptophan -testosterone -and serotonin. The epinephrine controls Sympathetic Nervous System. The Parasympathetic nervous system including the focus of the eyes.

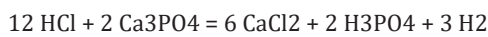Vitamin B₁₂, also known as cobalamin, is a water-soluble vitamin involved in metabolism [2]. It is one of eight B vitamins. It is required by animals, which use it as a cofactor in DNA synthesis, and in both fatty acid and amino acid metabolism [3]. It is important in the normal functioning of the nervous system via its role in the synthesis of myelin, and in the circulatory system in the maturation of red blood cells in the bone marrow [2,4]. Source: Wikipedia.

The patient also has dark circles around the eyes, and a pail complexion and a look of being tired. He passes out when he gives blood from fasting. He has chronic fatigue, hair loss on the knees, tinnitus, and constipation, guilt and psychosis. He has malabsorption of vitamin B₁₂. He may have parasites in the gut.

Calculations

Recommend Daily Amount of B₁₂ 200-250 pg/mL ~2.25=4/9=0.444
 0.444^2-0.444-1=-1.247~-1.25=Emin

Propionic Acid causes Propionibacterium leading to acne.



$$\text{pH} = \text{Log} [\text{H}^+]$$

$$1 \frac{1}{2} \text{ moles of H}_2 = 3 \text{ mol}[\text{H}^+]$$

$$\text{pH} = \text{Ln} [3/60 \text{ m}\ell]$$

$$= 2.9957 = c$$

Avg pH=1.5-3.5 in 20 -100mℓ of fluid

$$= 0.04/60 = 6.66$$

$$\text{pH} = 6.66 = \text{Ln} [\text{H}^+]$$

$$[\text{H}^+] = e^{6.66} = \pi/4 = t$$

$$\sin t = \cos t$$

$$y = y'$$

$$6(110.98) + 2(98.00) + 3(2.02) = 867.94 \sim 0.866 = \sin 60^\circ = t$$

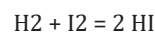
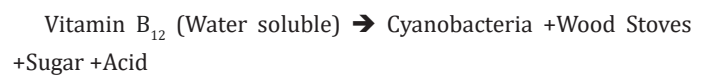
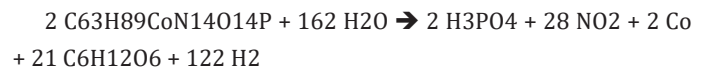
$$\sin 60 \times \pi/4 = 0.66088$$

$$3(110.98) + 2(63.94) = 0.66082$$

Vitamin B₁₂ deficiency has been detected among COVID survivors.

I suspect that there is a connection between deficiency in vitamin B₁₂ and B6 (Folate) and schizophrenia. Folate is necessary to produce red blood cells from iron. B₁₂ is necessary for pregnant women to have a baby with a healthy nervous system. We suspect

that iron is a cause of schizophrenia, specifically FeCl₂. We discussed in a previous paper that schizophrenia in Britain coincided with the areas where a lot of iron or calcium was in the ground. We've also seen that schizophrenia coincided with places that had cholera outbreaks such as Saint John, NB. There they have double the rate of schizophrenia and had a cholera outbreak in 1854. Vitamin B₁₂ is essential for producing healthy sDNA. Clinical studies should be done to determine what affect Vitamin B₁₂ and B9 had on the development of DNA. This author suspects that it affects adenine. The patient's mother had Thyroid Disease (Grave's disease or Hyperthyroidism) Thyroid Disease leads to vitamin B₁₂ deficiency.



These two reactions explain why patients with an overactive thyroid have the same symptoms as those with Vitamin B deficiency, including dementia. The mother has Dementia.

$$122 \text{ mol of H}_2$$

$$244 \times 6.023 = 1469.6 \text{ gm}$$

$$1469.6/5\ell \text{ of blood} = 293.9$$

$$\text{Now } 293.9/125 \text{ m}\ell \text{ CSF} = 2.3512$$

$$2.3512 \times 1.0074 = 2.368$$

$$2.368 / 7 = 0.376 = 1/F = E$$

After 27 days of taking Calcium, Zinc, Magnesium, Vit B₁₂, Artichoke, Turmeric, Milk Thistle, Chromium, Vanadium, Folate Vit B9, Omega 3, and one day: A E, C, D. I have stopped taking these supplements. I think the Omega 3 (Cod Liver Oil) brings pout Brain Fog as a result of COVID infection. I detoxed my liver with Milk Thistle. I lost some weight from the increased metabolism (B₁₂, B9, Mg, Fe) and Artichoke. I must no longer be anemic since I have stubble of hair growing back on my knees. I lost the hair with Anemia. I think Chromium interferes with psychiatric medication.. It is good for eye strain which I have. So I'm all done with the supplements.

A McGill educated General Physician comments that we don't know how much of what is wrong with us is from what we eat. The human body is like a chemical experiment that needs nutrition and a balanced diet. As for taking vitamins, they seem to have only a limited impact on changing the health of the patient. The vitamins did seem to help with the anemia problem. Hir has begun to regrow on the once hairy legs of the patient. Ther Vitamin B₁₂ taken to boost the metabolism along with Magnesium Folate seemed of

limited value. The patient seems to have less dense fat and a little impact on waisted line measurements. Vitamin B₁₂ of course has cobalt which has been shown to cause schizophrenia. The patient did notice psychosis like symptoms while taking both Vitamin B₁₂ as well and Chromium which is thought to interfere with psychiatric medication. The Omega 3 caused pressure in the brain especially around the ears. The patient stopped taking Omega 3 before the bottle was 1/2 finished. He also stopped the One -A -Duty which has vitamin A, C, D, E, B's, Omega 3 because of the omega 3. Omega 3 brought out the chronic lung infection that lingered without the patient. The concentrated artichoke for weight loss didn't seem to work.

Conclusion

Visual Snow is the tip of the iceberg for nervous system disease. It may indicate schizophrenia, a much more serious disease. Overall, the patient eats a balanced diet. He could have diabetes eventually, as well as current anemia, obesity, eye strain, slow metabolism, toxic liver, brain fog, double vision, rotary vertigo. Everyone who wants to be healthy should have access to sampling of the blood, urine, feces and hair and nails and CSF to determine what chemicals they have too much of and what they are short on. This may save a lot of more serious health problems in the future as well as a healthier today.

Bibliography

1. Visual Snow Syndrome (Static Vision): Symptoms and Causes (clevelandclinic.org).
2. Zollinger-Ellison syndrome - Symptoms and causes - Mayo Clinic.
3. Zollinger-Ellison Syndrome | Johns Hopkins Medicine.
4. Vitamin B12 Deficiency: Causes, Symptoms, and Treatment (webmd.com).