



## The Role of Ocular Findings in Prognosticating Mortality in Head Injury Patients: A Prospective Study

Busaraben Gandhi<sup>1</sup>, Stuti Juneja<sup>2</sup>, Manoj Soman<sup>3,4\*</sup> and Unnikrishnan Nair<sup>3,4</sup>

<sup>1</sup>MS Ophthalmology, Medical Retina Research Fellow, London Northwest University Hospital and Research Institute, London, United Kingdom

<sup>2</sup>MS Ophthalmology, Associate Professor and In-Charge, Head of the Department of Ophthalmology, Medical College Vadodara, Vadodara, Gujarat, India

<sup>3</sup>MS Ophthalmology, Vitreoretinal Services, Chaithanya Eye Hospital and Research Institute, Trivandrum, Kerala, India

<sup>4</sup>MS Ophthalmology, Chaithanya Innovation in Technology and Eyecare (Research), Trivandrum, Kerala, India

\*Corresponding Author: Manoj Soman; MS Ophthalmology, Vitreoretinal Services, Chaithanya Eye Hospital and Research Institute, Trivandrum, Kerala, India.

DOI: 10.31080/ASNE.2025.08.0812

Received: February 12, 2025

Published: February 28, 2025

© All rights are reserved by **Manoj Soman, et al.**

### Abstract

**Objective:** To evaluate the frequency and severity of different ocular manifestations in head injury and assess the role of optic nerve sheath diameter (ONSD) in predicting mortality, with the goal of reducing overall mortality through early recognition and appropriate interventions.

**Design:** Prospective study.

**Methodology:** A study of 180 head injury cases was conducted at a tertiary care hospital over one year to evaluate various ocular manifestations. The Glasgow Coma Scale (GCS) was used to assess head injury severity. Patients were examined for ocular findings, age, sex, mode of injury, and symptoms. Bed side ocular examination, visual acuity, and fundus examination via indirect ophthalmoscopy were performed. ONSD measurements in primary gaze and in supine position using USG B-scan were obtained. Statistical analysis was done using the chi-square test and descriptive statistics. Ocular neurological signs, ONSD values, and GCS scores were correlated with survival outcomes.

**Outcome Measures:** In this study of 180 head injury patients, 91.11% had ocular complications, with lid edema (85.56%) and ecchymosis (76.11%) being the most common. Most patients were male (88.33%) and between 21-30 years old. Road traffic accidents (81.11%) were the leading cause of injury. Cranial nerve palsies, notably third nerve palsy (2.22%), and pupillary abnormalities (29.44%) were observed. Posterior segment involvement, including papilledema and retinal haemorrhage, was observed in 6.67% of cases. Abnormal pupil reactions, Glasgow Coma Scale (GCS) scores, and optic nerve sheath diameter (ONSD)  $\geq 5$ mm significantly ( $P < 0.0001$  for each of above) and orbital fractures ( $P = 0.04$ ) correlated with mortality.

**Conclusions:** Ocular manifestations were present in 91.11% of head injury cases. Pupillary abnormalities and ONSD  $\geq 5$  mm were highly associated with mortality. Increased ONSD could serve as a surrogate bedside measure of prognosis and survival in head injury patients.

**Keywords:** Glasgow Coma Scale; Head Injury; Ocular Manifestations; Optic Nerve Sheath Diameter; Mortality Prediction

## Abbreviations

CLW: Contused Lacerated Wound; CPP: Cerebral Perfusion Pressure; CSF: Cerebro Spinal Fluid; CT: Computed Tomography; GCS: Glasgow Coma Scale; ICP: Intra Cranial Pressure; IH: Intracranial Hypertension; MRI: Magnetic Resonance Imaging; ONSD: Optic Nerve Sheath Diameter; RAPD: Relative Afferent Pupillary Defect; RTA: Road Traffic Accident; RTS: Revised Trauma Score; TBI: Traumatic Brain Injury; USG: Ultra Sonography

## Introduction

Traumatic brain injury (TBI) is a significant global health concern, with an estimated incidence of 939 cases per 100,000 people annually, affecting millions worldwide [1]. India bears a particularly heavy burden, with over one million serious head injuries reported annually [2]. Ocular complications in TBI are common, occurring in 25% to 83% of cases, and can be vision-threatening in severe instances [3-6]. The prompt recognition of ocular manifestations is vital, not only for preserving vision but also for assessing neurological damage. Studies show that a higher incidence of ocular findings is observed when ophthalmologists are actively involved in trauma care, highlighting the importance of comprehensive ophthalmic assessments in TBI management [4].

Severe TBI is often associated with elevated morbidity and mortality rates, with nearly 40% of survivors experiencing long-term disabilities. Moreover, fewer than half of the affected individuals achieve favourable neurological outcomes after one year [7,8]. Several prognostic factors, including age, gender, injury severity, Glasgow Coma Scale (GCS) score, motor response, pupillary reactivity, type of brain lesion, and elevated intracranial pressure (ICP), influence the outcome in TBI patients [9,10].

One of the most critical prognostic indicators in severe TBI is elevated ICP, which is closely linked to poor outcomes, including death. Cerebral oedema, a common cause of intracranial hypertension (IH), affects more than 60% of patients with intracranial haemorrhage and can even develop in 15% of patients with initially normal CT scans. Left untreated, increased ICP can lead to a reduction in cerebral perfusion pressure (CPP), resulting in cerebral ischemia, brain herniation, and, ultimately, death [11]. Early recognition and intervention for elevated ICP significantly improve the prognosis in TBI patients.

While invasive ICP monitoring techniques, such as intraventricular catheter placement or craniotomy, are considered the gold standard, they carry substantial risks, including infection and haemorrhage [12]. This has driven the search for reliable, non-invasive alternatives that can provide early indicators of elevated ICP without these complications.

Optic nerve sheath diameter (ONSD) measurement, using ocular sonography or CT imaging, has emerged as a promising, non-invasive method for monitoring ICP. The optic nerve sheath, connected to the subarachnoid space, dilates in response to elevated ICP, allowing for indirect measurement of ICP through ONSD, [13]. Studies have demonstrated a strong correlation between increased ONSD and elevated ICP, making it a valuable tool for real-time, non-invasive monitoring [13]. Given its practicality, ONSD measurement could serve as an essential bedside tool in emergency settings.

This study aims to investigate various ocular features including ONSD that can serve as a predictor of hospital mortality in head injury patients.

## Materials and Methods

This study comprises 180 cases of head injury treated at the emergency department of a tertiary hospital over 1 year. After receiving approval from the ethics committee and obtaining written consent from patients, including consent for photographs, those with ocular morbidity were evaluated based on age, sex, mode of injury, Glasgow Coma Score (GCS), and associated injuries. Clinical details, including name, age, sex, and address, were documented. The exact mode of injury, type of object involved, and the duration of injury were also recorded.

Ocular examinations included bedside visual acuity assessments, along with a thorough systemic examination to evaluate the severity of head injuries according to the GCS scale, as outlined in the *Advanced Trauma Life Support: Course for Physicians* (American College of Surgeons, 1993). Pupillary signs were given special importance in determining the level of consciousness and life prognosis. Imaging studies included ultrasonography (USG) of the eye with B-scan to assess optic nerve thickness. In this procedure, a linear probe (7-12 MHz) was applied to the closed upper eyelid of supine patients in primary gaze, using adequate aqueous gel as a coupling agent. In cases where extreme gaze deviations occurred, the lateral axial view was utilized if other views failed.

Since the most distensible part of the optic nerve sheath is located approximately 3mm behind the vitreo-retinal interface, optic nerve sheath diameter (ONSD) was measured at this level, perpendicular to the axis of the nerve, using a Philips Affinity series machine. [14] The average of bilateral ONSD measurements was calculated for each patient to assess raised intracranial pressure.

Follow-ups were conducted at the first, second, and third weeks, where any improvement or deterioration in the general condition and ocular findings were noted based on visual acuity, pupillary reactions, and ocular movements. The data, including cause, effect, and outcome, were statistically analyzed for significance using the Chi-Square Test, Frequency, and Percentage methods.

## Results and Discussion

### Results

This study analyzed 180 head injury patients, of which 159 (88.33%) were males and 21 (11.67%) were females, with a male-to-female ratio of 7.57:1. The most common cause of injury was road traffic accidents (81.11%), followed by assaults (7.78%), falls from heights (5%), and other causes such as falls in bathrooms (6.11%). Statistical analysis revealed that the correlation between male gender and road traffic accidents as the cause of head injury was not significant ( $\chi^2 = 1.88, P = 0.16$ ), (Table 3).

The severity of head injuries varied, with 76.11% classified as mild (GCS 13-15), 2.78% as moderate (GCS 9-12), and 21.11% as severe (GCS  $\leq 8$ ). Ocular and visual complications were present in 91.11% of cases. The most frequent ocular findings were lid edema (85.56%) and ecchymosis (76.11%), (Table 1). Cranial nerve palsies occurred in 6 patients (3.34%), with third nerve involvement being the most common, found in 4 cases (2.22%), (Table 1) (Figure 3). Pupillary abnormalities were observed in 53 cases (29.43%), with relative afferent pupillary defect (RAPD) present in 17 patients (9.44%), (Table 1). Bilateral dilated fixed pupils were seen in 4.44% of cases, (Table 1).

Posterior segment manifestations were found in 12 cases (6.67%), with papilloedema being the most common (3.33%), (Table 1), all of which had optic nerve sheath diameters (ONSD) of  $\geq 5$ mm. Retinal haemorrhage was present in 4 cases (2.22%), and vitreous haemorrhage and macular edema were rare, found in 1 case each (0.56%), (Table 1). Optic nerve thickness measurements via USG B-scan revealed that 31 patients had an ONSD  $\geq 5$ mm (17.2%) while 82.2% had ONSD  $< 5$ mm.

Orbital wall fractures were observed in 40.56% of patients, with multiple fractures (26.67%) occurring nearly twice as often as isolated fractures (13.89%). Lateral orbital wall fractures were the most frequent (23.33%), followed by superior (16.67%), medial (11.67%), and inferior orbital wall fractures (10.00%), (Table 1).

In severe head injuries (GCS  $\leq 8$ ) 89.47% were associated with ocular manifestations. All 11 patients with a GCS  $\leq 3$  exhibited ocular manifestations as well. Among patients with moderate head injuries (GCS 9-12), 80% exhibited ocular manifestations. In patients with mild head injuries (GCS 13-15) 91.97% had ocular manifestations but had a favourable prognosis. Additionally, the relationship between GCS score and pupil abnormality was highly significant ( $\chi^2 = 25.22, P < 0.00001$ ), (Table 3).

### Correlation with mortality

Severe head injuries (GCS  $\leq 8$ ) were significantly associated with increased mortality. All 11 patients with a GCS  $\leq 3$  had a 100% mortality rate, indicating a poor prognosis. Among patients with moderate head injuries (GCS 9-12), 20% succumbed. In contrast, patients with mild head injuries (GCS 13-15) had a favourable prognosis, with no deaths reported.

Pupillary abnormalities were observed in 29.43% cases, with relative afferent pupillary defect (RAPD) present in 9.44% cases, 17.65% of whom died. Bilateral dilated fixed pupils were seen in 4.44% of cases and all these cases were associated with poor prognosis. The relationship between pupil abnormalities and mortality was also highly significant ( $\chi^2 = 21.26, P < 0.0001$ ), as was the correlation between ONSD  $\geq 5$ mm and mortality ( $\chi^2 = 41.67, P < 0.0001$ ), (Table 3). There was a significant correlation between orbital wall fractures and mortality ( $\chi^2 = 3.85, P = 0.04$ ), (Table 3).

Ocular Manifestations	No. of Cases (Percentage)	
Lid Edema	154	85.56
Ecchymosis	137	76.11
Ptosis	4	2.22
Lagophthalmos	1	0.56
CLW from Eyebrow to Lower Lid	27	15.00
Subconjunctival Haemorrhage	122	67.78
Chemosis	112	62.22
Corneal Epithelial Defect	26	14.44

Corneal Perforation	1	0.56
HypHEMA	2	1.11
Cranial Nerve Palsies	6	3.34
3 <sup>rd</sup> cranial nerve palsy	4	2.22
6 <sup>th</sup> cranial nerve palsy	1	0.56
7 <sup>th</sup> cranial nerve palsy	1	0.56
Pupillary Involvement	53	29.44
Relative Afferent Pupillary Defect	17	9.44
Bilateral Sluggish Reaction to Light	15	8.33
Unilateral Dilated Fixed	13	7.22
Bilateral Dilated fixed	8	4.44
Posterior Segment Involvement	12	6.67
Papilloedema	6	3.33
Retinal Haemorrhage	4	2.22
Vitreous Haemorrhage	1	0.56
Macular Edema	1	0.56
Orbital Wall Fractures (isolated and multiple)	73	40.56
Lateral	42	23.33
Superior	30	16.67
Medial	21	11.67
Inferior	18	10.00

**Table 1:** Ocular manifestations.

GCS score group	Correlation of GCS Score and ONSD value		
	ONSD >/5mm	ONSD < 5mm	Total
GCS</8 (Severe)	16	22	38
GCS 9-12 (Moderate)	1	4	5
GCS 13-15 (Mild)	14	122	136
	31	148	179

**Table 2:** Correlation of GCS and OSND.

Correlation between Variables	Chi-square value ( $\chi^2$ )	P value	Significance
Correlation Between Male Sex and RTA as Cause of Injury.	1.88	0.16	Not significant
Correlation Between Orbital Wall Fractures and Mortality.	3.85	0.04	Significant
Correlation Between Pupil Reaction Abnormality and Mortality.	21.26	< 0.0001	Highly significant
Correlation Between USG B SCAN (ONSD) Value $\geq$ 5 and Mortality.	41.67	< 0.0001	Highly significant
Correlation Between GCS Score and Pupil Abnormality.	25.22	< 0.00001	Highly Significant
Correlation Between different Age group and USG B SCAN (ONSD) Value.	6.087	0.4135	Not significant
Correlation Between Gender and USG B SCAN (ONSD) Value.	1.20	0.273	Not significant
Correlation Between GCS Score </8 and USG B SCAN (ONSD) Value $>$ /5mm	20.92	<0.001	Highly Significant

**Table 3:** Correlation between select variables and mortality.

**Discussion**

In our study on ocular manifestations of head injury, the majority of patients were between the ages of 21-30 (31.11%) and 31-40 (25.00%), aligning with findings by Sahasrabudhe., *et al.* and Kumari., *et al.* [15,16]. The most vulnerable group for head injuries was young adults, peaking in the second and third decade of life, likely due to increased exposure to risky environments such as outdoor work, travel, and assault. Elderly patients (>60 years) and young children (<10 years) accounted for significantly fewer cases, which also corresponded with these studies, [15,16].

A higher prevalence of male patients (88.33%) was noted, consistent with studies by Sahasrabudhe, *et al.* Kumari, *et al.*, and Abbasi, *et al.* [15-17]. likely due to greater exposure to environments with high injury risks, such as unsafe work sites and vehicular accidents. Vehicular accidents were the most common cause of head injury (81.11%), higher than in Sahasrabudhe, Kumari, and Abbasi's studies, [15-17] indicating the rising use of vehicles without proper safety measures. Assault-related injuries were lower in our study (7.78%), contrasting with higher rates found in their research, [15-17].

Ocular involvement was seen in 91.11% of cases, reaffirming its frequent association with head injuries, consistent with Sahasrabudhe's findings (78%), [15]. Overall, our study highlights the significant link between head trauma and ocular manifestations, especially in young adults involved in vehicular accidents.

In our study on ocular manifestations of head injury, 91.11% of cases exhibited ocular involvement, which was higher compared to the findings of R. Kumari, *et al.* (67.44%), Kulkarni, *et al.* (83.50%), and F. Masila, *et al.* (68.70%), [5,16,18]. Lid edema was the most common manifestation in our study (85.56%), similar to Kulkarni's findings, while other studies, such as K. Abbasi's, reported ecchymosis as more prevalent, [5,17]. Neurological ptosis was seen in 2.22% of cases, consistent with other studies, although Kumari, *et al.* reported a higher incidence (8.13%), [16]. Lagophthalmos was rare in our study, with only 1 case (0.56%), and was not reported in most other studies, (Table 1).

Sub-conjunctival haemorrhage (67.78%) was a frequent finding in our study, (Table 1) ranking third, while it was the second most common in Abbasi's study (40.79%), [17]. Chemosis was seen in 62.22% of cases, (Table 1) significantly higher than in K. Abbasi (10.53%) and F. Masila (7.22%), [17,18]. Corneal epithelial defects were found in 14.44% of cases, (Table 1) and 0.56% of cases had corneal perforation, with globe perforation, a lower rate compared to other studies like Kumari's, [16].


HypHEMA occurred in 1.11% of cases, while cranial nerve palsies were noted in 3.34% of cases, (Table 1). Pupillary involvement was found in 29.44%, and posterior segment manifestations were observed in 6.67% of cases, (Table 1), which was lower than other studies, notably Kumari, *et al.* and Masila, *et al.* [16,18]. Orbital

wall fractures were observed in 40.56% of cases, (Table 1), the highest incidence compared to other studies, suggesting the severity of trauma in our cohort.

In our study, third nerve palsy was seen in 2.22% of cases, (Table 1) (Figure 2-4) with 1.67% showing ptosis initially, and one case developing ptosis during follow-up. Mild improvement occurred with steroid treatment. Other studies reported similar findings, including Kumari, *et al.* (3.49%) and Abbasi, *et al.* (6.58%), [16,17].

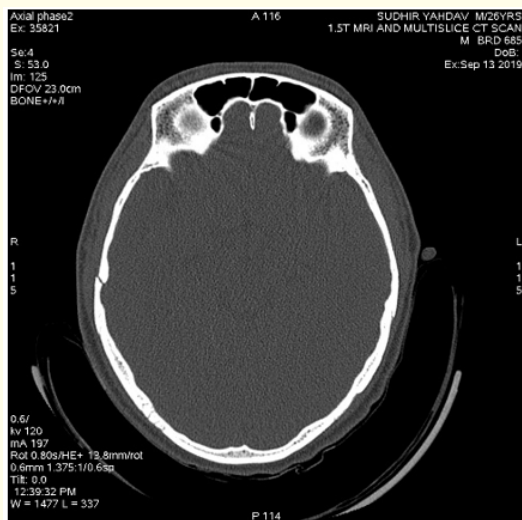
Sixth nerve palsy was present in 0.56% of cases, consistent with reports from Kumari, *et al.* (5.81%) and Abbasi, *et al.* (7.89%), [16,17], where it was the most commonly affected cranial nerve. One case of seventh nerve palsy was also noted (0.56%), in line with other studies, (Table 1) (Figure 1).

In our study, 29.44% of patients had pupillary abnormalities, compared to 19.00% in the study by Sahasrabudhe, *et al.* [15] Relative afferent pupillary defects (RAPD) were found in 9.44% of cases, significantly higher than the 2.50% reported by Sahasrabudhe, *et al.* [15] likely due to more optic nerve injuries in our cohort. Additionally, 8.33% of patients exhibited bilateral sluggish light reactions, compared to 1.00% in Sahasrabudhe, *et al.* [15] Unilateral dilated fixed pupils were observed in 7.22% of patients, (Figure 6,7) with 33.33% having third nerve palsy, while 4.44% had bilateral dilated fixed pupils, all of whom had a poor prognosis.

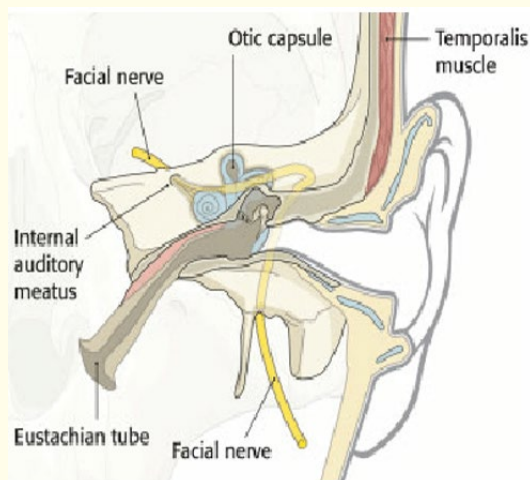


**Figure 1:** Right Eye: Lagophthalmos on closure of eyes in patients with 7<sup>th</sup> nerve palsy.

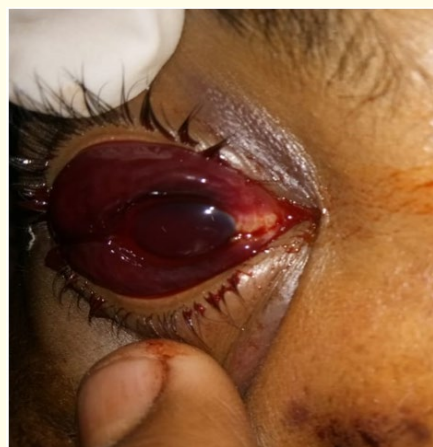



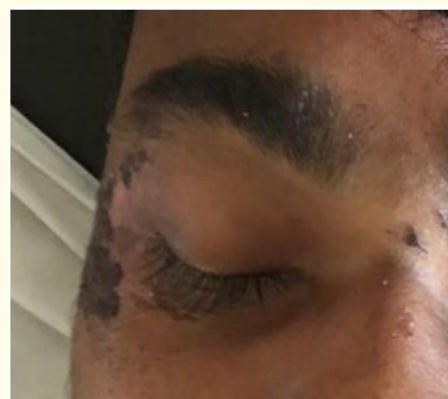**Figure 1a:** CT and MRI head of the same patient showing fracture of squamous part of right temporal bone extending to the petrous part of the right temporal bone.



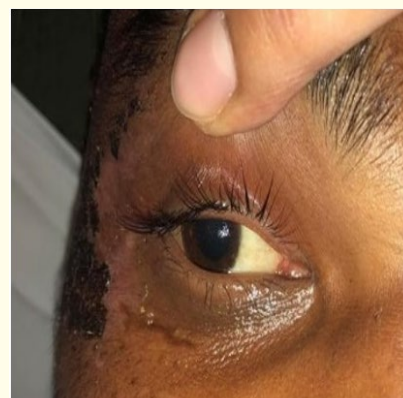
**Figure 1b:** Mechanism of 7<sup>th</sup> nerve palsy resulting from fracture of petrous part of the temporal bone causing injury to tympanic part of the 7<sup>th</sup> nerve.



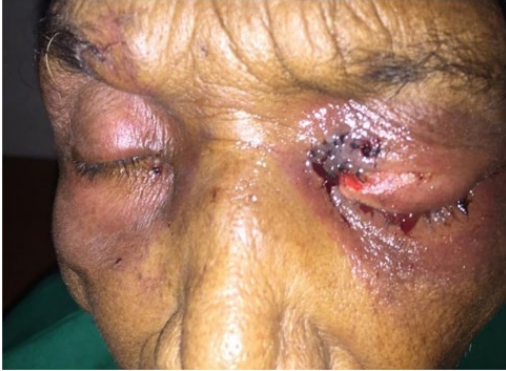**Figure 2:** Right Eye: Full chamber hyphema following head injury due to RTA.



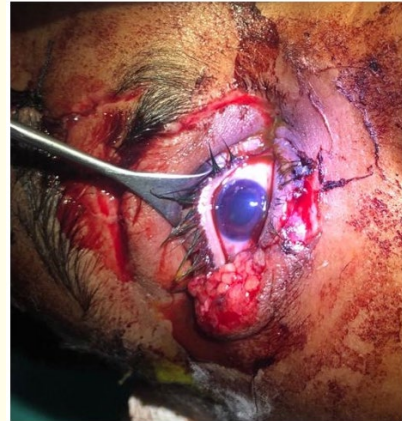**Figure 3:** Right third nerve palsy with ptosis due to right temporal lobe contusion with pneumocephalus.



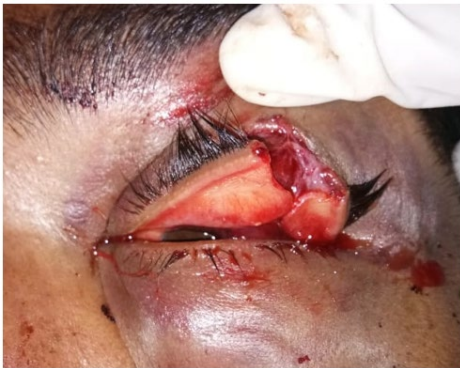**Figure 3a:** Same patient with right lid elevated showing exodeviation with traumatic mydriasis of right eye due to third nerve palsy.



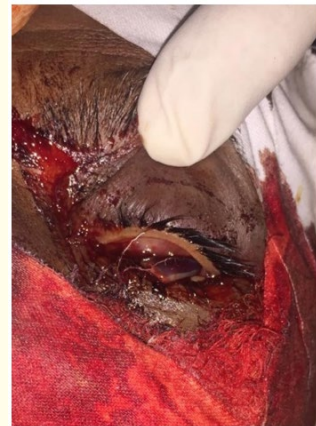**Figure 4:** Bilateral black eyes seen secondary to basal skull fracture.



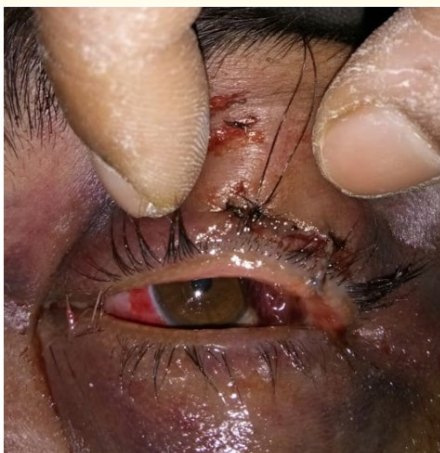**Figure 6:** Showing right eye traumatic mydriasis with right lower lid tear on lateral aspect.



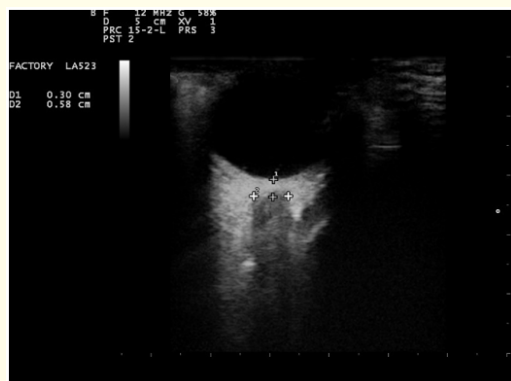**Figure 5:** Showing left eye upper lid full thickness tear on the lateral aspect secondary to head injury due to RTA.



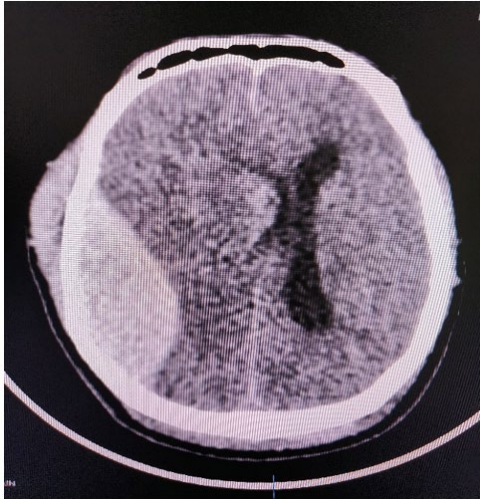
**Figure 7:** Showing left eye globe rupture with autovisceration of orbital tissue following injury due to RTA.



**Figure 5a:** Same patient left eye upper lid full thickness tear repaired with 6-0 vicryl suture under LA with traction suture.



**Figure 8:** USG B scan of this patient showing optic nerve sheath diameter 5.8mm.



**Figure 8(a):** CT scan of the same patient showing a large lenticular-shaped hyperdensity in the right parietal region in the extradural location, causing a significant midline shift towards the left side, suggesting an extradural haemorrhage. A hypodensity is noted in the right parietal lobe adjacent to the above-mentioned hyperdensity, suggestive of brain edema.

In our study, the overall incidence of posterior segment manifestations was low. Papilloedema was observed in 3.33% of cases, which was lower than the 5.50% reported by Kulkarni, *et al.* [5] possibly due to their focus on closed head injuries. Retinal haemorrhage was seen in 2.22% of cases, higher than the 0.50% in Kulkarni's study, [5]. Macular edema and vitreous haemorrhage were rare, both occurring in 0.56% of cases, with similar findings for vitreous haemorrhage in the study by Kulkarni, *et al.* (0.50%), [5].

In our study, orbital fractures were observed in 40.56% of head injury cases, a higher incidence compared to Kumari, *et al.* (12.79%) and Sahasrabudhe, *et al.* (13.00%), [16,15], this may be due to the higher rate of RTAs (81.11%) in our study. Lateral orbital wall fractures were the most common (23.33%), consistent with Kumari, *et al.* (5.81%) and Sahasrabudhe, *et al.* (10.50%), likely due to the lateral impact during RTAs, [16,15]. Superior orbital wall fractures were the second most common (16.67%), followed by medial orbital wall fractures (11.67%). Inferior orbital wall fractures were the least common (10.00%), as seen in Sahasrabudhe, *et al.* (0.50%), [15].

The risk of increased ICP in the setting of traumatic brain injury is that it increases the mortality rate, [19]. Today, several techniques exist to diagnose ICP with each technique having its own challenges. The use of intracranial catheters may cause coagulopathy or thrombocytopenia, [20]. The use of computed tomography (CT) scan is an invasive technique and carries the risk of exposure to ionizing radiation, [21]. Also CT scan may not be easily available in every setting and there may be feasibility issues in these bed ridden patients [22]. Some studies in different parts of the world have observed that the changes in ONSD are strongly in consonance with CT scan image findings, which has vivid evidence of an increase in ICP. [23-26].

We found raised ONSD in 17.32% of patients, with a mean ONSD of 5.25 mm for measurements  $\geq 5.0$  mm and 3.83 mm for measurements  $< 5.0$  mm. ONSD  $\geq 5.0$  mm was considered a surrogate marker for early increased intracranial pressure. In contrast to our observation, Kaur, *et al.* reported raised ONSD in 46% of their cohort, with mean ONSD values of 5.6 mm and 4.1 mm, respectively, [27]. This difference could be attributed to variations in patient demographics, clinical conditions, or methodologies used between the studies.

Our study revealed a significant increase in ONSD with lower GCS scores (3-8), consistent with Kaur, *et al.* findings and a highly significant correlation (P-value = 0.000) (Table 2,3). This supports ONSD as an indicator of elevated ICP. However, the lower proportion of raised ONSD in our study may reflect differences in patient ICP levels or selection criteria. We could not assess the 30-degree test, a more reliable ONSD assessment tool, in most of the patients as the patient could not comprehend due to the neurological involvement or restricted movement of the eye.

Both our study and Kaur, *et al.* found no significant relationship between age or gender and ONSD measurements, (Table 3). This consistency suggests that ONSD is a reliable indicator of ICP irrespective of these demographic factors, making it broadly applicable across diverse patient groups.

Our study recorded a maximum ONSD of 5.80 mm, slightly lower than Kaur, *et al.* 5.9 mm, [27]. These discrepancies might arise from variations in imaging techniques, measurement protocols, or patient characteristics. Standardizing measurement practices could help reconcile these differences.



## Conclusion

This study highlights the high incidence of ocular manifestations in head injury patients, the importance of ONSD measurements in detecting raised intracranial pressure, and the significant correlations between ocular signs, GCS scores, and mortality. The significant correlation between ONSD and GCS in our study reinforces the utility of ONSD measurements for assessing ICP in neuro-trauma patients. Given its non-invasive nature, ONSD measurement is a valuable tool for rapid assessment. The variations in prevalence and maximum ONSD readings compared to existing literature highlight the need for further research to standardize methodologies and confirm findings across various clinical settings.

## Limitations

The limitations of the study include the fact that no comparison of the ultrasound evaluation of the optic nerve thickness with CT scan/MRI scan was done as they have the advantage of less operator bias. Also the measurement of the optic nerve on the ultrasound was calculated as the average of the two optic nerves and analysis of individual optic nerve thickness and its correlation with mortality was not done. In spite of these limitations, the strength of this study is the large study population and its prospective nature.

## Conflict of Interest

- No authors have any proprietary interest.
- The authors declare that they have no competing interests.
- None of the authors has any conflicts of interest to disclose.

## Bibliography

1. Dewan Michael C., *et al.* "Estimating the Global Incidence of Traumatic Brain Injury". *Journal of Neurosurgery* (2018): 1-18.
2. Nehra Anil and Shubham Bajpai. "Effectiveness of Cognitive Retraining After Brain Trauma: Case Studies". *Activitas Nervosa Superior* 54 (2012): 139-145.
3. Emery JM., *et al.* "Orbital Floor Fractures: Long-Term Follow-Up of Cases with and Without Surgical Repair". *Trans Ophthalmol Otolaryngol* 75 (1971): 801-812.
4. Malik Anmol., *et al.* "Ocular Manifestations of Head Injury: A Clinical Study". *Sudanese Journal of Ophthalmology* 8 (2016): 46-50.
5. Kulkarni AR., *et al.* "Ocular Manifestations of Head Injury: A Clinical Study". *Eye (London)* 19 (2005): 1257-1263.
6. Odebode TO., *et al.* "Ocular and Visual Complications of Head Injury". *Eye (London)* 19 (2005): 561-566.
7. Selassie AW., *et al.* "Incidence of Long-Term Disability Following Traumatic Brain Injury Hospitalization, United States, 2003". *Journal of Head Trauma Rehabilitation* 23 (2008): 123-131.
8. Myburgh JA., *et al.* "Epidemiology and 12-Month Outcomes from Traumatic Brain Injury in Australia and New Zealand". *Journal of Trauma* 64 (2008): 854-862.
9. Saini NS., *et al.* "Factors Predicting Outcome in Patients with Severe Head Injury: Multivariate Analysis". *Indian Journal of Neurotrauma* 9 (2012): 45-49.
10. Roozenbeek B., *et al.* "Prediction of Outcome After Moderate and Severe Traumatic Brain Injury: External Validation of the IMPACT and CRASH Prognostic Models". *Critical Care Medicine* 40 (2012): 1609-1617.v
11. Vella MA., *et al.* "Acute Management of Traumatic Brain Injury". *Surgery Clinics of North America* 97.4 (2017).
12. Strumwasser A., *et al.* "Raised Intracranial Pressure in Those Presenting with Headache". *BMJ* (2018).
13. Frumin E., *et al.* "Sonographic Optic Nerve Sheath Diameter as an Estimate of Intracranial Pressure in Adult Trauma". *Journal of Surgical Research* (2011).
14. Hansen HC and K Helmke. "The Subarachnoid Space Surrounding the Optic Nerves: An Ultrasound Study of the Optic Nerve Sheath". *Surgical and Radiologic Anatomy* 18.4 (1996): 323-328. Google Scholar.
15. Sahasrabudhe V and A Sonkamble. "Ocular Manifestations in Head Injury: A Clinical Study". *International Journal of Medical Research Professionals* 3.4 (2017): 79-83.
16. Kumari R., *et al.* "Ocular Manifestations in Head Injury Patients: A Prospective Study". *International Journal of Contemporary Medical Research* 4.8 (2017): 1648-1651.
17. Abbasi KZ., *et al.* "Ocular Manifestations Associated with Head Injury". *Pakistan Journal of Ophthalmology* 32.2 (2016): 78-81.
18. Masila F., *et al.* "Ocular Findings in Patients with Head Injury". *JOECSA* 18.2 (2015).

19. Frumin E., et al. "Prospective Analysis of Single Operator Sonographic Optic Nerve Sheath Diameter Measurement for Diagnosis of Elevated Intracranial Pressure". *West Journal of Emergency Medicine* 15 (2014): 217-220.
20. Lee LA., et al. "Perioperative Head Injury Management in the Multiply Injured Trauma Patient". *International Anesthesiology Clinics* 40 (2002): 31-52.
21. Bajoghli M., et al. "Children, CT Scan and Radiation". *International Journal of Preventive Medicine* 1 (2010): 220-222.
22. Sarkisian AE., et al. "Sonographic Screening of Mass Casualties for Abdominal and Renal Injuries Following the 1988 Armenian Earthquake". *Journal of Trauma* 31 (1994): 247-250.
23. Karakitsos D., et al. "Transorbital Sonographic Monitoring of Optic Nerve Diameter in Patients with Severe Brain Injury". *Transplant Proceedings* 38 (2006): 3700-3706.
24. Girisgin AS., et al. "The Role of Optic Nerve Ultrasonography in the Diagnosis of Elevated Intracranial Pressure". *Emergency Medicine Journal* 24 (2007): 251-254.
25. Goel RS., et al. "Utility of Optic Nerve Ultrasonography in Head Injury". *Injury* 39 (2008): 519-524.
26. Soldatos T., et al. "Optic Nerve Sonography: A New Window for the Non-Invasive Evaluation of Intracranial Pressure in Brain Injury". *Emergency Medicine Journal* 26 (2009): 630-634.
27. Kaur Amandeep., et al. "Bedside Ultrasonographic Assessment of Optic Nerve Sheath Diameter as a Means of Detecting Raised Intracranial Pressure in Neuro-Trauma Patients: A Cross-Sectional Study". *International Journal of Medical Research Professionals* 3 (2017).
28. Raju NS. "Ocular Manifestations in Head Injuries". *Indian Journal of Ophthalmology* 31.6 (1983): 789-792.
29. Patel P., et al. "Post-Traumatic Cranial Nerve Injury". *Indian Journal of Neurotrauma* 2.1 (2005): 27-32.
30. Van Stavern GP., et al. "Neuro-Ophthalmic Manifestations of Head Trauma". *Journal of Neuro-Ophthalmology* 21.2 (2001): 112-117.
31. Baker RS and AD Epstein. "Ocular Motor Abnormalities from Head Trauma". *Survey of Ophthalmology* 35.4 (1991): 245-267.