

## The Effect on Histo-morphology of Lungs in Fluconazole and Vitamin E Treated Sprague Dawley Albino Rats with Septic Shock

Nasir Mustafa\*, Hina Zahoor and Kanza Shamim

Department of Health Sciences, Istanbul Gelisim University, Turkey

\*Corresponding Author: Nasir Mustafa, Department of Health Sciences, Istanbul Gelisim University, Turkey.

Received: October 22, 2020

Published: November 18, 2020

© All rights are reserved by Nasir Mustafa, et al.

### Abstract

Fluconazole is a subclass of triazole antifungal agents, is available as oral tablets, powder or for oral suspension, and as a sterile solution for intravenous administration. Fluconazole is designated chemically as 2,4-difluoro- $\alpha,\alpha^1$ -bis benzyl alcohol in the form of white crystalline solid which is slightly soluble in water and saline. Fluconazole oral suspension contains 350 mg or 1400 mg contains sucrose, citric acid anhydrous, sodium benzoate, sodium citrate, colloidal, silicon dioxide, titanium dioxide, xanthan gum, and natural orange flavor. After reconstitution with 24 ml of distilled water or purified water each ml of reconstituted suspension contains 10 mg or 40 mg of fluconazole. Animals are divided into 4 groups. The rats of group A were taken as control group. In group B rats are kept nil per orally at 12 hours prior to induction of septic shock produce by *Candida albicans* s. Group C animals are administrated with fluconazole at doses of 3mg/kg, 10mg/kg and 30mg/kg after the septic shock produce by *Candida albicans* s. Since fluconazole at a higher dose had clearly shown to decrease tissue injury. We decided to keep fluconazole dose as constant and vitamin E would be administered in dose of 10mg/100gm of body weight in group D. Both the drugs are administrated after inducing septic shock. After the study, animals sacrificed and lungs obtained within 8 hours of septic shock. Lungs are taken out from sacrificed animals and then fixed with paraffin and then sectioned and stained by eosin and haemotoxylin. With the help of cardiac puncture blood samples were taken to estimate the infectious markers. Study of CBC and CRP was done. The levels were estimated and compared with control and correlated with histologic findings. The lung histology is determined by mucosal thickening and inflammatory cells. All these results were in favor of group D fluconazole along with vitamin E that shows significant results in all parameters. There was significant correlation between control and fluconazole along with vitamin E treated group because vitamin E reduces the histopathological changes in lungs parenchyma. It is concluded from the study that vitamin E when treated with combination of fluconazole it decreases the lung tissue injury and oxidative stress.

**Results:** The present study reveals that the distorting effects of *Candida albicans* s on lung mucosa and establish improved effects of fluconazole decrease the elevated levels of TLC, Lymphocytes, CRP, neutrophils and attenuate the lung injury.

**Conclusion:** From this study it is concluded that the fluconazole attenuated lung injury and the biochemical and histopathological changes were more improved by addition of vitamin E. Because it acts as potent antioxidant agent.

**Keywords:** Lungs Histology; Fluconazole; Vitamin E; Septic Shock

### Introduction

Septic shock is a serious medical condition that leads to an organ injury or damage in response to infection and cause abnor-

malities in cellular metabolism [1]. The primary infection is most commonly by bacteria, but also may be by fungi, viruses, or parasites. It may be located in any part of the body, but most commonly

in the lungs, brain, urinary tract, skin, or abdominal organs [2]. It can cause multiple organ dysfunction syndrome (formerly known as multiple organ failure) and death. The mortality rate from septic shock is approximately 25–50% [3]. Septic shock results in ischemia and organ dysfunction secondary to infection which releases Cytokines which causes vasodilation, increased capillary permeability, decreased systemic vascular resistance, and low blood pressure. Finally, in an attempt to offset decreased blood pressure, ventricular dilatation and myocardial dysfunction occur. The precipitating infections that may lead to septic shock including pneumonia, bacteremia, pyelonephritis, meningitis, pancreatitis, necrotizing fasciitis, MRSA, and mesenteric ischemia [4,5]. The key role in the pathophysiology of septic shock is the development of an immune and coagulation response to an infection. Both pro-inflammatory and anti-inflammatory responses play a role in septic shock [6]. Most cases of septic shock are caused by gram-positive bacteria [7], followed by endotoxin-producing gram-negative bacteria, although fungal infections are an increasingly prevalent cause of septic shock [8]. The respiratory system consists of organs which perform the process of respiration in an organism. During the process of respiration exchange of gases takes place between organism and environment. In human this function is performed by a pair of lungs. Oxygen is taken into the lung which is inspiration and carbon dioxide is release into air called expiration. Inspiration and expiration are collectively called ventilation [9]. Respiratory centres are present in pons and medulla oblongata of the brain stem which controls and coordinates the respiratory movements. Contraction of external intercostal muscles causes movements of ribs and sternum outward and upward while it becomes flat when diaphragm contracts. This method helps to create the negative intra-plural pressure inside the thoracic cavity. Exchange of gases occurs when air enters into alveoli through respiratory pathway. Relaxation of external intercostal muscles and the contraction of internal intercostal muscles, which move ribs as well as sternum inward and downward. Similarly, diaphragm also relaxes which makes it dome-shaped thus reducing the volume of the thoracic cavity. In this way lungs are compressed so the air along with water vapours is exhaled outside [10]. Pulmonary bronchi constrict due to low partial pressure of oxygen [11]. Lung epithelium secretes immunoglobulins (IgA) and surfactant which help in the defense of lungs. Respiratory epithelium also performs metabolic function. It also has fibrinolytic system for clot break down which is present in the arterial blood. Pharynx leads air into larynx through an opening called glottis. Glottis is guarded by a flap of tissue called epiglott-

is. During swallowing, the epiglottis closes the glottis. The mucous membrane of larynx forms a pair of fold, called the vocal cords, which vibrate with expelled air. Due to the vibration of vocal cords voice is produced, therefore the larynx is also called voice box [12]. Preterm infants have under developed lungs results in malformation of type II alveolar cells which produce surfactants results in increase in surface tension which leads to respiratory distress syndrome [13]. A well-known antifungal drug fluconazole is used orally or intravenously. It is used against the fungal infections such as *Candida albicans* found in oral cavity, vagina and blood. Fluconazole is also used in premature babies, impaired immunity patients and transplant patients [14]. Fluconazole was manufactured by Pfizer in 1990 [15]. Fluconazole is categorized as first generation antifungal compound used for prophylaxis *Candida albicans* infections. Prophylactic use of fluconazole can help to prevent fungal infections. Fluconazole structure has triazole ring which increases the absorption on oral administration. Drug resistance seen in the immunocompromised patients [16]. Cytochrome P-450 enzyme system is inhibited by fluconazole whose inhibition prevents the alteration of lanosterol to ergosterol a necessary factor of the fungal cytoplasmic membrane [17]. Fluconazole ceases fungal growth in different species which is dose dependent specially *Cryptococcus* [18]. *Candida albicans* can switch between various phenotypes [19]. *Candida albicans* exhibit dimorphism i.e. unicellular yeast form multicellular filamentous structure [20,21]. Chromosomal reorganization is performed by translocations, chromosomes deletions and trisomy of individual chromosomes is significant feature of *Candida albicans*. Karyotype variation results in the phenotype alteration [22]. *Candida albicans* is most common cause of infection in immunocompromised patients [23]. Blood infection due to *Candida albicans* have been related with a high mortality rate [24].

Tocopherols and tocotrienols are well known class of fat soluble vitamins [25]. Second most active form of vitamin E is  $\alpha$ -tocopherol in the diet. Vitamin E has shown antioxidant role produces non-enzymatic defense against lipid per oxidation. It performs numerous oxidative physiological activities including gene expression, enzymatic activities and neurological functions [26]. The Recommended Dietary Allowance (RDA) of vitamin E in men and women is 15 mg or 22.5 IU. For breast feeding woman it is 19 mg or 28.5 IU [27]. Vitamin E is, widely distributed throughout the body. Intracellular spreading of alpha-tocopherol is not uniform [28]. It stores in the body as efficiently as the other fat-soluble vitamins.

Excess quantity of vitamin E excrete out in the feces but remaining quantity is stored chiefly in the adipose tissues as it is lipid soluble, and less quantity is stored in the liver and other organs [29]. Alpha-Tocopherol is an important lipid-soluble antioxidant. It performs its functions as antioxidant in the glutathione peroxidase pathway [28], and it protects cell membranes from oxidation by reacting with lipid radicals produced in the lipid peroxidation chain reaction [29]. Vitamin E has many biological functions, the antioxidant function being the best known [30]. Other functions include enzymatic activities, gene expression, and neurological functions. As an antioxidant, vitamin E acts as a peroxy radical scavenger, disabling the production of damaging free radicals in tissues, by reacting with them to form a tocopheryl radical, which will then be reduced by a hydrogen donor such as vitamin C and thus return to its reduced state [31]. Fluconazole exerts beneficial effect in septic shock through unknown mechanism [32]. In this research our goal is to demonstrate the effect of vitamin E with fluconazole. Since vitamin E is an antioxidant, we would like to see the combined effect of fluconazole with vitamin E. As stated above this study explore the effect of fluconazole on lung along with vitamin E attenuates lung injury because of protective role of vitamin E. We would like to study histological (H & E stains and fixing the slides with formalin and examining them under microscope) and also pathologic changes in experimentally induced septic shock both before and after the administration of drug and vitamin under study.

## Material and Methods

Sprague Dawley albino rat sample taken for the experiment would include both 50% male and 50% female rats weighing 150-200 grams. All rats will be kept in laboratory manner at room temperature to see the effect of vitamin E with fluconazole in experimentally induced septic shock. After proper grouping of rats they will be kept in hygienic conditions in separate cages. In this research we suggest to study the combined effect of fluconazole and vitamin E. We propose to study on Sprague Dawley rats. We will choose from Sprague Dawley rats with sample size around 64 including both male and female rats. We plan to categorize 16 Sprague Dawley rats as control study, 24 Sprague Dawley rats for fluconazole alone and 24 others for fluconazole with vitamin E.

## Groups

Sixty four albino rats were divided into eight groups A, B, C1, C2, C3, D1, D2 and D3 comprising of 8 rats each.

- **Group A-** Control negative- healthy rats with normal saline treatment given and received no intervention.

- **Group B-** Control positive- infected rats with *Candida albicans* and then no treatment given.
- **Group C1-** Infected rats with *Candida albicans* are treated with fluconazole 3 mg/kg body weight given as a single dose through gastric gavage.
- **Group C2-** Infected rats with *Candida albicans* are treated with fluconazole 10 mg/kg body weight given as a single dose through gastric gavage.
- **Group C3-** Infected rats with *Candida albicans* are treated with fluconazole 30 mg/kg body weight given as a single dose through gastric gavage.
- **Group D1-** Infected rats with *Candida albicans* are treated with fluconazole 3 mg/kg body weight along with vitamin E 10mg/100gm given as a single dose through gastric gavage.
- **Group D2-** Infected rats with *Candida albicans* are treated with fluconazole 10 mg/kg body weight along with vitamin E 10mg/100gm given as a single dose through gastric gavage.
- **Group D3-** Infected rats with *Candida albicans* are treated with fluconazole 30 mg/kg body weight along with vitamin E 10mg/100gm given as a single dose through gastric gavage.

## Procedure

The animals were kept NPO (Nil per oral) overnight and doses were given between 10 - 11a.m. Group A rats are treated with normal saline. *Candida albicans* was given by gastric gavage in group B, C and D. Fluconazole with strength of 3, 10 and 30 mg/kg body weight was given by gastric gavage 60 minutes after giving *Candida albicans* in group C and D. Fluconazole with strength of 3, 10 and 30 mg/kg body weight and vitamin E 100 mg/100gm was given by gastric gavage after 30 minutes in group D.

All healthy rats were weighed between 150-200 grams and their ages were between 10-12 weeks old were included in the study. All sick or dead animals were excluded from the study. All animals were kept in humanely manner in separate cages according to group criteria. At the end of respective period of treatment animals were weighted and given chloroform anesthesia spread over a cotton sheet in a plastic container. The animals were then transferred in plastic container individually till they were fully anesthetized. The animals were then fixed on a dissection board and a midline longitudinal incision was made in the upper trunk that extended from manubrium sterni up to lower abdomen to expose the thoracic abdominal organs. Blood samples were collected through cardiac puncture with 5cc syringes into blood test tubes to detect serum CBC and CRP level through biochemical analysis.

The lung of each animal was exposed and gross appearance of the lung was observed for any change in color, shape, size, consistency and contour. It was excised and removed. The lung tissues were fixed in 10% formalin. Small pieces were cut from the fixed lungs and processed in ascending strength of alcohol, cleared in xylene and then infiltrated with and embedded in paraffin to make blocks.

Lungs will be taken out of sacrificed animals and will be embedded in paraffin and then sectioned and then stained with H & E. Blood samples were taken by cardiac puncture to estimate the infectious markers. Study of CBC and CRP was done. The levels were estimated and compared with control and correlated with histologic findings. The lung histology will be determined by intensity of septal thickening and cellular infiltration.

The slides will be examined and the following scoring system will be used.

- 0 = No histological changes
- 1 = Subtle histological changes
- 2 = Mild histological changes
- 3 = Moderate histological changes
- 4 = Severe histological changes.

Parameters

Histological parameters

- Mucosal thickness of respiratory membrane
- Disruption of epithelium of alveolus and the terminal bronchioles tubes of lung
- Inflammatory cells in respiratory membrane
- Sub mucosal glands in trachea and the terminal bronchiole

Biochemical parameters

- CRP
- TLC
- Lymphocytes
- Neutrophils

Statistical analysis

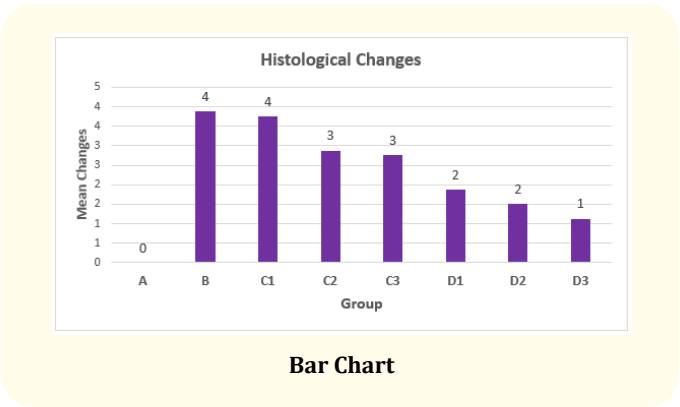
The data was analyzed on IBM SPSS version 24.0 and the results were presented as mean, standard deviation, confidence interval

for all responses like Hb. Neutrophils, TLC, Lymphocytes, CRP except Histological changes for which mean, standard deviation, minimum and maximum were reported. Graphical analysis was performed using Microsoft Excel 2016.


One Way ANOVA was applied to see the mean difference among groups. Since assumptions of normality and equal variances were proved therefore for pair-wise comparison Tukey Test was applied for TLC, Neutrophils, CRP and for Histological changes, Bonferroni test due to not having normality assumption. A p-value of 0.05 or less was consider as significant and 0.01 or less as highly significant.

Results


Total 8 groups with 64 rats samples were analyzed. Table 1 describe the descriptive statistics and comparison among all groups for all responses.



**Figure 1:** Photomicrograph of lung section of group A showing the normal architecture of lung tissue composed of thin wall alveoli on H & E 10X.




**Figure 2:** Photomicrograph of lung section of group A showing normal architecture of lung tissue composed of thin wall alveoli with single layer of squamous epithelium on H & E 10X.




**Figure 5:** Photomicrograph of lung section of group C1 "D" showing architectural distortion of lung tissue and "I" diffuse inflammatory cells on H & E 10X.




**Figure 3:** Photomicrograph of lung section of group B "A" showing architectural distortion of lung tissue, B showing chronic inflammatory cells on H & E 100X.



**Figure 6:** Photomicrograph of lung section of group C2 "R" showing few repairing of lung parenchyma tissue and mucosal thickening, "D" showing distorted tissue with inflammation on H & E stain 10X.



**Figure 4:** Photomicrograph of lung section of group B D showing architectural distortion of lung tissue, H showing hemorrhagic vessels and U showed ulceration and inflammation on H & E 4X.



**Figure 7:** Photomicrograph of lung section of group C3 "R" showing moderate repair of lung parenchymal tissue and "D" showing few distorted tissue with mild to moderate inflammation on H & E 10X.

**Figure 8:** Photomicrograph of lung section of group D1 “R” showing moderate repair of lung parenchyma with thickening of mucosa on H & E 10X.

**Figure 9:** Photomicrograph of lung section of group D2 “R” showing signs of moderate repair with mild mucosal thinning of lung parenchymal tissue on H & E 10X.

Group	Responses				
	Histo. Changes	CRP	TLC	Lymphocytes	Neutrophil
A	0 ± 0	363 ± 0.93	6.4 ± 0.19	60 ± 0.93	32 ± 0.93
(n = 8)	(0 - 0)	(362.2 - 363.7)	(6.2 - 6.6)	(59.2 - 60.8)	(31.2 - 32.8)
B	4 ± 0.35	699.3 ± 2.67	22 ± 0.93	90 ± 0.93	90 ± 1.85
(n = 8)	(3 - 4)	(697.1 - 701.6)	(21.2 - 22.8)	(89.2 - 90.8)	(88.5 - 91.6)
C1	4 ± 0.46	680 ± 1.85	20.8 ± 0.71	88 ± 0.93	85 ± 0.93
(n = 8)	(3 - 4)	(678.4 - 681.5)	(20.2 - 21.3)	(87.2 - 88.8)	(84.2 - 85.8)
C2	3 ± 0.35	670 ± 1.85	20 ± 0.76	86 ± 0.93	81 ± 0.93
(n = 8)	(2 - 3)	(668.4 - 671.5)	(19.4 - 20.6)	(85.2 - 86.8)	(80.2 - 81.8)
C3	3 ± 0.46	610 ± 1.85	17.5 ± 0.53	85 ± 0.93	72 ± 0.93
(n = 8)	(2 - 3)	(608.4 - 611.5)	(17.1 - 17.9)	(84.2 - 85.8)	(71.2 - 72.8)
D1	2 ± 0.35	560 ± 1.85	15.5 ± 0.53	80 ± 0.93	62.1 ± 1.46
(n = 8)	(1 - 2)	(558.4 - 561.5)	(15.1 - 15.9)	(78.2 - 82.8)	(60.9 - 63.3)
D2	2 ± 0.54	425 ± 2.78	11.6 ± 0.74	78.5 ± 1.85	52 ± 1.85
(n = 8)	(1 - 2)	(422.6 - 427.3)	(11 - 12.2)	(76.5 - 80.5)	(50.5 - 53.6)
D3	1 ± 0.35	345 ± 1.85	9.9 ± 0.83	70 ± 1.85	48.6 ± 0.84
(n = 8)	(1 - 2)	(343.4 - 346.5)	(9.2 - 10.6)	(68.4 - 71.6)	(47.4 - 49.8)
P-value	< 0.001**	< 0.001**	< 0.001**	< 0.001**	< 0.001**
**Significant at 1%					
'Mean ± SD					
99% C.I (L.L - U.L)					

**Table 1:** Descriptive analysis of Histological changes, CRP, TLC, Lymphocytes and Neutrophils among Groups.



**Figure 10:** Photomicrograph of lung section of group D3 "R" showing sign of moderate repair with moderate mucosal thinning of lung parenchymal tissue on H & E 10X.

The present study reveals that *Candida albicans* has distorting effects on lung mucosa and treatment with fluconazole along with vitamin E decreases the elevated levels of TLC, Lymphocytes, CRP and neutrophils and attenuates the lung injury.

## Discussion and Conclusion

The present study explores the substantial evidence regarding the significant role of vitamin E with fluconazole in lung injury. Acute lung injury is a disorder of acute inflammation that causes disruption of the lung endothelial and epithelial barriers. The alveolar capillary membrane is comprised of the microvascular endothelium, interstitium, and alveolar epithelium. Cellular characteristics of acute lung injury includes loss of alveolar-capillary membrane integrity, excessive transepithelial neutrophil migration, and release of pro-inflammatory, cytotoxic mediators [33,34]. Biomarkers found on the epithelium and endothelium and that involved in the inflammatory and coagulation cascades predict morbidity and mortality in acute lung injury. Following infection or trauma, upregulation of proinflammatory cytokines occurs as a direct response and as a marker of ongoing cellular injury. Meduri, *et al.* found that baseline and persistently elevated plasma levels of interleukin (IL)-6, IL-8, and tumor necrosis factor (TNF)- $\alpha$  are strongly predictive of mortality [35]. On administering the *Candida albicans* in albino rats, severe lung injury was noted followed by septic shock, including tachypnea, piloerection, writhing, diarrhea, frothing from nose and mouth, loose skin, and immobilization of the animals within 72 hours.

In this study Sprague Dawley rats have been used. The physiologic and metabolic processes of rodents are resembled with those

of humans because of resemblance in genome. Approximately 80% of rodents animals are used in the experimental study [36]. Millions of rats are used in research study around the world yearly. Wistar and Sprague Dawley are two most common strains used for research [37].

Fluconazole has been reportedly found to be effective in the infection caused by *Candida albicans*. Administering fluconazole along with vitamin E increased the constructive effects on lung injury. The administration of greater amount of fluconazole along with vitamin E showed better results when compared to the control group.

Our present study was aimed at assessing the role of antifungal, free radical scavenger and their combination in prevention and limiting the effect of shock. We also investigated some clinical parameters in our study to observe CRP, neutrophil count, TLC and lymphocytes.

In group A there are no histological changes and the value of CRP, neutrophils, TLC and lymphocytes are within the normal ranges.

In group B after administration of *Candida albicans* severe histological changes occur i.e., architectural distortion of lung tissue and chronic inflammatory cells, hemorrhagic vessels and ulceration. After the inoculation of *Candida albicans* the elevated levels of CRP are observed because of acute phase inflammation which corresponds to the Kostiala, *et al.* elevated values of CRP were seen in patients with fungal septicemia before within a few days after the first positive blood culture [38]. There is increased number of neutrophils secondary to acute inflammation in contrast to Hpoke, *et al.* neutrophil-initiated cell wall disruptions augment some macrophage cytokine responses to attacked fungi [39]. The TLC level is also elevated due to acute inflammation. Increased level of lymphocytes are also observed resembling Ashman, *et al.* that during the cell-mediated immunity response to fungi, lymphocytes can release cytokines that not only enhance CMI but also modulate the antifungal activity of polymorphonuclear leukocytes and macrophages [40].

In group C after treating infected rats with 3mg, 10mg and 30mg of fluconazole, the constructive effects are noted i.e., repairing of few lung parenchyma tissue and mild mucosal thickening resembling Kathiravan, *et al.* that azole antifungals act by inhibit-

ing ergosterol biosynthesis via the cytochrome P450 enzyme 14- $\alpha$  demethylase, which catalyzes the conversion of lanosterol to ergosterol. Azoles affect the integrity of fungal membranes, altering their morphology and inhibiting growth [41]. The elevated level of CRP gradually goes down and decrease in the number of neutrophils and a minor decrease in the number of TLC and lymphocytes are observed.

In group D on administrating the fluconazole along with vitamin E in infected rats shows the signs of moderate repair with mild mucosal thinning of lung parenchyma tissue resembling Fakhruddin, *et al.* that antioxidant vitamins E and C as adjunct therapy lower respiratory infection in infants and young children [42] The CRP level comes within the normal ranges which is the sign of progressive recovery. There is decrease in the number of neutrophils and TLC resembling Timonen, *et al.* that patients with acute leukaemia CRP level increases proved most valuable in the follow up of fungal infections, in the detection of infectious complications and in the detection of possible invasive fungal infection [43] The level of lymphocytes goes down to normal level.

The antifungal and antioxidant combination of group D is superior to group C in which fluconazole was administrated alone. Therefore fluconazole and vitamin E gave better results as compared to group C and similar results when compared with control group. Lung injury improves in fluconazole 30mg/kg along with vitamin E 100 mg /100 gm of body weight proven by histological finding and CRP level. Fluconazole and vitamin E showed significant improvement over the control group, probably the local free radical scavenger action provided vitamin E.

Our results coincides with the study reported (Tariq, *et al.*) Intra-peritoneal administration of rats with homogenous fecal suspension produced the characteristic symptoms of peritonitis followed by death (only 20% survival) of the animals within 72 hours. Treatment of animals with fluconazole dramatically improved the symptoms and increased the survival 90% rate. Although the protective effect of fluconazole against *Candida albicans* s peritonitis has been reported [44]. In our study after the treatment of fluconazole along with vitamin E drastic improvement in signs and symptoms was noted proved by histological parameters. Even more improvements are observed when given in greater doses of fluconazole along with vitamin E because of antioxidant property of vitamin E.

The aim of the present study is to observe the distorting effects *Candida albicans* on lung mucosa and to establish improved effects of fluconazole along with vitamin E on lung injury and to decrease the elevated levels of TLC, Lymphocytes, CRP, neutrophils and attenuate the lung injury. The significance of vitamin E was observed in contrast to Morita, *et al.* that vitamin E supplementation (alpha-tocopherol) would attenuate acute lung injury induced by burn and smoke inhalation injury [45].

## Recommendation

Recommended to apply that study on human. The clinical trial can be applied for the betterment of community health.

## Bibliography

1. Singer M., *et al.* "The Third International Consensus Definitions for Sepsis and Septic Shock (Sepsis-3)". *Journal of the American Medical Association* 315.8 (2016): 801-810.
2. Jui Jonathan. In Tintinalli, Judith E.; Stapczynski, J. Stephan; Ma, O. John; Cline, David M.; et al. Tintinalli's Emergency Medicine: A Comprehensive Study Guide (7th ed.). New York: McGraw-Hill. Ch. 146: Septic Shock" (2012): 1003-1014.
3. Kumar V., *et al.* "Robbins Basic Pathology (8th ed.)". Saunders, Elsevier (2017): 102-103.
4. Melis M., *et al.* "Bowel necrosis associated with early jejunal tube feeding: A complication of postoperative enteral nutrition". *Archives of Surgery* 141.7 (2006): 701-704.
5. Jun-Gyo Gwon., *et al.* "Enteral nutrition associated non-occlusive bowel ischemia". *Journal of Korean Surgical Society* 83.3 (2012): 171-174.
6. Angus Derek C and van der Poll Tom. "Severe Sepsis and Septic Shock". *New England Journal of Medicine* 369.9 (2013): 840-851.
7. Martin GS. "Sepsis, severe sepsis and septic shock: changes in incidence, pathogens and outcomes". *Expert Review of Anti-infective Therapy* 10.6 (2012): 701-706.
8. Dellinger RP, *et al.* "Surviving Sepsis Campaign: International guidelines for management of severe sepsis and septic shock". *Critical Care Medicine* 41.2 (2013): 580-637.
9. Maton A., *et al.* "Human Biology and Health". Prentice Hall, Englewood Cliffs. New Jersey (2010): 108-118.
10. Tortora J., *et al.* "Principles of anatomy and physiology, 13th edition". Harper and Row, New Jersey (2012): 570-572.



11. Von Euler Liljestrand US. "Observations on the pulmonary arterial blood pressure in the rat". *Acta Physiologica Scandinavica* 12 (1946): 301-320.
12. West JB. "Respiratory physiology". The essentials, Baltimore: Williams and Wilkins (1985): 21-30, 84-84, 98-101.
13. Sullivan LC and Orgeig S. "Lung Development and Respiratory Distress Syndrome". *American Journal of Physiology* 3 (2010): 770-778.
14. "Fluconazole (Diflucan): Drug Safety Communication - FDA Evaluating Study Examining Use of Oral Fluconazole (Diflucan) in Pregnancy". FDA (2016).
15. "WHO Model List of Essential Medicines". World Health Organization (2013).
16. Bennett JE. "Antifungal Agents". Chabner B.A. Knollmann B.C, Goodman and Gilman's The Pharmacological Basis of Therapeutics, In L.L. Brunton 12e (2012).
17. Fluconazole monograph. The American Society of Health-System Pharmacists (2014).
18. Pfizer Australia Pvt Ltd. Diflucan (Australian Approved Product Information). West Ryde (NSW): Pfizer Australia (2004).
19. Tortora Gerald J. "An Introduction of Microbiology". San Francisco. CA Pearson Benjamin Cummings (2010): 758.
20. Mukherjee PK, *et al.* "Mycobiota in gastrointestinal diseases". *Nature Reviews Gastroenterology and Hepatology* 12.2 (2014): 77-87.
21. Ohama T, *et al.* "Non-universal decoding of the leucine codon CUG in several *Candida* species". *Nucleic Acids Research* 21.17 (1993): 1039-4045.
22. Andrzej AE and Ostell J. "The Alternative Yeast Nuclear Code". The Genetic Codes. Bethesda, Maryland, U.S.A.: National Center for Biotechnology Information (NCBI). 31.3 (2010): 937-947.
23. Sydnor Emily. "Hospital Epidemiology and Infection Control in Acute-Care Settings". *Clinical Microbiology Reviews* 24 (2011): 141-173.
24. Weinberger M. "Characteristics of candidaemia with *Candida albicans* compared with non-*albicans* *Candida* species and predictors of mortality". *Journal of Hospital Infections* 61 (2016): 146-154.
25. "Vitamin E — Health Professional Fact Sheet". Office of Dietary Supplements, US National Institutes of Health (2016).
26. Angelo Azzi A and Stocker A. "Vitamin non oxidative role". 39.31 (2000): 231-255.
27. Story M and Stang J. "Nutritional needs of adolescents". Guidelines for adolescent nutrition services. Division of Epidemiology and Community Health, School of Public Health, University of Minnesota. (2005): 21-34.
28. Wang X, *et al.* "Vitamin E and its function in membranes". *Progress in Lipid Research* 38.4 (1999): 309-360.
29. Gropper S and Smith JL. "Fat soluble Vitamins: Advanced human nutrition". Jones and amp: Barlett Publishers. Burlington (2013): 284.
30. Traber MG. "Vitamin E Inadequacy in Humans: Causes and Consequences". *Advances in Nutrition* 5 (2014): 503-514.
31. Norhona-Blob N, *et al.* "Reduces mortality associated with sepsis in rats". *Journal of Pharmacology and Experimental Therapeutics* 267 (1993): 664-666.
32. Tariq M. "Fluconazole attenuates lung injury and mortality in a rat peritonitis model". *Intensive Care Medicine* (2003) 29:2043-2049.
33. MUSTAFA N, *et al.* "İnsan-COVID-19'da Pandemik SARS coronavirus-2 Enfeksiyonları". *İstanbul Gelişim Üniversitesi Sağlık Bilimleri Dergisi* 10 (2020): 77- 93.
34. "Outbred rats - Sprague Dawley Outbred Rat". Harlan Laboratories - Animal Research Laboratory - Contract Research Services (2012).
35. Kostiala I. "C-reactive protein response induced by fungal infections". *Journal of Infection* 8.3 (1984): 212-220.
36. Hpoke A, *et al.* "Neutrophil Attack Triggers Extracellular Trap-Dependent *Candida* Cell Wall Remodeling and Altered Immune Recognition". *Plos Pathogens* (2016).
37. Ashman RB. "Cell-mediated immune responses correlate directly with susceptibility and resistance to infection". *Immunology and Cell Biology* 68 (1990): 15-20.
38. Kathiravan MK, *et al.* "The biology and chemistry of antifungal agents: a review". *Bioorganic and Medicinal Chemistry* 20.19 (2012): 5678-5698.

39. Fakruddin M., *et al.* "Antimicrobial and antioxidant activities of *Saccharomyces cerevisiae* IFST062013, a potential probiotic". *BMC Complementary and Alternative Medicine* 17 (2017): 64.
40. Timonen TT and Koistinen P. "C-reactive protein for detection and follow-up of bacterial and fungal infections in severely neutropenic patients with acute leukaemia". *European Journal of Cancer and Clinical Oncology* 21.5 (1985): 557-562.
41. Mustafa N., *et al.* "Collaborative learning aspect for training hip and knee joint anatomy". *Journal of Rheumatic Diseases and Treatment* 1 (2020): 13-16.
42. Tariq M., *et al.* "Fluconazole attenuates lung injury and mortality in a rat peritonitis model". *Intensive Care Medicine* 29 (2003): 2043-2049.
43. Morita N., *et al.* "Vitamin E attenuates acute lung injury in sheep with burn and smoke inhalation injury". *Redox Report* 11.2 (2006): 61-70.
44. Barbara Y., *et al.* "Wheatear's Functional Histology". Churchill Livingstone (2013): 207-208.
45. Peckham M. "Histology at a Glance". Wiley-Blackwell. Churchill Livingstone (2011): 67.

#### Assets from publication with us

- Prompt Acknowledgement after receiving the article
- Thorough Double blinded peer review
- Rapid Publication
- Issue of Publication Certificate
- High visibility of your Published work

**Website:** [www.actascientific.com/](http://www.actascientific.com/)

**Submit Article:** [www.actascientific.com/submission.php](http://www.actascientific.com/submission.php)

**Email us:** [editor@actascientific.com](mailto:editor@actascientific.com)

**Contact us:** +91 9182824667