



N The Significance of Hyponatremia Assessment Before Surgical Intervention on the Confusion Table in the Borderline Subdural Hematoma

Ozdemir Ugur*

Neurosurgery, Beykoz State Hospital, Turkey

*Corresponding Author: Ozdemir Ugur, Neurosurgery, Beykoz State Hospital, Turkey.

Received: December 30, 2019

Published: January 09, 2020

© All rights are reserved by **Ozdemir Ugur.**

Abstract

The aim of presenting this phenomenon was to emphasize that changes in the consciousness table in a patient with traumatic borderline subdural hematoma may depend not only on hematoma but also on hyponatremia. Our case was a 60 year old, confused patient with borderline subdural hematoma on CT examination. The patient had deep hyponatremia at the same time. While the patient was followed up with clinical, radiological and laboratory findings, it was seen that the hematoma continued at the same size, but the consciousness was totally opened by the treatment of hyponatremia and even the patient could be mobilized. In conclusion, a patient who has undergone trauma and has surgically borderline subdural hematoma should not be rushed for surgery. In such patients, urgent electrolyte evaluations especially for hyponatremia should be done first, and this should be corrected.

Keywords: Traumatic Brain Injury; Borderline Subdural Hematoma; Hyponatremia; Inappropriate Antidiuretic Hormone Secretion Syndrome

Introduction

For neurosurgeons, subdural hematoma is often considered a condition that requires immediate surgery. However, hyponatremia, syndrome of inappropriate antidiuretic hormone secretion (SIADH) and cerebral salt-wasting syndrome (CSWS) are very important in clinical practice of neurosurgery. If this fine detail is not overlooked, patients are protected from unnecessary operations. Our patient had characteristics that could cause this confusion. We did not rush to the surgical option and corrected hyponatremia. Thus, the patient's clinic improved without surgical intervention. We wanted to present this case in order to express this attention.

Case description

Our case is a 60-year-old male patient. When the patient was brought to the hospital emergency department as a result of head trauma, the patient was in a confused state and was blinking with an audible stimulus. So the eye score of glasgow coma scale was two (GCSE = 2). Verbal communication was confused level. So the verbal score of glasgow coma scale was four (GCSV = 4). He was localizing the painful stimulus. So the motor score of glasgow coma scale was five (GCSM = 5). So the total GCS score was 11 (Table 1).

Laboratory measurements

The first cranial computed tomography scan of the patient had subdural hematomas of about 1 cm at its widest point and cranial

Eye	Verbal		Motor		
	Score		Score		
Spontaneous	4	Orientated	5	Obey commands	6
To sound	3	Confused	4	Localising	5
To pressure	2	Words	3	Normal flexion	4
None	1	Sounds	2	Abnormal flexion	3
		None	1	Extension	2
			None	1	

Table 1: The Glasgow Coma Scale.

fractures. (Figure 1 and 2) Significant hyponatremia was the notable finding in the hospital laboratory examination of the emergency department (124 mmol/l).

Clinical course

The patient was followed up clinically, laboratory and radiologically. While there was no radiologic difference in cranial computed tomography taken on the same day and other days, clinically significant improvement occurred with early treatment of the hyponatremic table (Figure 3).

Following the treatment of hyponatremia, the blood sodium level rose to 127 mmol/l on the first day, 128 mmol/l on the next day

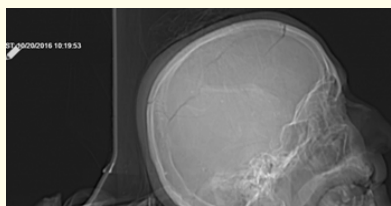


Figure 1: Common cranial fractures.

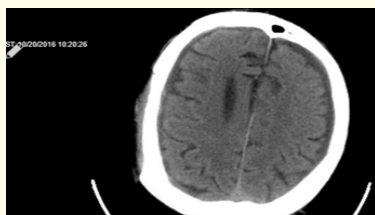


Figure 2: Borderline subdural hematoma and effusion in first cranial CT scan.

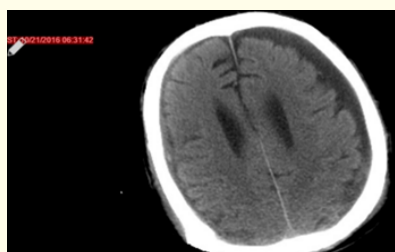

Figure 3: Hematoma of the same size at following CT.

and 139 mmol/l in a few days. Despite the absence of radiological regression in the hematoma or effusion of the patient, the patient's consciousness was fully opened with the recovery of hyponatremia and the patient began to establish normal verbal communication and began taking orders. So the GCS score was 15. The patient could be mobilized by opening the consciousness.

Comments

In traumatic brain injuries, effects due to electrolyte disturbances are as important as those due to direct neural tissue loss in patients' symptomatic charts. The most common of these charts are electrolyte imbalances due to "inappropriate antidiuretic hormone secretion syndrome" or "cerebral salt-wasting syndrome" tables [1]. And the most important electrolyte disorder is hyponatremia. For hyponatremia that occurs in these conditions, "inappropriate antidiuretic hormone secretion syndrome" is of higher priority than "cerebral salt-wasting syndrome" [2]. In the body water and sodium imbalance, damage to the brain tissue is important. Therefore, the improvement of brain tissue damage is important in the

recovery of this imbalance [3]. The presence of hyponatraemia and the level of brain edema in brain computerized tomography are closely related. In this respect, computerized tomography is more important than the Glasgow Coma Scale [4]. Acute hyponatremia, especially in traumatic situations, is more likely to cause acute brain edema than chronic hyponatremia. In addition, the patient's clinic is more disrupted in acute hyponatremia than in chronic hyponatremia. As brain edema increases, hyponatremia deepens [5]. In traumatic brain injuries, hypokalaemia is also a common finding as an electrolyte imbalance. But it's not as important as hyponatremia [6]. Serum sodium levels are more correlated with diffuse brain lesions than focal brain lesions [7]. Hyponatremia is also the primary clinical table in diffuse clinical tables such as viral brain infections [8]. In patients with traumatic brain injury, hyponatremia is more likely to develop if GCS is below 8, if cerebral edema is predisposed and if skull base fracture is present [9]. The purpose of presenting this phenomenon is not to open the cause of hyponatremia in traumatic brain-damaged patients. It is important to know that changes in consciousness patterns in a patient with posttraumatic borderline subdural hematoma may be due not only to hematoma but also to hyponatremia. In other words, it is important to emphasize that such patients should not be rushed for surgery without emergency electrolyte assessments. Literature surveys have shown that sometimes emergency surgical procedures can worsen hyponatremia and clinical deterioration [10].

Formatting of Funding Sources

This research did not receive any specific grant from funding agencies in the public, commercial, or not-for-profit sectors.

Assets from publication with us

- Prompt Acknowledgement after receiving the article
- Thorough Double blinded peer review
- Rapid Publication
- Issue of Publication Certificate
- High visibility of your Published work

Website: <https://www.actascientific.com/>

Submit Article: <https://www.actascientific.com/submission.php>

Email us: editor@actascientific.com

Contact us: +91 9182824667