

Impact of Mild Alzheimer Changes in Vascular Dementia: A Neuropathological Study

Jacques De Reuck*, Florent Auger, Nicolas Durieux, Vincent Deramecourt, Charlotte Cordonnier, Florence Pasquier, Didier Leys and Regis Bordet

Université Lille 2, INSERM U1171, Degenerative and Vascular Cognitive Disorders, CHR Lille, France

***Corresponding Author:** Jacques De Reuck, Professor, Université Lille 2, INSERM U1171, Degenerative and Vascular Cognitive Disorders, CHR Lille, France.

Received: April 24, 2019; **Published:** May 17, 2019

Abstract

Background: Vascular dementia (VaD) is mainly due to small-vessel disease involving primarily loss of myelin and axons in the white matter, and the presence of frequent lacunar infarcts. The present post-mortem study investigates in which way mild Alzheimer disease (AD) features can influence the occurrence of cerebrovascular lesions in VaD.

Materials and Methods: Thirty brains of patients with VaD were examined: 18 pure forms and 12 with additional mild AD features. In addition to the macroscopic examination, a whole coronal section at the level of the mamillary body was used to quantify the severity of the small cerebrovascular lesions. Also 7.0-tesla MRI was performed on 3 coronal sections of a cerebral hemisphere to determine the distribution and the severity of these lesions.

Results: The “pure” VaD brains were characterized by a predominance of lacunar infarcts, equally distributed in the 3 MRI sections. The VaD-mild AD brains had significantly more cerebrovascular lesions including cerebral amyloid angiopathy, lobar haematomas, territorial infarcts and cortical micro-bleeds and micro-infarcts. White matter changes were equally severe in both groups.

Conclusions: VaD brains with additional mild AD have more diverse and more severe cerebrovascular lesions, due to associated cerebral amyloid angiopathy. In “pure” VaD lacunar infarcts due to arteriosclerotic micro-angiopathy are the predominant lesions.

Keywords: Neuropathology; Post-mortem 7.0-tesla MRI; Vascular Dementia; Alzheimer Features; Lacunar Infarcts; Lobar Haematomas; Territorial Infarcts; Cortical Micro-Infarcts; Cortical Micro-Bleeds; White Matter Changes

Abbreviations

VaD: Vascular Dementia; AD: Alzheimer’s Disease; WMCs: White Matter Changes; CoMBs: Cortical Micro-Bleeds; CoMIs: Cortical Micro-Infarcts; LIs: Lacunar Infarcts; LHs: Lobar Haematomas; TIs: Territorial Infarcts; CAA: Cerebral Amyloid Angiopathy; MRI: Magnetic Resonance Imaging.

Introduction

The most common forms of vascular dementia (VaD) are those due to a subcortical vascular encephalopathy, to strategic infarcts or to a multi-infarct encephalopathy [1]. In recent years cerebral small-vessel disease, characterised by arteriosclerosis, lacunar infarcts (LIs), cortical micro-infarcts (CoMIs) and diffuse white

matter changes (WMCs), is considered to be the most important substrate for the vascular cognitive impairment [2]. LIs and diffuse loss of myelin and axons in the centrum semiovale are the main lesions of VaD [3]. LIs are rarely haemorrhagic although the incidence of the latter can increase in the presence of an intracerebral haemorrhage [4]. Also there is no increase of iron, reflecting the presence of frequent micro-bleeds, in ischaemic white matter disease [5]. The LIs and WMCs are more frequent in “pure” VaD than in mixed neurodegenerative- VaD dementia syndromes [6]. However, mild Alzheimer’s disease (AD) pathology and small vessel disease can interact synergistically [7]. AD pathology is less severe in the presence of cerebral vascular lesions [8]. AD brains with severe CAA contain more lobar LHs, CoMIs, CoMBs and more severe

WMCs than those without CAA [9]. CAA has a greater prevalence in VaD than in normal controls [10]. On the other hand cerebrovascular lesions due to cerebral amyloid CAA are often less severe when associated to AD pathology [11]. In subjects with no/sparse neuritic plaques, non-haemorrhagic brain infarcts are more common in those with CAA pathology than in those without [12]. On *in vivo* magnetic resonance imaging (MRI) the presence of subacute small infarcts in advanced CAA is associated with a higher burden of haemorrhages [13].

Nothing is known about the impact of mild AD features in patients with a definite diagnosis of VaD. The present neuropathological study with post-mortem 7.0-tesla MRI investigates whether minor AD changes, in contrast to those observed the end-stage of this neurodegenerative disease, have a different or no impact on the occurrence of various cerebrovascular lesions in VaD patients.

Materials and Methods

Thirty patients with VaD not associated to a severe neurodegenerative disease, which has been followed up at the Lille University Hospital, underwent an autopsy. A previously obtained informed consent from the nearest family allowed the autopsy for diagnostic and scientific purposes. The brain tissue samples were acquired from the Lille Neuro-Bank of the Lille University, federated to the "Centre des Ressources Biologiques" that acted as an institutional review board.

Eighteen VaD brains without any neurodegenerative changes were compared to 12 with mild AD pathology in the temporal lobes (grade I-III according to the Braak and Braak criteria) [14]. The post-mortem assessment of VaD was done according to the consensus criteria of the neuropathology group at the 9th international congress of vascular dementia [15]. The post-mortem diagnosis of CAA was made according to a recent consensus protocol and their degree was evaluated semi-quantitatively in 4 cortical samples and graded from 0 to 3 [16].

The standard procedure consisted of examining samples from the primary motor cortex, the associated frontal, temporal and parietal cortex, the primary and secondary visual cortex, the cingulate gyrus, the basal nucleus of Meynert, the amygdaloid body, the hippocampus, basal ganglia, mesencephalon, pons, medulla and cerebellum. Slides from paraffin-embedded sections were stained with haematoxylin-eosin, luxol fast blue and Perl. Immune-staining for protein tau, β -amyloid, α -synuclein, prion protein, TDP-43

and ubiquitin was also performed. A whole coronal section at the level of the mamillary body was used to quantify the severity of the small cerebrovascular lesions on microscopical examination [17].

On 7.0-tesla MRI 3 coronal sections of a cerebral hemisphere were examined for quantification of the small cerebrovascular lesions. We used a 7.0-T MRI Bruker BioSpin SA (Ettlingen, Germany). The samples were placed in an issuer-receiver cylinder coil with inner diameter of 72 mm. Three MRI sequences were used: a positioning sequence, a T2 sequence and a T2 * sequence [18]. Large cerebrovascular lesions such as LHs and TIs, although also detectable on MRI, were not quantified on the 3 sections, as their numbers were less representative and better detected on the macroscopic examination of the brain. The topography and the quantification of LIs were on the other hand also determined on the MRI sections.

Statistical analysis consisted in unvaried comparisons of unpaired groups, performed with the Fisher's exact test for categorical data. The non-parametric Mann-Whitney U-test was used to compare continuous variables. The significance level, two-tailed, was set at ≤ 0.05 for moderately significant, at ≤ 0.01 for significant and at ≤ 0.001 for highly significant.

Results

The age groups of the VaD patients without and with mild AD pathology were similar with 76 (SD: 6) years in the former and 77 (SD: 6) years in the latter group. Also the gender distribution was not statistically different with 83% males in the former and 50% in the latter group.

The neuropathological examination revealed no differences in the degree of WMCs between both groups. Significant differences in the severity of the other cerebrovascular lesions were observed concerning CAA, LHs, TIs, CoMIs and CoMBs, which were considerably more present in the VaD group with mild AD pathology (≤ 0.01). On the other hand LIs were more frequent in the "pure" VaD group (≤ 0.01) (Table 1).

An example of a LH is shown on MRI in figure 1 and of a small cortical haemorrhagic infarct in figure 2 of two VaD different brains with mild AD pathology. LIs are demonstrated on the MRI in the brains of 2 different patients with "pure" VaD (Figure 3 and 4).

Items	pure" VaD (n= 18)	VaD-mild AD (n= 12)	P values
White matter changes	1.7 (1.1)	2.0 (0.6)	N.S.
Cerebral amyloid angiopathy	0.6 (0.9)	2.2 (0.9)	≤ 0.01
Lacunar infarcts	1.8 (0.5)	0.7 (0.7)	≤ 0.01
Territorial infarcts	0.6 (0.7)	1.6 (0.8)	≤ 0.05
Lobar haematomas	0.2 (0.2)	1.4 (1.1)	≤ 0.01
Cortical micro-infarcts	1.9 (1.7)	5.2 (0.8)	≤ 0.01
Cortical micro-bleeds	2.2 (1.1)	4.5 (1.3)	≤ 0.01

Table 1. Comparison of the severity of the different cerebrovascular lesions (standard deviation) on the neuropathological examination of the vascular dementia brains without (VaD) compared to those with mild Alzheimer’s disease changes (VaD-mild AD)

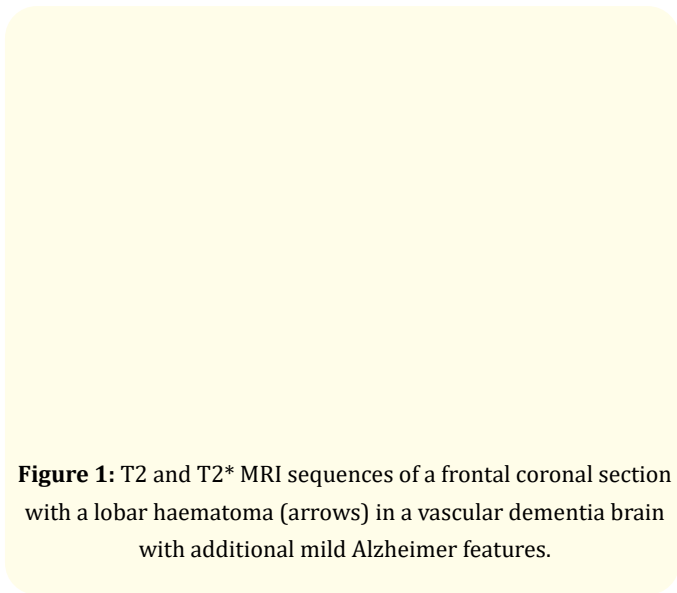


Figure 1: T2 and T2* MRI sequences of a frontal coronal section with a lobar haematoma (arrows) in a vascular dementia brain with additional mild Alzheimer features.

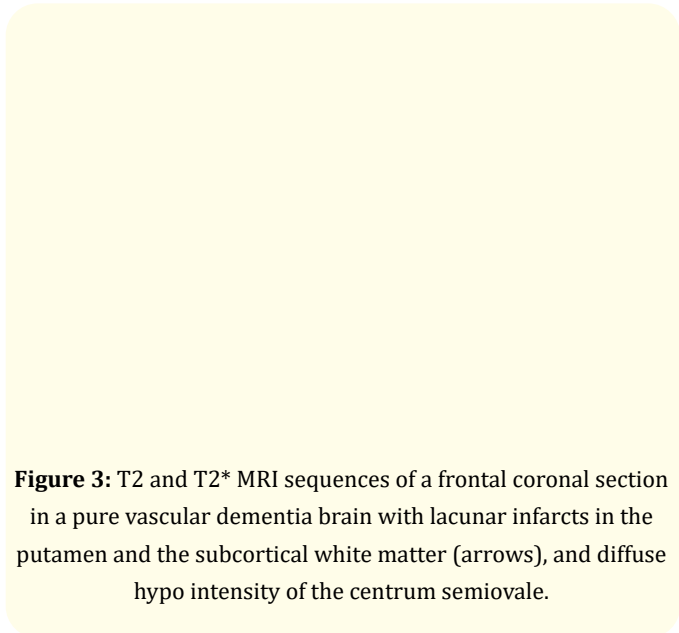


Figure 3: T2 and T2* MRI sequences of a frontal coronal section in a pure vascular dementia brain with lacunar infarcts in the putamen and the subcortical white matter (arrows), and diffuse hypo intensity of the centrum semiovale.

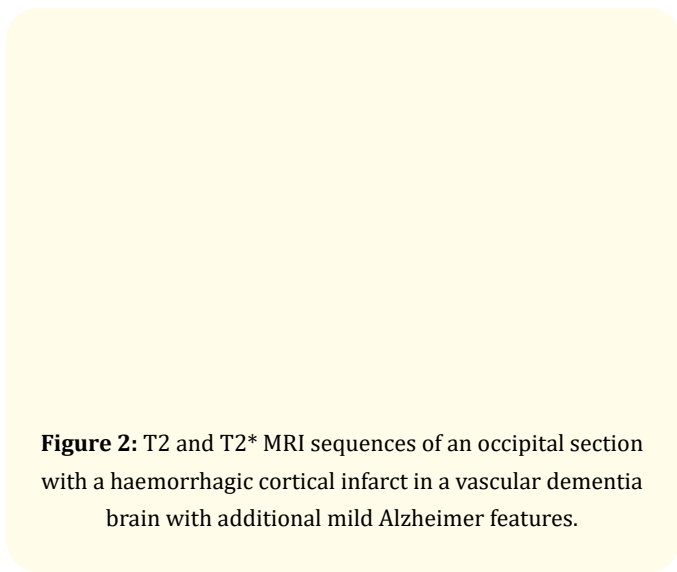


Figure 2: T2 and T2* MRI sequences of an occipital section with a haemorrhagic cortical infarct in a vascular dementia brain with additional mild Alzheimer features.

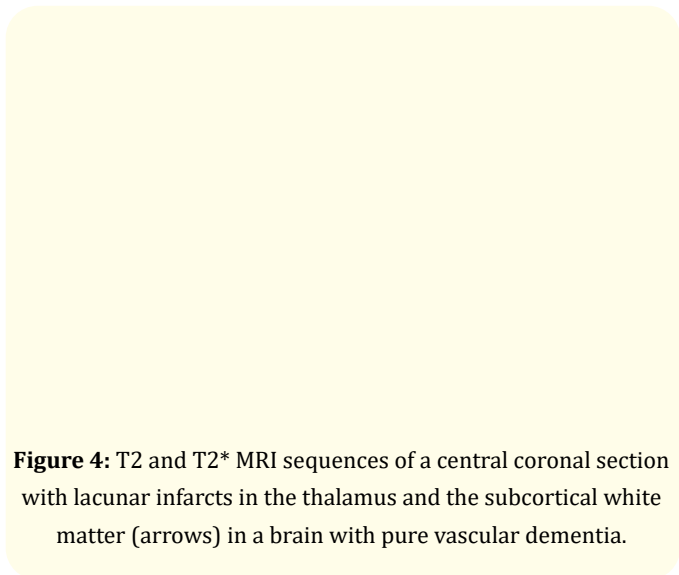


Figure 4: T2 and T2* MRI sequences of a central coronal section with lacunar infarcts in the thalamus and the subcortical white matter (arrows) in a brain with pure vascular dementia.

On MRI examination diffuse ischaemic WMCs were more or less equally present in the 3 separate hemispheric sections of both groups. CoMIs were more frequent in the different cerebral sections of the VaD-mild AD group (≤ 0.01), although to some extent less pronounced in the central section (≤ 0.05). CoMBs were only significantly increased in the central section of the VaD group with

mild AD features (≤ 0.01). On the other hand LIs were significantly increased in the frontal sections of “pure” VaD brains without AD pathology (≤ 0.01), and to some extent prominent in the central and parieto-occipital sections (≤ 0.05) (Table 2). They were more or less equally present in the basal ganglia and in the centrum semiovale.

Items	VaD (n= 18)	VaD-mild AD (n= 12)	P values
White matter changes			
Frontal section	1.3 (0.9)	1.4 (1.0)	N.S.
Central section	1.8 (1.2)	1.5 (1.0)	N.S.
Parieto-occipital section	1.3 (1.0)	1.4 (1.1)	N.S.
Cortical micro-infarcts			
Frontal section	1.0 (0.2)	2.3 (0.6)	≤ 0.01
Central section	1.2 (0.6)	2.5 (1.0)	≤ 0.05
Parieto-occipital section	1.4 (0.7)	2.5 (0.6)	≤ 0.01
Cortical micro-bleeds			
Frontal section	2.3 (0.8)	3.0 (0.8)	N.S.
Central section	2.0 (0.8)	3.8 (1.0)	≤ 0.01
Parieto-occipital section	2.7 (0.9)	3.4 (0.5)	N.S.
Lacunar infarcts			
Frontal section	1.5 (0.8)	0.3 (0.1)	≤ 0.01
Central section	1.4 (1.0)	0.4 (0.6)	≤ 0.05
Parieto-occipital section	1.5 (0.8)	0.3 (0.8)	≤ 0.05

Table 2: Comparison of the severity of the small cerebrovascular lesions (standard deviation) on magnetic resonance imaging between vascular dementia brains without (VaD) and those with mild Alzheimer’s disease changes (VaD-mild AD).

Discussion

The present study shows that patients with VaD associated to mild AD features have significantly more cerebrovascular lesions than those without this association. While in the pure form of VaD the predominant responsible lesions are LIs, CAA appears to be the most important cause of the other cerebrovascular lesions, independently from the degree of associated AD pathology. The findings are surprising as in our previous studies only mixed dementia brains had more CAA related cerebrovascular lesions [19]. Also CAA can be found of in 45% of brains with Lewy body dementia, depending on the degree of associated AD features [20,21].

Brains with “pure” CAA have more extensive cerebrovascular lesions than those associated to AD [11]. Our VaD patients with

mild AD fulfil all the diagnostic Boston criteria for CAA [22]. CAA is known to contribute to dementia in early AD pathogenesis [23]. CAA must be in part considered as a protein elimination failure angiopathy [24]. Also several studies have shown that CAA not always fully overlap with AD and can contribute to cortical atrophy mediated by vascular dysfunction [25,26].

While CoMIs and non-haemorrhagic brain infarcts are more common in those with CAA [27,28], we can not confirm that CAA is more significantly correlated to the severity of the WMCs [29].

Also the increase of the CoMBs in the present study is restricted to the central MRI section and not diffuse, which correlates more with our previous observation that the AD features are more re-

sponsible than the CAA itself for these lesions [30]. Also the increase of CoMIs cannot be attributed to the CAA alone as the severity of the neurodegenerative changes are aggravated in CAA brains with severe AD features [31].

Increase of cerebrospinal fluid biomarkers of neuroinflammation in early Alzheimer disease could be the responsible factors why CAA is accountable for the increased cerebrovascular dysfunction in VaD with mild AD pathology [33].

Conclusion

In VaD mild additional AD features contributes to more severe and diverse cerebrovascular lesions due to the severity of the CAA. This is quite different from the “pure” form of VaD, in which the predominant lesions are LIs.

Funding Source

No sponsoring or funding was obtained.

Conflicts of Interest

The authors have no conflict of interest to declare.

Bibliography

1. Thal DR., et al. “Vascular dementia: different forms of vessel disorders contribute to the development of dementia in the elderly brain”. *Experimental Gerontology* 47.11 (2012): 816-824.
2. Kalaria RN., “The pathology and pathophysiology of vascular dementia”. *Neuropharmacology* 134 (2018): 226-239.
3. De Reuck J., et al. “Topographic distribution of white matter changes and lacunar infarcts in neurodegenerative and vascular dementia syndromes: A post-mortem 7.0-tesla magnetic resonance imaging study”. *European Stroke Journal* 1 (2016): 121-129.
4. Scharf J., et al. “Significance of haemorrhagic lacunes on MRI in patients with hypertensive cerebrovascular disease and Intracerebral haemorrhage”. *Neuroradiology* 36.7 (1994): 50-508.
5. Gattringer T., et al. “No evidence for increased iron deposition in patients with ischemic white matter disease”. *Neurobiology of Aging* 45 (2016): 61-63.
6. Jellinger KA and Attems J. “Prevalence and pathology of vascular dementia in the oldest-old”. *Journal of Alzheimer’s Disease* 21.4 (2010): 1283-1293.
7. Jellinger KA., “The pathology of vascular dementia: a critical update”. *Journal of Alzheimer’s Disease* 14.1 (2008):107-123.
8. Jellinger KA., “Morphologic diagnosis of vascular dementia – a critical update”. *Journal of the Neurological Sciences* 270 (2008) :1-12.
9. De Reuck J., et al. “The impact of cerebral amyloid angiopathy on the occurrence of cerebrovascular lesions in demented patients with Alzheimer features: a neuropathological study”. *European Journal of Neurology* 18.6 (2011): 913-918.
10. Esiri MM., et al. “Neuropathological assessment of the lesions of significance in vascular dementia”. *Journal of Neurology, Neurosurgery, and Psychiatry* 63.6 (1997) :749-753.
11. De Reuck J., et al. “Cerebrovascular lesions in cerebral amyloid angiopathy with and without Alzheimer’s disease: A neuropathological study with post-mortem 7.0-tesla magnetic resonance imaging”. *EC Neurology* 10.11 (2018): 954-960.
12. Brenowitz WD., et al. “Cerebral amyloid angiopathy and its co-occurrence with Alzheimer’s disease and other cerebrovascular neuropathological changes”. *Neurobiology of Aging* 36.10 (2015): 2702-2708.
13. Kimberly WT., et al. “Silent ischemic infarcts are associated with hemorrhage burden in cerebral amyloid angiopathy”. *Neurology* 72.14 (2009): 1230-1235.
14. Braak H and Braak E. “Neuropathological staging of Alzheimer-related changes”. *Acta Neuropathologica* 82.4 (1991): 239-259.
15. McAleese KE., et al. “Post-mortem assessment in vascular dementia: advances and aspirations”. *BMC Medicine* 14.1 (2016): 129.
16. Love S., et al. “Development, appraisal, validation and implementation of a consensus protocol for assessment of cerebral amyloid angiopathy in post-mortem brain tissue”. *American Journal of Neurodegenerative Disease* 3.1 (2014): 19-32.

17. De Reuck J., et al. "Prevalence of small cerebral bleeds in patients with a neurodegenerative dementia: a neuropathological study". *Journal of the Neurological Sciences* 300 (2011): 63-66.
18. De Reuck J., et al. "Comparison of 7.0-T T2*-magnetic resonance imaging of cerebral bleeds in post-mortem brain sections of Alzheimer patients with their neuropathological correlates". *Cerebrovascular Diseases* 31 (2011): 511-517.
19. De Reuck J., et al. "Aging and cerebrovascular lesions in pure and in mixed neurodegenerative and vascular dementia brains: a neuropathological study". *Folia Neuropathol* 56.2 (2018): 81-87.
20. De Reuck J., "The impact of cerebral amyloid angiopathy in various neurodegenerative dementia syndromes: a neuropathological study". *Neurology Research International* (2019).
21. De Reuck J., et al. "Lobar intracerebral haematomas: Neuropathological and 7.0-tesla magnetic resonance imaging evaluation". *Journal of the Neurological Sciences* 369 (2016): 121-125.
22. Wermer MJH and Greenberg SM. "The growing clinical spectrum of cerebral amyloid angiopathy". *Current Opinion in Neurology* 31.1 (2018): 28-35.
23. Vidoni ED., et al. "Cerebral β -amyloid angiopathy is associated with earlier dementia onset in Alzheimer's disease". *Neurodegenerative Diseases* 16 (2016): 218-224.
24. Charidimou A., et al. "Emerging concepts in sporadic cerebral amyloid angiopathy". *Brain* 140.7 (2017): 1829-1850.
25. Fotiadis P., et al. "Cortical atrophy in patients with cerebral amyloid angiopathy: a case-control study". *The Lancet Neurology* 15.8 (2016): 811-819.
26. Smith EE., "Cerebral amyloid angiopathy as a cause of neurodegeneration". *Journal of Neurochemistry* 144.5 (2018): 651-658.
27. Halund M., et al. "Cerebral amyloid angiopathy and cortical microinfarcts as putative substrates of vascular dementia". *International Journal of Geriatric Psychiatry* 21.7 (2006): 681-687.
28. Brenowitz WD., et al. "Cerebral amyloid angiopathy and its co-occurrence with Alzheimer's disease and other cerebrovascular neuropathologic changes". *Neurobiology of Aging* 36.10 (2015): 2702-1708.
29. Haglund M and Englund E. "Cerebral amyloid angiopathy, white matter lesions and Alzheimer encephalopathy – a histopathological assessment". *Dementia and Geriatric Cognitive Disorders* 14.3 (2002): 161-166.
30. De Reuck J., et al. "Micro-bleeds in postmortem brains of patients with Alzheimer's disease: a T2*-weighted gradient-echo 7.0 T magnetic resonance imaging study". *Alzheimer Disease and Associated Disorders* 27.2 (2013): 162-165.
31. De Reuck J., et al. "The impact of cerebral amyloid angiopathy on the occurrence of cerebrovascular lesions in demented patients with Alzheimer features: a neuropathological study". *European Journal of Neurology* 18.6 (2011): 913-918
32. Janelidze S., et al. "CSF biomarkers of neuroinflammation and cerebrovascular dysfunction in early Alzheimer disease". *Neurology* 91.9 (2018): 867-877.

Volume 2 Issue 6 June 2019

© All rights are reserved by Jacques De Reuck, et al.