



## Coexistence of Genital Tuberculosis and Ovarian Serous Cystadenofibroma in a Young Female Patient of Disseminated Tuberculosis

Jyoti Saikia<sup>1</sup>, Rakesh Holla<sup>2\*</sup>, Ritu Mehta<sup>1</sup>, Arijit Sen<sup>1</sup> and Barun Chakrabarty<sup>1</sup>

<sup>1</sup>Department of Pathology, Armed Forces Medical College, Pune, India

<sup>2</sup>Department of Pathology, Command Hospital (Southern Command), Pune, India

\*Corresponding Author: Rakesh Holla, Department of Pathology, Command Hospital (Southern Command), Pune, India.

DOI: 10.31080/ASMS.2022.06.1366

Received: July 28, 2022

Published: August 23, 2022

© All rights are reserved by Rakesh Holla, et al.

### Abstract

The coexistence of genital TB and ovarian serous cystadenofibroma is rare and presents a greater diagnostic challenge. We present a case of a 30-year-old woman with complaints of lower abdominal pain since past one year with a left tubo-ovarian mass lesion detected by B-ultrasound. The patient was an old case Right sided pleural effusion and was on ATT for six months. In view of the raised tumor markers and left side tubo-ovarian mass, staging Laparoscopic surgery was performed to rule out malignancy and tissues were sent for histopathological examination. The histopathological finding from left ovarian cyst wall showed cystic tissue lined by benign ciliated columnar epithelium showing focal pseudostratification. Epithelioid cell granulomas were noted in cyst wall.

**Keywords:** Tuberculosis; Ovary; Tumor

### Introduction

Ovary is an important organ as it is concerned with the production of progeny. The ovary consists of sex cells and mesenchymal cells which are totipotent and multipotent respectively. Ovarian tumor and non-neoplastic lesions present a great challenge to gynecological oncologist. Certain non-neoplastic lesions of the ovary frequently form a pelvic mass and potentially mimic an ovarian neoplasm.

On the other hand, Female Genital Tuberculosis (TB) causes significant morbidity. Mycobacterium tuberculosis is the etiological agent for tuberculosis. The ovaries are involved in 20-30% cases of genital TB. The diagnosis is made by detection of acid-fast bacilli on microscopy or culture on endometrial biopsy or on histopathological detection of epithelioid granuloma on biopsy. Polymerase chain reaction alone is not sufficient to make the diagnosis. Laparoscopy and hysteroscopy can also diagnose genital tuberculosis by characteristic findings. Histopathology is an essential tool for definitive diagnosis.

The coexistence of genital TB and ovarian serous cystadenofibroma is rare and presents a greater diagnostic challenge. We hereby present a case of a 30 year old female, a case of Right sided pleural effusion (completed ATT) with synchronous occurrence of ovarian TB and ovarian serous cystadenoma in which histopathological study proved the mass to be a benign ovarian neoplasm in the presence of concurrent tuberculosis.

### Case Report

A 30-year-old woman, a para 2, living 2 (both full term normal delivery), presented to a tertiary care hospital in Maharashtra with complaint of pain abdomen in left lower quadrant since last one year. She is a known case of Right sided pleural effusion and completed anti-tubercular therapy with Isoniazide 300 mg, Rifampicin 450 mg, Pyrazinamide 1200 mg, Ethambutol 800 mg daily for six months in Oct 2021.

On physical examination, per abdomen examination was normal, per vaginal examination showed normal cervix, uterus

of normal size, anteverted. The patient had no family history of gynaecological malignancy or TB.

USG examination revealed left tubo-ovarian mass measuring 8.3x10.3x9.9 cm. MRI revealed solid cystic lesion arising from right ovary. Tumor markers namely serum carbohydrate antigen (CA)-125 and HE-4 levels were slightly increased with values of 257.4 U/mL and 77.7 U/mL (normal values: 35 U/mL and 35 U/mL), respectively.

On 08 Apr 2022, the patient underwent laparoscopic exploration for suspicion of malignancy in view of raised tumor markers. Bilateral tubo-ovarian mass, left side omentum and cystic wall from left ovary were biopsied and an intraoperative frozen pathology examination was performed. Histopathological examination from bilateral tubo-ovarian mass revealed multiple well-formed granulomas comprising of epithelioid cells, Langhans type giant cells, lymphocytes and fibroblasts with areas of caseous necrosis. No atypia/malignancy seen.

The histopathological finding from left ovarian cyst wall showed cystic tissue lined by benign ciliated columnar epithelium showing focal pseudostratification. Epithelioid cell granulomas were noted in cyst wall. No cytological atypia/stromal invasion noted.

**Discussion and Conclusion**

We present a case of a 30-year-old woman with complaints of lower abdominal pain since past one year with a left tubo-ovarian mass lesion detected by B-ultrasound. The patient was an old case Right sided pleural effusion and was on ATT for six months till Oct 2021. In view of raised tumor markers and left side tubo-ovarian mass, staging Laparoscopic surgery was performed to rule out malignancy and tissues were sent for histopathological examination. The histopathological diagnosis was necrotizing granulomatous inflammation of bilateral tubo-ovarian mass with left ovarian serous cystadenoma.

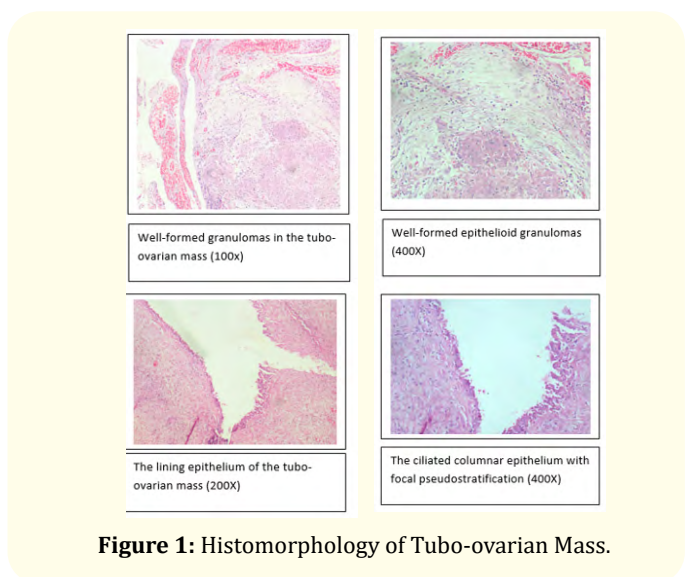
Genital TB in women is a chronic disease with systemic non-specific symptoms such as loss of weight and appetite, night sweats, low grade fever and up to 11% of women with genital TB are asymptomatic <sup>1</sup>. The main complication of genital TB is the risk of infertility due to frequent involvement of endometrium and fallopian tube [1]. Timely detection and treatment of female genital TB are important. The coexistence of genital TB and Ovarian

cystadenofibroma is rare and very often missed by the treating surgeons/physicians [2].

Our patient was a known case of right sided pleural effusion and she completed six months ATT in Oct 2021. She had chronic on and off abdominal pain since last one year with severe dull aching pain occasionally. Her menstrual history was normal and obstetric history was Para2 Living2 with both being Full Term Normal Vaginal Delivery.

Epidemiological studies have shown that genital TB in the female reproductive system is mainly transmitted through hematogenous spread and local dissemination which is more common in young women in developing countries. The diagnosis of Genital TB with Ovarian Serous cystadenofibroma was made by the histopathological findings in the tubo-ovarian mass and CECT pelvis also revealed bilateral complex adnexal mass effect and inflammatory changes likely to be tubercular etiology.

Ovarian epithelial neoplasm account for nearly 60% of all the ovarian tumors and ovarian serous cystadenofibromas are an uncommon benign neoplasm. Without histopathological examination, making a diagnosis of ovarian serous cystadenofibromas through imaging alone is difficult especially when there are other comorbidities. The results of immunohistochemistry showed that the ovarian serous cystadenoma in our patient was benign. The findings in our case suggest that genital TB needs to be considered for young women with a tubo-ovarian mass [3].



**Figure 1:** Histomorphology of Tubo-ovarian Mass.

## Bibliography

1. Grace GA., *et al.* "Genital tuberculosis in females". *Indian Journal of Medical Research* 145.4 (2017): 425-436.
2. Yang S., *et al.* "Coexistence of genital tuberculosis and ovarian serous cystadenofibroma in a young female patient: a case report". *Journal of International Medical Research* 48.10 (2020): 0300060520949410.
3. Limaiem F and Mlika M. "Ovararian cystadenoma". [Updated 2019 Feb 2]. In: StatPearls [Internet]. Treasure Island (FL): StatPearls Publishing, (2018).