



## Vasospastic Angina in a Patient with Induced Metabolic Disorders: A Case Report

PS Popov<sup>1</sup>, AS Zhuravleva<sup>1</sup>, IA Kurnikova<sup>1\*</sup>, TV Nikishova<sup>2</sup> and TS Polikarpova<sup>1</sup>

<sup>1</sup>RUDN University, Moscow, Russia

<sup>2</sup>Federal State Budgetary Educational Institution of Further Professional Education "Russian Medical Academy of Continuing Professional Education", Kazan, Russia

\*Corresponding Author: IA Kurnikova, RUDN University, Moscow, Russia.

**Received:** February 13, 2021

**Published:** April 27, 2021

© All rights are reserved by IA Kurnikova, et al.

### Abstract

**Background:** Currently, cases of disorders associated with patients' activities or the use of supplements and drugs are rarely reported. We observed a patient, a former professional bodybuilder. This sport is well known for use of some groups of pharmaceuticals with an ambiguous cardiovascular effect.

**Objective:** To assess the relationship between the patient's professional activity and cardiovascular disease.

**Discussion:** When analyzing the data of the presented patient admitted to the specialized Department of Cardiology with acute coronary syndrome, the association was revealed between cardiovascular dysfunction, lipid metabolism and previous self-medication of drugs that can lead to coronary artery spasm and potentially increase the risk of sudden cardiac death.

**Keywords:** Vasospastic Angina; Acute Coronary Syndrome; Unstable Angina; Athlete's Heart; Bodybuilding

### Background

As a rule, physicians specializing in sports medicine are involved in the health monitoring of professional athletes. However, often athletes become patients of other medical specialists, especially in such sports, which can be easily practiced by both professionals and amateurs, or during the transition of a person from intensive sports to a normal lifestyle.

In modern society, bodybuilding has become widespread. This sport is attractive not only to people focused on professional achievements, but also to amateurs with the goal of shaping a beautiful and healthy body.

Despite the fact that the use of medicines in bodybuilding is far from being approved in all countries (in Russia, for example, some drugs available in other countries are prohibited), this issue usually remains the choice of the athletes themselves. The effects of their use and its consequences, as a rule, are of interest only to a narrow circle of specialists and the medical field itself is rather restricted due to the peculiarities of this sport. However, when health problems occur, these patients turn to a general practitioner who should be well informed of the medicines used in bodybuilding, their mechanism of action and the consequences of their use.

The main groups of pharmaceuticals used in this sport are well known. Quite often in the fitness industry, methods of sports phar-

macology are used [1]. Anabolic steroids are at the top of the list of drugs used to increase muscle volume and muscle strength [2]. Bodybuilders combine them with testosterone, which is necessary to prevent androgen deficiency while suppressing the production of gonadotropin-releasing hormone (GnRH) [3,4]. The latest generation of drugs with anabolic effects include selective androgen receptor modulators (SARMs) [5].

In sports, other drug groups are also actively used: analogues of growth hormone; growth hormone secretagogues (ibutamoren, GHRP-2, GHRP-6, CJC-1295, Hexarelin, Ipamorelin, Sermorelin); growth hormone fragments (HGH 176-191); and analogues of the type 1 insulinlike growth factor (IGF-1) [6]. The main advantage of the latter is a significant lipolytic effect.

However, in addition to the effect on skeletal muscles, all these drug groups have a specific effect on cardiomyocytes, as well as on the cardiovascular system as a whole. Stimulation of androgen receptors by medicinal agents affects lipid metabolism, vascular tone, systemic inflammation, platelet aggregation, erythropoiesis (through stimulation of erythropoietin secretion), electrophysiology of cardiomyocytes, water-salt balance in the body, and increases the risk of atherosclerosis [7].

According to the published studies of the effect of androgen receptor stimulation on the cardiovascular function, it seems that scientists have not yet come to agreement. In the 2019 scientific review, we found approximately the same number of randomized clinical trials (RCTs), which indicated that testosterone worsens the cardiovascular prognosis [7], and those, which pointed that testosterone, on the contrary, improves the prognosis or has a neutral effect [8].

There has not yet been a single point of view in assessing the risks of atherosclerosis and thrombosis associated with the use of these drugs, the differential diagnosis of dyslipidemia associated with the genetics and lifestyle of a particular bodybuilder and “iatrogenic” dyslipidemia with the use of anabolic steroids or selective androgen receptor modulators [8].

Among very important and unresolved problems remains cardiomegaly, in which the combination of drugs stimulating the androgen receptor and growth hormone receptor is the most serious. The combination of medicines in sports pharmacology (testosterone, anabolic steroids and growth hormone) leads to the emergence of additional risk factors for cardiovascular disease due to systemic inflammation, dyslipidemia, increased hematocrit, as well as cardiac hypertrophy. However, there are currently no major studies and endpoints in risk assessment in such patients.

We would like to share our personal experience and present a clinical observation on acute coronary syndrome in a bodybuilder who abruptly stopped active sports training.

The study objective was to assess the relationship between the patient’s professional activity and cardiovascular disease.

Ethical principals were followed: we obtained the patient’s informed consent to use the data of his medical history.

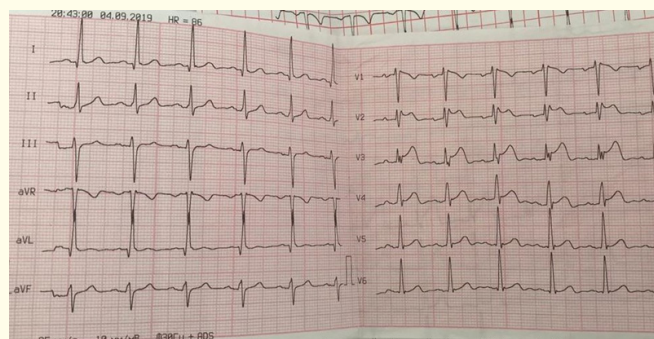
### Clinical Case

Patient Ye., 47 years old, manager, unemployed at the time of admission. On April 2, 2019, he was urgently admitted to the emergency room of the City Clinical Hospital named after SS Yudin of the Moscow City Health Department (Russia) with complaints of pain behind the sternum of a pressing nature, and a feeling of “fear of death”.

According to the history, the patient was actively engaged in professional bodybuilding for 10 years. After quitting a year ago, his body weight increased from 91 kg to 100 kg. There were episodes of increased blood pressure to 200/110 mm Hg with a frequency of once a month. Previously, hypertension was never treated and diagnosed. The patient sought medical attention from a general practitioner at the clinic at the place of residence repeatedly. Beta-blockers were prescribed, but the patient took them irregularly.

On the day of hospitalization in the evening for the first time he noticed chest pain of a pressing nature, intense, lasting more than

20 minutes, and radiating into the left arm. The patient denied the connection of pain with increased physical activity. The ambulance team that arrived at the call recorded an ST-segment elevation in II, III, avF and V2-V6 leads on the electrocardiogram (Figure 1) and transported the patient to the hospital in the intensive care unit with a provisional diagnosis of acute myocardial infarction:



**Figure 1:** The electrocardiogram of a patient with hypertension and acute coronary syndrome with 3-hour episode of pain (ST elevation in II, III, avF and V2-V6 leads, left axis deviation).

- **Prehospital treatment:** Acetylsalicylic acid 250 mg, clopidogrel 600 mg, nitrate spray 2 doses. The pain was managed by sublingual administration of nitrates.
- **Past medical history:** Fifteen years ago, peptic ulcer of the duodenum was detected without relapse after treatment, and a year before laser vision correction was performed for moderate myopia.

No bad habits.

During bodybuilding, the patient took protein mixtures and amino acid complexes to increase muscle mass.

The family history is burdened: His father had myocardial infarction at the age of 53.

During examination in the intensive care unit: The condition is serious. The state of consciousness is normal. The position is pas-

sive. Body temperature is 36.8°C. The skin is pale, cool, moist, cyanosis is absent, peripheral edema is absent. Height is 184 cm. Body mass index is 30.9 kg/m<sup>2</sup>.

In the lungs, breathing is bronchial, heard symmetrically throughout the lung fields, moderately weakened in the lower parts due to excessively developed subcutaneous fat, rales are not heard. Respiratory rate is 17 bpm.

The area of the heart is without abnormalities. The borders of the heart are extended to the left by one cm. Heart sounds are muffled, rhythmic. Emphasis of the 2<sup>nd</sup> tone on the aorta is auscultated. Systolic murmur is heard at the apex of the heart. Pulse on peripheral arteries is of satisfactory filling. BP = 170/100 mm Hg, HR = 90 bpm.

The tongue is pale, moist, without plaque. The abdomen is symmetrical, not swollen, soft, nontender on palpation. The size of the liver vertically from right to left is 12-9-8 cm, the edge of the liver is soft, painless on palpation. The spleen is not palpable. Peristaltic noises are of normal sonority. With percussion of the abdomen - tympanic sound. The stool is regular. Urination is normal.

Oxygen saturation measured with pulse oximeter was 98%.

**Complete blood count**

RBC: 5.06 × 10<sup>12</sup>/L, hemoglobin: 143-157 g/L, WBC: 6.0 × 10<sup>9</sup>/L, leukocyte formula within the norm, platelets: 165 - 180 × 10<sup>9</sup>/L.

The diagnosis was: Acute coronary syndrome with ST-segment elevation.

Additional examination and continuous monitoring was provided in the intensive care unit with subsequent transfer to a specialized Department of Cardiology.

**Biochemical assay**

The activity of transaminases is slightly higher than the average at this age (ALT 40 U/L, AST 42 U/L), an increase in CPK to

678-781 U was observed on the first day of hospitalization, with a normal activity of CPK-MB = 14 U. On the second day of hospitalization, CPK-MB increased to 40 U, which was also not a significant marker of acute myocardial infarction. The troponin levels assayed every 6 - 12 hours were within normal values of less than 0.02 ng/mL. The serum creatinine level was 100  $\mu$ mol/L. An insignificant (characteristic for stage 2 chronic kidney disease) decrease in glomerular filtration rate to 77 mL/min/1.73 m<sup>2</sup> was counted via the CK-EPI formula, which was regarded as a result of hypertension. Urea was 5.0 mmol/L. There was also a minimal increase in serum total cholesterol to 5.4 mmol/L, triglycerides to 2.34 nmol/L and an increase in glucose to 5.9 mmol/L. Electrolyte abnormalities were not detected. ABG test was within the norm, as well as the acid-base status. Urinalysis: Proteinuria up to 0.150 g /L, a small amount of ketones.

### Coagulation test

The prothrombin index, prothrombin time and INR were within normal values, heparin-induced target elongation of the activated partial thromboplastin time to 55.6 seconds was revealed. The risk of thromboembolic complications was low with the **Padua** Prediction Score of one. Pulmonary embolism was extremely unlikely.

On X-Ray exam no abnormality was detected, cardiac shadow and aorta without features, pulmonary pattern was not changed.

According to the recommendations, a patient with risk factors for coronary artery disease (male, metabolic syndrome, burdened hereditary history), angina typical for acute coronary syndrome, ECG-changes specific for myocardial infarction, and increased CPK requires coronary angiography. According to coronary angiography, no abnormalities in the coronary arteries were detected, and the codominant type of coronary circulation was recorded.

The patient underwent echocardiography, there were no signs of impaired local left ventricular myocardial contractility, the cardiac chambers were not enlarged, attention was drawn to the thickening of the interventricular septum to 1.1 cm, and slight mitral regurgitation of the 1<sup>st</sup> degree was determined. A satisfactory left ventricular ejection fraction of 61% was maintained.

Since acute coronary syndrome can be not only a manifestation of destabilization of the chronic course of coronary artery disease, but also the first sign of coronary artery disease in patients without previous complaints, the absence of increased troponin, the absence of hypokinesia zones during echocardiography and the absence of atherosclerotic stenosis of coronary arteries allowed to exclude myocardial infarction.

### The principal diagnosis

Coronary Artery Disease. Unstable vasospastic angina.

The appropriate treatment was conducted.

On the dual antiplatelet therapy (acetylsalicylic acid + ticagrelol) combined with gastroprotection and antihypertensive therapy, a satisfactory clinical effect was obtained: the pain syndrome did not recur, target BP values were achieved, during repeated electrocardiographic studies the ST-segment deviation was not recorded. With the diagnosis of unstable vasospastic angina the patient was transferred to the Department of Cardiology for additional examination and consecutive treatment.

### Discussion

At the initial stage of the patient examination, experts suggested a connection between the professional activities (bodybuilding) of the patient, a sharp change in the type of activity and impaired functioning of the cardiovascular system. A year ago, after quitting active sports, the patient had hypertension, and exercise-induced left ventricular hypertrophy immediately led to the resistance to treatment. A patient with a long history of static loads on the cardiac muscle, who does not deny the long-term use of pharmaceuticals stimulating protein synthesis, undoubtedly, to one degree or another, already had morphological (interventricular septal hypertrophy, codominant coronary circulation) and electrophysiological myocardial remodeling.

Dyslipidemia and a high level of triglycerides in a patient committed to a healthy lifestyle, following a diet can also be due to his professional activity, especially since he is middle-aged and, de-

spite the heredity of CAD is burdened, his father had a myocardial infarction at a later age. The effect of anabolic steroids can also not be excluded, since their use is associated with the development of dyslipidemia due to an increase in hepatic lipase activity (increased total cholesterol, LDL, VLDL, TG and decreased HDL), increased hematocrit, which, in turn, increases the likelihood of platelet aggregation [9-12].

In this patient, the risk of thromboembolic complications was regarded as low, but heparin-induced prolongation of activated partial thromboplastin time was noted. When coagulogram was studied in users of anabolic steroids (AS), an abnormally high level of plasma thrombin-antithrombin complexes, as well as high concentrations of prothrombin fragment 1, antithrombin II and protein S were often found [13]. In addition, a low concentration of tissue plasminogen activator and its inhibitor was observed in plasma.

Clinical studies in bodybuilders show that chronic use of anabolic steroids negatively affects vascular reactivity regardless of smooth muscle hypertrophy and wall stiffness [14]. Anabolic steroids reduce the production of cyclic guanosine monophosphate (cGMP) by inhibiting guanylyltransferase, which potentially inhibits the ability of nitric oxide to affect myocytes in the coronary arteries, which leads to spasm and potentially increases the risk of sudden cardiac death [15].

Therefore, a preliminary diagnosis of acute coronary syndrome with ST-segment elevation (myocardial infarction?) was justified. In our opinion, the ST-segment elevation could be associated with the early repolarization syndrome, pathognomonic for the "athlete's heart". Currently experts pay attention not only to the transcriptional, but also to the non-genomic effects of anabolic steroids and testosterone, which are characterized by an extremely high rate of development (increase in intracellular calcium concentration through activation of the membrane GPRC6A receptor; activation of protein kinase A and C with the start of the MAPK cascade, nitric oxide synthesis, and stimulation of apoptosis through the membrane protein ZIP9) [16,17].

Interestingly, on treatment these ECG-changes resolved. In addition, it was taken into account that the patient had risk factors for coronary artery disease and did not work out in the gym for a year.

In the medical history, specific attention was paid to blood pressure elevation. This is indeed a challenge of AS-induced hypertension and this case confirms the hypothesis of the development of hypertension with the use of anabolic steroids, although there is no single point of view on the effect of high doses of steroids on systolic or diastolic blood pressure [18-21].

An increase in the level of 11-deoxycorticosterone, the precursor of aldosterone, is believed to be significant in pathogenesis [22]. Androgens can enhance renin secretion by the kidneys [23] and increase plasma aldosterone levels [24].

## Conclusion

In a patient with clear signs of acute coronary syndrome, but without stenosis according to the intracoronary intervention, the onset of pain behind the sternum, accompanied by short-term ST-segment elevation, as well as an insignificant increase in cardiac enzymes, was regarded as vasospastic angina.

In addition, the use of drugs that stimulate protein metabolism and the sudden termination of training in bodybuilders should be attributed to risk factors for acute coronary syndrome in this group of patients.

## Authors' Contributions

- Pavel Popov is the main author of the manuscript, analyzed and interpreted the patients.
- Anastasia Zhuravleva - Treatment and examination of the patient.
- Irina Kurnikova contributed to the preparation of the manuscript, participated in the collection of material and interpretation of this patient.
- Tatiana Nikishova - Discussion and interpretation of this patient.
- Tatiana Polikarpova - Treatment and examination of the patient.

All authors have read and approved the final manuscript.

## Conflict of Interests

The authors declare no conflicts of interest.

### Acknowledgments

The Ministry of Education and Science of the Russian Federation on the program to improve the competitiveness of Peoples' Friendship University of Russia (RUDN University) among the leading research and education centers in the 2016-2020 financially supported this paper.

### Bibliography

1. Rabih El Osta., et al. "Anabolic steroids abuse and male infertility". *Basic and Clinical Andrology* 26 (2016): 2.
2. Woerdeman J and de Ronde W. "Therapeutic effects of anabolic androgenic steroids on chronic diseases associated with muscle wasting". *Expert Opinion on Investigational Drugs* 20.1 (2011): 87-97.
3. Page ST., et al. "Exogenous testosterone (T) alone or with finasteride increases physical performance, grip strength, and lean body mass in older men with low serum T". *Journal of Clinical Endocrinology and Metabolism* 90 (2005): 1502-1510.
4. Bhasin S., et al. "Older men are as responsive as young men to the anabolic effects of graded doses of testosterone on the skeletal muscle". *Journal of Clinical Endocrinology and Metabolism* 90 (2005): 678-688.
5. Mario Thevis and Wilhelm Schanzer. "Detection of SARMs in doping control analysis". *Molecular and Cellular Endocrinology* 30 (2017): 1-12.
6. David M Siebert., et al. "The Use and Abuse of Human Growth Hormone in Sports". *Sports Health* 10.5 (2018): 419-426.
7. Thiago Gagliano-Jucá and Shehzad Basaria. "Testosterone replacement therapy and cardiovascular risk". *Nature Reviews Cardiology* 16.9 (2019): 555-574.
8. Shehzad Basaria., et al. "The Safety, Pharmacokinetics, and Effects of LGD-4033, a Novel Nonsteroidal Oral, Selective Androgen Receptor Modulator, in Healthy Young Men". *The Journals of Gerontology Series A Biological Sciences and Medical Sciences* 68.1 (2013): 87-95.
9. Chang S., et al. "Anabolic Androgenic Steroid Abuse: The Effects on Thrombosis Risk, Coagulation, and Fibrinolysis". *Seminars in Thrombosis and Hemostasis* 44.8 (2018): 734-746.
10. Mottram DR and George AJ. "Anabolic steroids". *Best Practice and Research Clinical Endocrinology and Metabolism* 14.1 (2000): 55-69.
11. Webb OL., et al. "Severe depression of high density lipoprotein cholesterol levels in weight lifters and body builders by self-administered exogenous testosterone and anabolic-androgenic steroids". *Metabolism* 33 (1984): 971-975.
12. Parssinen M and Seppala T. "Steroid use and long-term health risks in former athletes". *Sports Medicine* 32 (2002): 83-94.
13. Ferenchick GS., et al. "Anabolic-androgenic steroid abuse in weight lifters: vidence for activation of the hemostatic system". *American Journals of Hematology* 49 (1995): 282-288.
14. Lane HA., et al. "Impaired vasoreactivity in bodybuilders using androgenic anabolic steroids". *European Journal of Clinical Investigation* 36 (2006): 483-488.
15. Melchert RB and Welder AA. "Cardiovascular effects of androgenic-anabolic steroids". *Medicine and Science in Sports and Exercise* 27 (1995): 1252-1262.
16. Lucas-Herald AK., et al. "Genomic and non-genomic effects of androgens in the cardiovascular system: clinical implications". *Clinical Science (Lond)* 131.13 (2017): 1405-1418.
17. Foradori CD., et al. "Non-genomic actions of androgens". *Frontiers in Neuroendocrinology* 29.2 (2008): 169-181.
18. Riebe D., et al. "The blood pressure response to exercise in anabolic steroid users". *Medicine and Science in Sports and Exercise* 24.6 (1992): 633-637.
19. Grace F., et al. "Blood pressure and rate pressure product response in males using high-dose anabolic androgenic steroids (AAS)". *Journal of Science and Medicine in Sport* 6 (2003): 307-312.

20. Sader MA, *et al.* "Androgenic anabolic steroids and arterial structure and function in male bodybuilders". *Journal of the American College of Cardiology* 37 (2001): 224-230.
21. Lane HA, *et al.* "Impaired vasoreactivity in bodybuilders using androgenic anabolic steroids". *European Journal of Clinical Investigation* 36 (2006): 483-488.
22. Rockhold RW. "Cardiovascular toxicity of anabolic steroids". *Annual Review of Pharmacology and Toxicology* 33 (1993): 497-520.
23. Kuipers H, *et al.* "Influence of anabolic steroids on body composition, blood pressure, lipid profile and liver functions in body builders". *International Journal of Sports Medicine* 12 (1991): 413-418.
24. Christowski K, *et al.* "Medical consequences of anabolic steroid abuse". *Biology of Sport* 17.2 (2000): 134-152.

#### Assets from publication with us

- Prompt Acknowledgement after receiving the article
- Thorough Double blinded peer review
- Rapid Publication
- Issue of Publication Certificate
- High visibility of your Published work

**Website:** [www.actascientific.com/](http://www.actascientific.com/)

**Submit Article:** [www.actascientific.com/submission.php](http://www.actascientific.com/submission.php)

**Email us:** [editor@actascientific.com](mailto:editor@actascientific.com)

**Contact us:** +91 9182824667