



## Pattern of Ocular Toxicity in Patients on Antipsychotic Drug Therapy at Alexandria Main University Hospital

Wafaa Mohamed El Sehly<sup>1\*</sup>, Rania Abd Elmeguid Ahmed<sup>2</sup>, Jiddaa Farouk Mekky<sup>3</sup>, Karim Mahmoud Nabil<sup>4</sup> and Magda Hassan<sup>5</sup>

<sup>1</sup>Professor of Forensic Medicine and Clinical Toxicology, Faculty of Medicine University of Alexandria, Egypt

<sup>2</sup>Lecturer in Forensic Medicine and Clinical Toxicology, Faculty of Medicine University of Alexandria, Egypt

<sup>3</sup>Lecturer in Neuropsychiatry, Faculty of Medicine University of Alexandria, Egypt

<sup>4</sup>Lecturer in Ophthalmology, Faculty of Medicine University of Alexandria, Egypt

<sup>5</sup>Assistant Lecturer of Forensic Medicine and Clinical Toxicology, Faculty of Medicine University of Alexandria, Egypt

\*Corresponding Author: Wafaa Mohamed El Sehly, Professor of Forensic Medicine and Clinical Toxicology, Faculty of Medicine University of Alexandria, Egypt.

Received: December 27, 2019

Published: March 17, 2020

© All rights are reserved by Wafaa Mohamed El Sehly., et al.

### Abstract

Psychotic disorders are severe mental disorders that cause abnormal thinking and perceptions. People with psychoses lose touch with reality. Two of the main symptoms are delusions and hallucinations. Antipsychotic drug treatment is a key component of schizophrenia treatment. First-generation antipsychotics, known as typical antipsychotics, neuroleptics or major tranquilizers. Most second-generation drugs, known as atypical antipsychotics, have been developed more recently. All psychotropic medications have the potential to induce numerous and diverse unwanted ocular effects. Psychiatrists, ophthalmologists and patients need to be aware of and prepared for any medication-induced toxic effect. Early prevention and intervention can avoid most of the serious and potentially irreversible ocular toxicities.

The aims of the present study were to assess the occurrence of toxic ocular effects of antipsychotic drugs, evaluate intraocular pressure of chronic psychotic patients treated with psychiatric medications, Correlate toxic ocular effects in patients treated with a variety of antipsychotics to duration of treatment and detect early toxic ocular effects for early intervention. Informed consent will be taken from patients. The present study was conducted on 100 chronic psychotic patients attending the Alexandria main university hospital who on treatment of antipsychotic drugs for a period more than six months period with age group between 18 - 60 years. 14% of those patients were on typical therapy alone, 16% on atypical antipsychotic alone while 70% were on combined therapy. 2% of all cases had pigmentation of conjunctiva all were on typical therapy. Corneal opacity was manifested on 4% of all cases. All of them was on typical therapy. As regard lens opacity, 7% was suffered from lens opacity, six cases due to typical therapy while one cases due to atypical therapy. Intraocular pressure was manifested in 11% of all cases. Optic examination revealed two cases had increased cup disc ratio who on typical therapy alone. So, it was concluded that ocular toxicity was manifested mainly with typical therapy that affected by duration of treatment. The incidence of toxicity decreased with atypical or combination of typical and atypical.

**Keywords:** Pattern of Ocular; Toxicity in Patients; Antipsychotic; Therapy at Alexandria

## Introduction

Antipsychotic drug treatment is a key component of schizophrenia treatment [1].

The main effect of treatment with antipsychotics is to reduce positive symptoms, including delusions and hallucinations. There is mixed evidence to support a significant impact of antipsychotic use on negative symptoms or on the cognitive symptoms of schizophrenia [2,3]. First-generation antipsychotics, known as typical antipsychotics, neuroleptics or major tranquilizers, were discovered in the 1950s. Most second-generation drugs, known as atypical antipsychotics, have been developed more recently, although the first atypical antipsychotic, clozapine, was discovered in the 1960s and introduced clinically in the 1970s. Both generations of medication tend to block receptors in the brain's dopamine pathways, but atypical tend to act on serotonin receptors as well [4]. Antipsychotics toxicity have multisystem manifestation [5].

All psychotropic medications have the potential to induce ocular toxic effects. Psychiatrists, ophthalmologists and patients need to be aware of and prepared for any medication-induced toxic manifestations. Ocular toxic effects due to antipsychotics can be divided into seven categories: eyelid and keratoconjunctival disorders; uveal tract disorders; accommodation interference; angle-closure glaucoma; cataract/pigmentary deposits in the lens and cornea; retinopathy; and other disorders [6,7]. Patient with psychiatric condition may not complain of visual symptoms. Ocular screening could be considered in these patients receiving chronic antipsychotic treatment. This toxicity is related to duration and dose of the drug [8]. Early prevention and intervention can avoid most of the serious and potentially irreversible ocular toxicity [9].

The aims of the present study were to assess the possibility of occurrence of ocular toxic effects of antipsychotic drugs as well as evaluation of intraocular pressure of chronic psychotic patients treated with antipsychotic medications. It was important also to relate ocular toxic effects in patients treated with a variety of antipsychotics to duration of treatment and detect early ocular toxic effects for early intervention.

## Patients

The study will be conducted on 100 chronic adult psychotic patients attending EL - HADRA University Hospital treated with antipsychotic drugs for a period more than six months. Patients with any chronic disease known to cause ocular complication were excluded.

## Methods

A clinical study included ocular examination of patients on antipsychotic medication. An informed consent was taken from each patient. The study was approved from the ethical committee of Faculty of Medicine, Alexandria University. History taking of age, sex, type and duration of drug intake were recorded with full ophthalmic and systemic history were taken from the included. Ophthalmological examinations: [9]

1. Uncorrected and best spectacle corrected visual acuity (BSCV) measurement. Distance BCVA for each eye was measured by a trained examiner using the tumbling E's chart.
2. Anterior segment examination by BQ 900 slit lamp (Haag-Streit AG).
3. Measurement of intraocular pressure (IOP) by Goldmann applanation tonometer (GAT). Tonometry measurements were performed by GAT using a sodium fluorescein solution. The same tonometer (Haag-Streit AG) was used throughout the study. Tonometry measurements were taken at the center of the cornea; the median of three consecutive measurements was used for analysis.
4. Dilated fundus examination using slit lamp bio microscopy and a non-contact fundus lens.

## Results

In the present study, the demographic data showed that most of the cases (51%) were employed while 45% of them were unemployed. Students and housewives were the least percentage among those cases as shown in (Table1). More than half of the cases (54%) were smokers while 46% of them were nonsmokers.

The duration of treatment in the present study ranged from 9 months to more than 25 years with a mean of  $10.45 \pm 8.66$  years. The majority of cases (35%) received treatment from 5 to less than 10 years while minority (6%) received treatment from 20 to less than 25 years (Table 2).

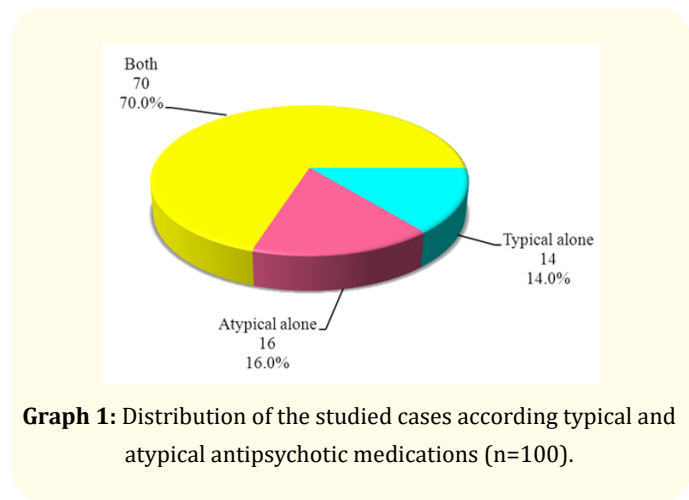
As regard type of the drug received in this study, more than two thirds of the cases (70%) were treated by both typical and atypical antipsychotic drugs, 16% of them received only atypical antipsychotics and the least percentage was on typical antipsychotics (14%) (Graph 1).

	No.
<b>Age (years)</b>	
20 – 30	25
31 – 40	43
41 – 50	22
51 – 60	10
Min. – Max.	20.0 – 60.0
Mean ± SD.	37.16 ± 9.12
Median	35.0
<b>Marital Status</b>	
Single	60
Married	28
Divorced	12
<b>Educational level</b>	
Illiterate	22
Read and Write	30
Middle education	36
Higher education	12
<b>Employment</b>	
Student	2
Unemployed	45
Employed	51
Housewife	2

**Table 1:** Distribution of the studied cases according to demographic data (n=100).

Duration of Treatment Years)	No.	%
<5	24	24
5 - <10	35	35
10 - <15	14	14
15 - <20	11	11
20 - <25	6	6
25+	10	10
Min. – Max.	0.75 – 38.0	
Mean ± SD.	10.45 ± 8.66	
Median	7.0	

**Table 2:** Distribution of the studied cases according to duration of treatment with antipsychotics (n=100).



**Graph 1:** Distribution of the studied cases according typical and atypical antipsychotic medications (n=100).

**Relation between the type of the used antipsychotic drug and the visual acuity**

There was non-significant relation between visual acuity and the type of antipsychotic drug used for both eyes (p = 0.841 and 0.617 for right and left eyes respectively).

Table 3 showing that intraocular pressure in studied cases ranged from 8.0 - 24 with a mean of 13.84 ± 3.89 in the right eye while intraocular pressure in left one ranged from 8.0 - 24 with a mean of 13.85 ± 4.04.

Eleven cases (11%) show increased intraocular pressure (more than 21 mmHg) seven cases of them treated with combination therapy and four cases of them on typical only but no cases of elevated intraocular pressure among cases treated with atypical antipsychotics alone.

I.O.P	Right	Left
Min. – Max.	8.0 – 24.0	8.0 – 24.0
Mean ± SD.	13.84 ± 3.89	13.85 ± 4.04
Median	12.0	12.0

**Table 3:** Distribution of the studied cases according to I.O.P (n=100).

Table 4 showing that there was a significant difference between three categories of drugs (typical alone, atypical alone and both) as regarding intraocular pressure, it was highest in those using typical antipsychotics alone followed by both typical and atypical then atypical antipsychotics alone in both eyes with p value(0.015 -0.033) for right and left eye respectively.

I.O.P	Drugs			H	p
	Typical (n= 14)	Atypical (n= 16)	Both (n= 70)		
<b>Right</b>					
Min. - Max.	12.0 - 24.0	10.0 - 16.0	8.0 - 24.0	8.353*	0.015*
Mean ± SD.	16.14 ± 5.27	12.0 ± 1.26	13.80 ± 3.77		
Median	13.0	12.0	12.0		
<b>Left</b>					
Min. - Max.	12.0 - 24.0	8.0 - 14.0	8.0 - 24.0	6.803*	0.033*
Mean ± SD.	16.14 ± 5.27	11.88 ± 1.36	13.84 ± 3.97		
Median	13.0	12.0	12.0		

**Table 4:** Relation between the type of the used antipsychotic drug and I.O.P.

By using sperman test there was a significant correlation between duration of treatment with antipsychotics and intra ocular pressure for both eyes with p value < 0.001 and also there was a significant correlation between duration of treatment with typical antipsychotics alone and intra ocular pressure and in both eyes with p value (0.005 - 0.001) in right and left eye respectively.

Also there was a significant correlation between duration of treatment with combination therapy of antipsychotics and intra ocular pressure in both eyes with p value (0.001). Meanwhile there was a non-significant correlation between duration of treatment with atypical antipsychotics alone and intra ocular pressure in both eyes with p value (0.987 - 0.353) in right and left eye respectively (Table 5).

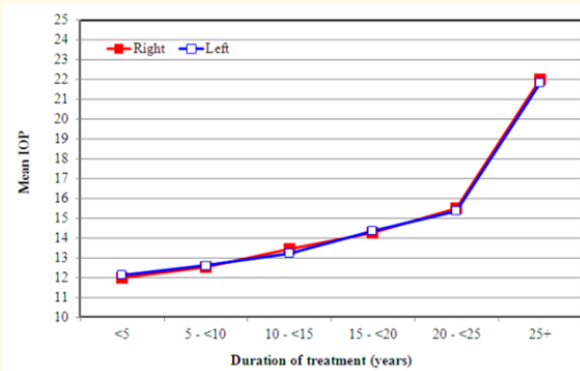
By using Kruskal Wallis test (Table 6), there was a significant difference between different duration categories of treatment with antipsychotics regarding to intraocular pressure in both eyes with p value < 0.001 for both eyes, it was highest with duration more than 25 years as shown by (Graph 2).

I.O.P	Duration (years)	
	r <sub>s</sub>	P
<b>Right</b>	0.454*	<0.001*
<b>Left</b>	0.379*	<0.001*
<b>Correlation between duration and I.O.P (typical alone)</b>		
<b>Right</b>	0.698*	0.005*
<b>Left</b>	0.779*	0.001*
<b>Correlation between duration and I.O.P (Atypical alone)</b>		
<b>Right</b>	0.007	0.987
<b>Left</b>	-0.248	0.353
<b>Correlation between duration and I.O.P (both)</b>		
<b>Right</b>	0.482*	0.001*
<b>Left</b>	0.419*	0.001*

**Table 5:** Correlation between duration and I.O.P (n= 100).

I.O.P	Duration of treatment (years)						H	P
	<5 (n=24)	5 - <10 (n=35)	10 - <15 (n=14)	15 - <20 (n=11)	20 - <25 (n=6)	25+ (n=10)		
<b>Right</b>								
Min. - Max.	8.0 - 16.0	10.0 - 24.0	12.0 - 18.0	10.0 - 20.0	12.0 - 23.0	10.0 - 24.0	29.468*	<0.001*
Mean ± SD.	12.0 ± 1.32	12.51 ± 2.24	13.43 ± 2.28	14.27 ± 3.29	15.50 ± 4.81	22.0 ± 4.27		
Median	12.0	12.0	12.0	14.0	13.0	23.0		
<b>Left</b>								
Min. - Max.	10.0 - 14.0	8.0 - 23.0	12.0 - 22.0	10.0 - 22.0	10.0 - 23.0	8.0 - 24.0	24.806*	<0.001*
Mean ± SD.	12.13 ± 0.95	12.60 ± 2.48	13.21 ± 2.72	14.36 ± 4.01	15.33 ± 5.13	21.80 ± 4.89		
Median	12.0	12.0	12.0	13.0	13.50	23.0		

**Table 6:** Relation between duration of treatment with I.O.P.



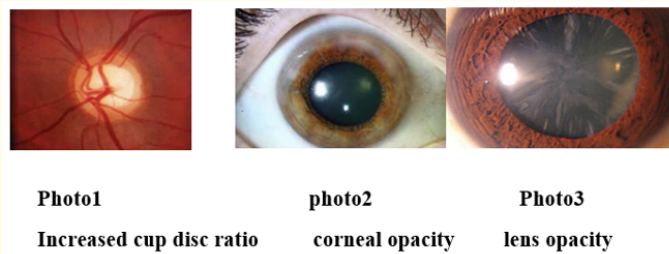
**Graph 2:** Relation between duration of treatment with I.O.P.

There was non-significant difference between the duration of treatment with typical antipsychotics alone and intraocular pressure in both eyes. There was a non-significant difference between duration of treatment with atypical antipsychotics alone and intraocular pressure in both eyes.

By using Kruskal Wallis test (Table 7) there was a significant difference between duration of treatment with combination therapy of antipsychotics and intraocular pressure in both eyes with p value (<0.001) in both eyes which is highest with duration more than 25 years. The majority of the cases have free fundus (normal cup disc ratio) (98%) and only (2%) of them have abnormality (increased cup disc ratio 0.5 LT, 0.6 RT) these 2 cases treated with typical antipsychotics alone.

I.O.P	Duration of treatment (years)						H	P
	<5 (n=17)	5 - <10 (n=28)	10 - <15 (n=7)	15 - <20 (n=8)	20 - <25 (n=3)	25+ (n=7)		
<b>Right</b>								
Min. - Max.	8.0 - 16.0	10.0 - 15.0	12.0 - 18.0	10.0 - 20.0	12.0 - 14.0	22.0 - 24.0	29.160*	<0.001*
Mean ± SD.	12.0 ± 1.58	12.29 ± 1.05	14.57 ± 2.76	14.38 ± 3.78	12.67 ± 1.15	23.29 ± 0.76		
Median	12.0	12.0	14.0	13.0	12.0	23.0		
<b>Left</b>								
Min. - Max.	10.0 - 14.0	8.0 - 18.0	12.0 - 22.0	10.0 - 22.0	10.0 - 15.0	22.0 - 24.0	25.143*	<0.001*
Mean ± SD.	12.06 ± 1.03	12.43 ± 1.83	14.14 ± 3.67	14.75 ± 4.68	12.33 ± 2.52	23.14 ± 0.69		
Median	12.0	12.0	12.0	12.50	12.0	23.0		

**Table 7:** Relation between duration of treatment with I.O.P (Both).



**Figure 1**

It was found that, there was a significant relation between lens opacity and duration of treatment with antipsychotics as shown in (Table 8).

Duration of treatment (years)	Lens		U	P
	Clear (n=93)	Cataract (n=7)		
Min. - Max.	0.75 - 38.0	5.0 - 35.0	128.500*	0.008*
Mean ± SD.	9.73 ± 8.21	20.0 ± 9.45		
Median	7.0	20.0		

**Table 8:** Relation between lens with duration of treatment.

There was a significant relation between lens opacity and duration of treatment with typical antipsychotics alone as shown by (Table 9).

Duration of treatment (years)	Lens		U	P
	Clear (n=8)	Cataract (n=6)		
Min. - Max.	0.75 - 12.0	5.0 - 35.0	4.500*	0.011*
Mean ± SD.	6.34 ± 4.66	21.0 ± 9.94		
Median	7.50	22.0		

**Table 9:** Relation between lens with duration of treatment (Typical).

### Discussion

Schizophrenia is a mental disorder characterized by abnormal social behavior and failure to understand what is real. Its symptoms typically occurs in young adulthood with approximately 1% of the world’s population affected [10].

The use of antipsychotic medications entails a difficult trade-off between the benefit of alleviating psychotic symptoms and the risk of troubling, sometimes life-shortening adverse effects. Once patients are exposed to different drugs with anticholinergic, adrenergic or serotonergic properties they can experience ocular toxic effects as a result of these properties [11]. The ocular adverse effects of these drugs depending upon the idiosyncrasies, dosages and the interactions with specific mechanisms of the body organs [12]. Males outnumbered females in the present study where males represented 78% of cases. The study entailed only ages ranged from 20 - 60 years as below the age of 20 years, the eyes not completely mature while above 60 years the aging process may

affect [13] This was in accordance to Souza., *et al.* (2008 ) [14], who conducted his study in the same age group. In the current study, 43% of the patients aged 31- 40 years. As regard visual acuity the present study, there was non-significant relation between visual acuity and the type of antipsychotic drug used for both eyes (p = 0.841 and 0.617 for right and left eyes respectively).

This was in agreement with Souza., *et al.* [14]. who conducted a study on 28 patients, four patients were on only typical antipsychotics (14.3%), sixteen were on only atypical antipsychotics (57.1%), and eight were on both typical and atypical antipsychotics (29.6%). Eleven patients (39%) were on phenothiazines, visual acuity was normal in 82% of cases. A slight reduction of visual acuity was found in 16% of them, and only 2% had moderate reduction of its visual acuity. For the cornea, in the present study, 4% of cases suffered from corneal opacity, all of them were on typical antipsychotics. There was non-significant relation between corneal opacity and duration of treatment with antipsychotics and also there was non-significant relation between corneal opacity and duration of treatment with typical antipsychotics alone.

Obviously there were no cases with corneal opacity among patients treated with atypical antipsychotics alone or combination therapy. Those results were in accordance to Grover and Avasthi [15] and Gowda., *et al.* [16] who recorded in their previous reports ocular adverse effects like a cataract of the lens and corneal endothelial deposits with prolonged use of chlorpromazine. Also, they reported three patients who developed corneal deposits and cataracts in both eyes secondary to prolonged chlorpromazine use resulting in visual impairment.

For typical antipsychotics, different studies revealed that the use of high doses typical antipsychotics for long periods is very much associated with eye opacities. Patients exposed to 800 mg/day for 2 years exhibited such findings which consist of swirling lines or fine streaks in the corneal epithelium [7,17].

That is not a serious condition because it does not cause visual impairment and tends to disappear, or at least diminish, after cessation of the drug [17].

In another study, Sönmez and Aykan (2013) [12], reported that 33% of patients using long term chlorpromazine have shown deposits in the cornea that was in near agreements with the present study as it was 28% on typical alone. On the other hand no changes



were found in the cornea in all cases treated with antipsychotics in a study done by Souza, *et al.* (2008) [14].

Regarding the lens in the present patients, only 7% of studied cases suffered from cataract. There was a significant relation between lens opacity and duration of treatment with typical antipsychotics alone. That was in accordance to Divakaran, *et al.* (2010) [18], who mentioned that Cataractous changes can result from antipsychotics, mainly high dosages typical antipsychotics for prolonged periods, they frequently cause lenticular opacifications. Pakzad-Vaezi (2013) [19], reported that typical antipsychotics, particularly the phenothiazines and with the exception of haloperidol, increase risk of cataract. This unwanted effect is related to the drug used and the dose.

For typical antipsychotics, Richa and Yazbek (2010) [7], reported that the use of high doses for long periods was very much associated with eye opacities.

Moreover lens deposits was found in about third of patients using long term chlorpromazine according to Sönmez, *et al.* (2013) [12] which was not in accordance with the present study. However, there are still no clear cut values that define the exact dose or duration of phenothiazines that increases the risk of opacity formation. 20) the risk of opacity may be explained by the photosensitizing properties of the drugs (such as chlorpromazine) that denature proteins and render them vulnerable to sunlight in a way that they form opacities, which become accumulated in the lens, cornea and skin; and endogenous melanin could trap free radicals produced by certain psychotropic agents (e.g. chlorpromazine), and the resulting compounds show as lens discoloration [7,20,21].

Such changes are subtle in presentation and do not show on gross inspection (without ophthalmological devices) [7,22].

On the other hand Pakzad-Vaezi, *et al.* (2013) [19], mentioned that the percentage of cases on typical antipsychotics that developed lens opacity was not found to be elevated as expected in their results. They explained that as the atypical antipsychotics were used his dataset 1.5 to 2.5 times more in than typical antipsychotics, a trend reflecting current practice methods for psychosis and other antipsychotic indications. Furthermore, the most prevalent typical antipsychotic in current use, haloperidol, has not been shown to increase cataract risk. As regards to atypical antipsychotics there was much debate as to whether the atypical antipsychot-

ics can cause cataract or not. Studies on dogs received four times the recommended human dose of atypical antipsychotics revealed cataract occurrence [20]. That may be explained by diabetogenic changes that sometimes occur with certain antipsychotics (e.g. olanzapine and clozapine) and an increased risk for cataractous changes (probably due to the effect of hyperglycaemia on the eye) [7]. In contrast, Souza, *et al.* (2008) [14] and Pakzad-Vaezi, *et al.* (2013) [19], indicated in their studies that is no risk of cataract in their patients, and they explained that by presence of serotonin receptors in the intraocular lens which play an important role in lens transparency. And serotonin itself was found to be cataractogenic in animal models [23] Serotonin levels are increased with the use of serotonin reuptake inhibitors and have been associated with an increased risk of cataract. A serotonin receptor blocker may provide a potential protective role. Atypical antipsychotics also demonstrate variable abilities to block muscarinic and histamine receptors. Topical miotics and anticholinesterases have a history of cataractogenesis [24], also certain atopic conditions associated with cataracts have elevated histamine levels in ocular tissues [25].

Therefore, the inhibition of these receptors provides further possibilities for the potential protective effect of atypical antipsychotics. Richa and Yazbek (2010) [7], reported trials in monkeys (at 5.5 times the recommended human dose) that did not increase cataract formation.) This was in disagreement with Souza, *et al.* (2008) [14], who conducted a study on 28 patients, Four patients were on only typical antipsychotics(14.3%), sixteen were on only atypical antipsychotics (57.1%), and eight were on both typical and atypical antipsychotics (29.6%).Anterior capsular clouding was found in 25% of patients. In the present study only 7% of all cases had clouding this may be attributed to difference in number of cases, type of drug used, dose of the drug and duration of treatment. Recent studies explained that typical antipsychotics and any psychiatric medication having anticholinergic effects can cause an angle closure with pupil block in a patient with anatomically narrow angles. The mechanism in such a case would be drug-induced mydriasis in an already crowded angle, either active or passive, depending on the drug. Thus, these drugs should be prescribed cautiously in patients with narrow angles [17,26,27].

As regard to atypical antipsychotics there is agreement with Lin, *et al.* (2007) [28] who reported that there is no known association between agents of new generation (atypical antipsychotics) and raised IOP.

Regarding cup disc, glaucomatous damage to cup disc was defined as asymmetry of cup-disc ratio > 0.2 between eyes, localized loss of neural rim, optic disc hemorrhage, and cup-disc ratio ≥ 0.5.

The present study shows that the majority of the cases have free fundus (normal cup disc ratio) (98%) and only (2%) of them have abnormality (increased cup disc ratio 0.5 LT, 0.6 RT) (glucomatus damage or glaucoma suspect). These two cases treated with typical antipsychotics alone (normal cup disc ratio is 0.3. This was in agreement with the study that reported increased cup disc ratio in patients on typical antipsychotics only [29].

On the other hand Souza, *et al.* (2008) [14], reported one patient out of 28 cases had a cup-disc ratio (CDR) asymmetry of 0.4. He was on atypical antipsychotic. He explained that by increased intraocular pressure. The suggestive findings of glaucoma, raised intraocular pressure and asymmetry of cup-disc ratio > 0.2 between eyes, showed a significant correlation with ziprasidone use.

### Conclusions

From the present study it was concluded that there was a conjunctival pigmentation occurs, lens opacity and corneal opacity in patients who treated with typical antipsychotics alone. On other hand, increased IOP noted only in patients treated with combination therapy and typical only. There was a significant correlation between duration of treatment with antipsychotics and IOP for both eyes. The majority of the cases have free fundus and only (2%) of them who treated with typical antipsychotics alone have abnormality. So increased cup disc ratio (glaucoma suspect) occurs only with typical antipsychotic.

It was recommended that:

1. Ocular screening could be considered in patients receiving chronic antipsychotic treatment.
2. Early prevention and intervention can avoid most of the serious and potentially irreversible ocular antipsychotic toxicity.
3. Further studies should be conducted on large scale of patients and use other methods of examination and more advanced investigations.

### Bibliography

1. Brunton L and Chabner B. "Goodman and Gilman's The Pharmacological Basis of Therapeutics". 12<sup>th</sup> edition. Newyork: McGraw-Hill Education (2011): 417.

2. Lisa H., *et al.* "Antipsychotics in adults with schizophrenia: comparative effectiveness of first-generation versus second-generation medications: a systematic review and meta-analysis". *Annals of Internal Medicine* (2012).
3. King C and Voruganti LN. "What's in a name? The evolution of the nomenclature of antipsychotic drugs". *Psychiatry and Neuroscience* 27.3 (2002): 168-175.
4. Hippus. "The history perspective of clozapine". *Psychopharmacology* 99.1 (1989): 3-5.
5. Hoffman RS, *et al.* "Manual of toxicologic emergencies". 9<sup>th</sup> edition. New York: The McGraw-Hill Companies (2007): 588-589.
6. Tripathi BJ. "Drug induced ocular disorders". *Drug Safety* 31.2 (2008): 127-141.
7. Sami Richa and Jean-Claude Yazbek. "Ocular Adverse Effects of Common Psychotropic Agents article review". *CNS Drugs* 24.6 (2010): 501-526.
8. Trudie S. "Anti-Psychotic Agents Related Ocular Toxicity". *Medicine* 95.15 (2016): 3.
9. Kanski JJ. "Clinical ophthalmology". 5<sup>th</sup> editon. Oxford (UK): Butterworth-Heinemann (2006).
10. World Health Organisation. "Mental disorders Fact sheet N°396"(Data base on the internet). (2014).
11. Helo A., *et al.* "The maturation of eye movement behavior: Scene viewing characteristics in children and adults". *Vision Research* 103 (2014): 83-91.
12. Sönmez İ and Aykan Ü. "Psychotropic Drugs and Ocular Side Effects". *Turkish Journal of Ophthalmology* 43.4 (2013): 270-278.
13. Carmona R and Prince K. "Trauma and forensic medicine". *Journal of Trauma* 29.9 (1989):1222-1225.
14. Souza VB, *et al.* "Intraocular pressure in schizophrenic patients treated with psychiatric medications". *Arquivos Brasileiros de Oftalmologia* 71.5 (2008): 660-664.
15. Grover S and Avasthi A. "Anti-psychotic prescription pattern: a preliminary survey of Psychiatrists in India". *Indian Journal of Psychiatry* 52.3 (2010): 257-259.
16. Gowda GS, *et al.* "Kerato-lenticular ocular deposits and visual impairment with prolonged chlorpromazine use: A case series". *Asian Journal of Psychiatry* 25 (2017):188-190.



17. Raizman MB., *et al.* "Drug-Induced Corneal Epithelial changes". *Survey of Ophthalmology* 62.3 (2016): 286-301.
18. Divakaran A., *et al.* "Chlorpromazine induced cataract in a young patient with schizophrenia". *Indian Journal of Psychological Medicine* 32 (2010): 69-70.
19. Pakzad-Vaezi KL., *et al.* "The Association between Cataract Surgery and Atypical Antipsychotic Use: ANested Case-Control Study". *American Journal of Ophthalmology* 156.6 (2013): 1141-1146.
20. Bitterman RA. "Medicolegal and Risk Management". In: John, Marx, Robert, Hockberger, Ron, Walls. *Rosen's Emergency Medicine: Concepts and Clinical Practice*. 5<sup>th</sup> edition. USA: Mosby (2002): 2747-2760.
21. Morley J., *et al.* "Peripheral Vascular Injuries". *Emedicine* (2007).
22. Vivekanandan S and Lou MF. "Evidence for the presence of phosphoinositide cycle and its involvement in cellular signal transduction in the rabbit lens". *Current Eye Research* 8.1 (1989): 101-111.
23. Boerrigter RM., *et al.* "Serotonin (5-HT) and the rat's eye: some pilot studies". *Documenta Ophthalmologica* 82.1-2 (1992): 141-150.
24. Gin-Shaw SL and Jordan RC. "Multiple Trama". In: John, Marx, Robert, Hockberger, Ron, Walls. *Rosen's Emergency Medicine: Concepts and Clinical Practice*. Fifth edition. USA: Mosby (2002): 242-255.
25. Hyams AL., *et al.* "Practice guidelines and malpractice litigation: a two-way street". *Annals of Internal Medicine* 122.6 (1995): 450-455.
26. Zimmerman TJ and Wheeler TM. "Miotics: side effects and ways to avoid them". *Ophthalmology* 89.1 (1982): 76-80.
27. Uchio E and Miyakawa K. "Systemic and local Immunological features of atopic dermatitis patients with ocular complications". *British Journal of Ophthalmology* 82.1 (1998): 82-87.
28. Lin TH and Chen IJ. "Hypotensive intraocular pressure activity of clozapine and sulpiride (2007).
29. J Coutinho., *et al.* "Cup to disc ratio (CDR) In patients with schizophrenia a preliminary cross-sectional study". *German Journal of Psychiatry* 11.2 (2008).

#### Assets from publication with us

- Prompt Acknowledgement after receiving the article
- Thorough Double blinded peer review
- Rapid Publication
- Issue of Publication Certificate
- High visibility of your Published work

**Website:** <https://www.actascientific.com/>

**Submit Article:** <https://www.actascientific.com/submission.php>

**Email us:** [editor@actascientific.com](mailto:editor@actascientific.com)

**Contact us:** +91 9182824667