

## Chordoid Meningioma

Hassan Baallal<sup>1\*</sup>, Ali Akhaddar<sup>1</sup>, Miloud Gazzaz<sup>2</sup> and Brahim El Moustarchid<sup>2</sup>

<sup>1</sup>Department of Neurosurgery, Avicenne Military Teaching Hospital, University Kaddi Ayyad, Marrakech, Morocco

<sup>2</sup>Department of Neurosurgery, Mohammed V Military Teaching Hospital, University of King Mohammed V Souissi, Rabat, Morocco

\*Corresponding Author: Hassan Baallal, Department of Neurosurgery, Avicenne Military Teaching Hospital, University Kaddi Ayyad, Marrakech, Morocco.

Received: May 21, 2019; Published: June 12, 2019

### Abstract

Chordoid meningioma is a rare variety of meningioma (0.5% - 1%) with high rate of recurrence. They are grouped in WHO Grade II tumors. They are mainly distributed in the supratentorial location. They have an aggressive clinical course, to the best of our knowledge, 284 chordoid meningiomas have been reported in the literature.

We report in this sense a new observation of cerebellar chordoid meningioma.

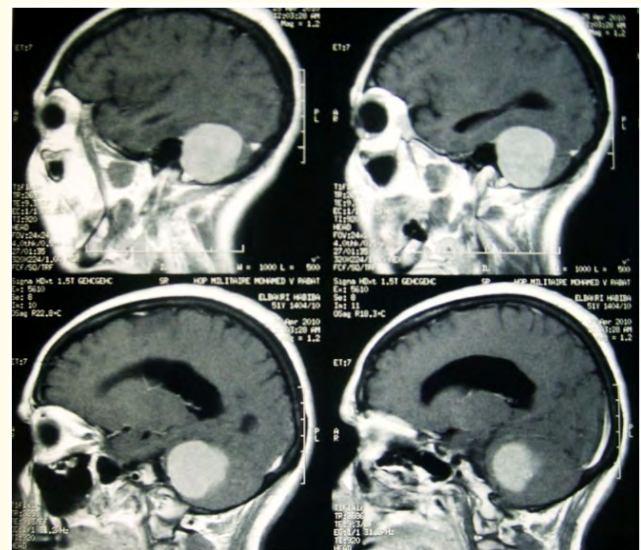
**Keywords:** Chordoid Meningioma; Cerebellar Syndrome

### Introduction

Meningiomas are among the most varied of all intracranial lesions. They present with a range of symptoms, as well as imaging and histopathological features, explaining why they are often called the 'great masqueraders'. Chordoid meningioma is a rare variant of meningioma. Only 284 cases have been reported in the literature to date. It is often confused with chordoma and has a high potential for recurrence. We report in this sense a new observation.

### Case Report

This is a patient of 38 years without disease history, who present for six months a syndrome of intracranial hypertension with a cerebellar syndrome. The MRI showed an expanding cerebellar process, 5 × 6 cm (Figure 1), enhancement after gadolinium administration. Complete surgical resection was performed. Pathological examination of the resected tumor showed a proliferation of heterogeneous architecture, consisting mainly of lobules separated by a fibro-inflammatory stroma. Within these lobules, tumor cells were disposed in cords and trabeculae bathed in abundant myxoid frame. This aspect was Chordoid evoke a meningioma. The postoperative course was uneventful and CT scan confirmed the complete removal of the tumor.



**Figure 1:** MRI showed an expanding cerebellar process, with enhancement after gadolinium administration.

### Discussion

The term “chordoid meningioma” was first used by Kepes., *et al.* [1] in 1988, to describe a meningeal tumor displaying histological

characteristics closely imitating those of chordoma and that arise in young patients who had iron-refractory hypochromic microcytic anemia and/or dysgammaglobulinemia. The first known case with similar clinical and histopathological features, was reported by Connors [2] in 1980 and later reviewed by Dimand, *et al.* [3] in 1985. Most chordoid meningiomas arise within the supratentorial intracranial space and particularly over the cerebral convexities. These meningiomas appear as a hyperintense mass on T1-weighted MRI, while on T2-weighted FLAIR sequences they appear as a hypointense mass, with brilliant contrast enhancement seen either within the brain parenchyma. The chordoid meningiomas are frequently confused with glial or metastatic tumors. Intracerebral “cystic” meningiomas, and rhabdoid meningiomas with a cystic component, are rarely described.

Chordoid meningioma (CM) is a meningioma containing regions that are histologically similar to chordoma, with trabeculae of eosinophilic, vacuolated cells in a myxoid background and corresponds to WHO grade II [4]. Such a tumor is a rare variant first described by Kepes, *et al.* in 1988 in young patients associated with Castleman syndrome [1]. Only a series [5] and a few case reports [6-8] were published.

But the largest series of chordoid meningiomas was reported by Couce, *et al.* [5] in 2000. Their study included 42 chordoid meningiomas representing 0.5% of all meningiomas operated in Mayo Clinic from 1975 to 1997. In this study, the clinical features of the patients were found to be significantly different from those observed in previous studies. The patient age ranged from 12 to 77 years (mean, 44 yrs) and only two tumors (5.2%) occurred in children. In contrast to previous reports, no significant association with systemic or hematologic abnormalities were found. To the best of our knowledge, about 80 cases have been previously published, but unpublished cases are often recorded. Ultrastructural features of these tumors are studied in only few reports and are not yet precisely ascertained. We present a new case of a relapsing chordoid meningioma with aggressive behavior and acute clinical presentation and a “chordoid progression” of the tumor characterized by histological and ultrastructural modification. Although most meningiomas are benign and are graded into WHO grade I, the chordoid variant is associated with a less favourable clinical outcome and is graded into WHO grade II. The extent of chordoid pattern is also important in predicting prognosis. Couce, *et al.* [5]

observed that in the majority (85.7%) of recurred cases, the primary, tumors show chordoid pattern in more than 50% of the tumor tissue.

There have been only two studies on chromosomal aberrations in chordoid meningioma in the available literature. One on chromosomal alteration of primary and recurrent chordoid meningioma evaluated the loci MYCN, ERBB4, CDH1, ABR, ERBB2 and NF2 probes [9] and showed that there is some level of alteration in genes such as NF2, MYCN, ABR, and ERBB2 among primary and recurrent chordoid meningioma [9].

Another study showed an unbalanced translocation of t(1;3) (p12-13;q11) as a unique feature of chordoid meningioma [10,11].

Another study was reported by Junxi dai [12] identified several hub genes, including JUN, PIK3R1, FOS, AGT and MYC, that may be functionally relevant to the pathogenesis of meningioma.

Another study was reported by Corinna Seligerand, *et al.* [13] concluded that the Obesity and arterial hypertension are positively associated with risk of meningioma. Further studies are needed to better understand potential underlying biologic mechanisms.

## Conclusion

The existing literature about the clinicopathological behaviour and management strategies for CM is sparse. chordoid meningiomas are treated with surgery and post-operative radiotherapy. Chemotherapy has been tried in these tumors without any significant survival benefit. The meningioma in our patient had two unusual features; the chordoid variant, and intracerebral location.

## Conflicts of Interest Statement

All authors certify that they have no affiliations with or involvement in any organization or entity with any financial interest (such as honoraria; educational grants; participation in speakers' bureaus; membership, employment, consultancies, stock ownership or other equity interest; and expert testimony or patent-licensing arrangements) and nonfinancial interest (such as personal or professional relationships, affiliations, knowledge or beliefs) in the subject matter or materials discussed in this manuscript.

The manuscript has been approved by all authors and has never been published or under the consideration for publication elsewhere.

## Bibliography

1. Kepes JJ, *et al.* "Chordoid' meningeal tumors in young individuals with peritumoral lymphoplasmacellular infiltrates causing systemic manifestations of the Castleman syndrome. A report of seven cases". *Cancer* 62.2 (1988): 391-406.
2. Connors MH. "Growth and maturation arrest, hypochromic anemia and hyperglobulinemia associated with a brain tumor". *Western Journal of Medicine* 133.2 (1980): 160-163.
3. Dimand RJ, *et al.* "Headache and growth arrest in an adolescent". *Hospital Practice* 20.11 (1985): 50-60.
4. Louis DN, *et al.* "Meningiomas". In: Kleihues P, Cavenee WB, eds. *Pathology and Genetics of Tumors of the Nervous System*. Lyon: IARC (2000): 176-184.
5. Couce ME, *et al.* "Chordoid meningioma: a clinicopathologic study of 42 cases". *American Journal of Surgical Pathology* 24.7 (2000): 899-905.
6. Glasier CM, *et al.* "Meningiomas in children: MR and histopathologic findings". *American Journal of Neuroradiology* 14.1 (1993): 237-241.
7. Salinero E, *et al.* "Intraoperative cytologic diagnosis of chordoid meningioma: a case report". *Acta Cytologica* 48.2 (2004): 259-263.
8. Denaro L, *et al.* "Pyrogenic cytokine interleukin-6 expression by a chordoid meningioma in an adult with a systemic inflammatory syndrome. case report". *Journal of Neurosurgery* 103.3 (2005): 555-558.
9. Cordeiro AP, *et al.* "Comparative analysis of proliferative and genetic alterations in a primary chordoid meningioma and its recurrence using locus-specific probes and AgNOR". *Molecular Medicine Reports* 2.3 (2009): 449-454.
10. Steilen-Gimbel H, *et al.* "Unbalanced translocation t(13)(p12-13q11) in meningiomas as the unique feature of chordoid differentiation". *Genes Chromosomes Cancer* 26.3 (1999): 270-272.
11. Sangoi AR, *et al.* "Distinguishing chordoid meningiomas from their histologic mimics: An immunohistochemical evaluation". *American Journal of Surgical Pathology* 33.5 (2009): 669-681.
12. Junxi dai, *et al.* "Identification of key genes and pathways in meningioma by bioinformatics analysis". *Oncology Letters* 15.6 (2018): 8245-8252.
13. Corinna Seliger and Christoph R. "Meier Claudia Becker and all Metabolic syndrome in relation to risk of meningioma". *Oncotarget* 8.2 (2017): 2284-2292.

**Volume 3 Issue 7 July 2019**

© All rights are reserved by Hassan Baallal, *et al.*