



Cardiac Emergencies in Neonates

Samah Alasrawi*

Pediatric Cardiologist, AlJalila Children Heart Center, Dubai UAE

***Corresponding Author:** Samah Alasrawi, Pediatric Cardiologist, AlJalila Children Heart center, Dubai, UAE

Received: May 14, 2019; **Published:** May 24, 2019

Abstract

Introduction: The diagnosis of cardiac disease in the neonates is not always straight forward because physical examination, ECG, and CXR are often difficult to interpret in the newborn period compared to older infant or child.

Although echocardiography is required to precisely define the anatomical abnormality, it is usually possible to define.

The most important factors in narrowing down the diagnostic possibilities are:

The clinical presentation

- Shock (ductal dependent systemic circ.) (Grey baby)
- Cyanosis (ductal dependent pulmonary circ.) (Blue Baby) including severe Ebstein's anomaly
- CHF congestive heart failure (shunt lesions) (Pink Baby)
- Arrhythmia

The timing of the presentation (age)

Associated non cardiac or genetic anomalies

Objective: To Concentrates on few points which make the diagnosis and managements of cardiac emergencies in neonates easier.

Keywords: Neonates; Cardiac; Emergencies

Introduction

The diagnosis of cardiac disease in the neonates is not always straight forward because physical examination, ECG, and CXR are often difficult to interpret in the newborn period compared to older infant or child.

Although echocardiography is required to precisely define the anatomical abnormality, it is usually possible to define the functional abnormality on the basis of the clinical and radiographic findings.

The timing of presentation and severity depends on

- Nature and severity of defect
- The alteration in cardiovascular physiology secondary to the effect of the transitional circulation as
- Closure of ductus/restriction of patent foramen ovale (PFO)
- Fall in pulmonary vascular resistance (PVR)

The most important factors in narrowing down the diagnostic possibilities are

- The clinical presentation
 - Shock (ductal dependent systemic circ.) (Grey baby)
 - Cyanosis (ductal dependent pulmonary circ.) (Blue Baby) including severe Ebstein's anomaly
 - GHF congestive heart failure (shunt lesions) (Pink Baby)
- The timing of the presentation (age)
- Associated non cardiac or genetic anomalies

So the vital signs and clinical examination in newborns are very important And lead to the right diagnosis: (Right sided obstructive lesions(cyanosis), Left sided obstructive lesions (Collapse), Mixing lesions (cyanosis with CHF), ASD dependent lesions (cyanosis with CHF) And give a chance to start PGE1 when there is any suspicion of PDA dependent lesion (systemic or pulmonary) before the Echo.

Neonatal Presentations

1. Cyanosis 2. Shock 3. CHF 4. Arrhythmias

Septicemia, respiratory disorders, persistent pulmonary hypertension of newborn (PPHN), inborn errors of metabolism and so on.

Neonatal Presentations

1. Cyanosis 2. Shock 3. CHF 4. Arrhythmias

Septicemia, respiratory disorders, persistent pulmonary hypertension of newborn (PPHN), inborn errors of metabolism and so on.

Cyanosis**Cardiac causes**

- PDA dependent pulmonary circulation
- Admixture lesions
- Critical Right ventricular outflow tract obstruction with intracardiac shunt

Case 1

Asymptomatic neonate was discharged on breast feeds

- Suddenly presents at 3 days of life with bluish discoloration
- Sats 70, mild tachypnea and minimal distress, soft ESM, No response to oxygen
- Ventilation –mild increase in saturations (75%)

CXR: Oligemic lung fields and no cardiomegaly Figure 1

Plan: Start Prostaglandin E1 and get Echo

Why PGE1 started, can we do it without echo, what is the probable DD.

Pulmonary atresia with VSD

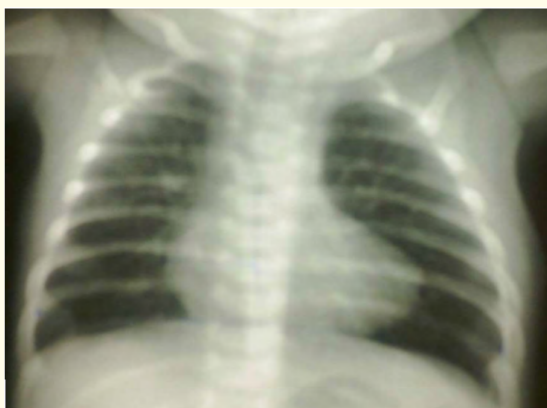

Figure 1

PDA dependent pulmonary circulation

1. Pulmonary Atresia, Intact Ventricular Septum
2. Pulmonary Atresia, VSD and PDA
3. Pulmonary Atresia with Single Ventricle
4. Severe forms of Epstein's anomaly

What is common to all these lesions**Oligemic lung fields on CXR****Admixture lesions**

- Transposition of Great Arteries, intact Interventricular septum
- Total Anomalous Pulmonary venous connection
- Truncus Arteriosus
- Double Outlet Right Ventricle with VSD
- Single ventricle anomalies with or without Pulmonary stenosis

Critical Right ventricular outflow tract obstruction with intra cardiac shunt

- Critical Pulmonary Stenosis with interatrial communication
- Tetralogy of Fallot with Critical Pulmonary Stenosis

Pulmonary causes**Primary lung disease**

- Respiratory distress syndrome
- Meconium aspiration

PPHN

- Pneumonia
- Tracheo- esophageal fistula

Airway obstruction

- Choanal atresia, laryngotracheomalacia, laryngeal web, vocal cord paralysis
- Extrinsic compression of the lungs
- Pneumothorax
- Chylothorax, Hemothorax
- Diaphragmatic Hernia, Space occupying lesions

Neurologic causes

- Drug-induced depression of respiratory drive,
- Intracranial hemorrhage,
- Post asphyxia cerebral dysfunction,
- Central apnea
- Respiratory neuromuscular dysfunction

- Spinal muscular atrophy,
- Infant botulism,
- Neonatal myasthenia gravis

Hematologic causes

Methemoglobinemia or polycythemia cyanotic with normal Pao₂

How to identify cardiac vs respiratory causes of cyanosis (Table 1)

Parameters	Respiratory pattern	Saturation difference between right upper limb (Rt) and lower limb (LL)	PCO ₂	Response to 100 % oxygen
Cardiac disease	Increased respiratory rate with minimal distress	Usually no difference unless specific lesions	Normal or low	No significant change
Primary pulmonary disease	Increased respiratory rate with distress	No difference	High	Increased saturations
PPHN	Increased respiratory rate with distress	>10% Rt >LL	Normal or high	May or may not change

Table 1

Hyperoxia Test

Differentiate mainly cardiac from respiratory cyanosis (Table 2)

If resting saturations are less than 95%.

	At Fio ₂ = 0.21 Pao ₂ (Saturation %)	At Fio ₂ = 1.00 Pao ₂ (Saturation %)	PaCo ₂
Normal	>70 (>95)	>300 (100)	Normal
Pulmonary disease	50 (85)	>150 (100)	111211
Neurological disease	50 (85)	>150 (100)	High
Methemoglobinemia	>70 (<85)	>200 (<85)	Normal
Cardiac disease	40-60 (75-93)	<150 (<93)	Normal
PPHN	Preductal 40-70 (75-95)	Variable	Nomal/high
	Post ductal <40 (75)	Variable	

Table 2: Hyperoxia test.

Interpretation of hyperoxia test

- PaO₂ more than 250 mmHg excludes cyanotic congenital heart disease
- PaO₂ is more than 150, cyanotic CHD unlikely
- Pao₂ less than 150, Cyanotic CHD

Limitations of hyperoxia test

- False positive

TAPVC and HLHS may respond to oxygenation

- False negative

Pulmonary disease with a massive intrapulmonary shunt may not respond to oxygenation.

Differential cyanosis

Preductal saturation > Post-ductal saturation

- Persistent Pulmonary Hypertension of the newborn (PPHN)
- Interrupted aortic arch (Figure 2), critical coarctation of the aorta and critical aortic stenosis.

Lower limb blue, Rt upper limb pink

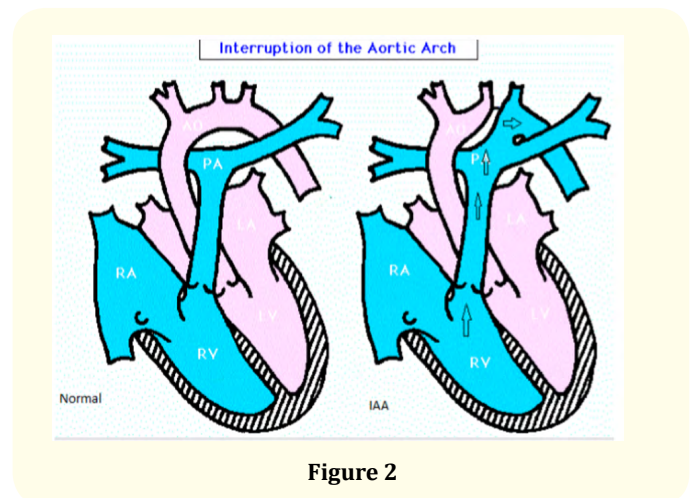


Figure 2

Reverse differential cyanosis

Pink Lower limb, blue upper limb

The post ductal saturation higher than the preductal saturation.

We notice it in many cases like:

- TGA with (critical coarctation of the aorta, interrupted aortic arch, critical aortic stenosis)
- TGA with PPHN.

Classification of Cyanotic CHD

Decreased PBF

- TOF/TGA, VSD, PS/DORV, VSD, PS/TA, VSD, PS/SV, PS/ Pulmonary atresia

Increased PBF

TGA, VSD/Truncus/TAPVC (admixture)/SV without PS/TA, VSD without PS

Chest X ray (figure 3)

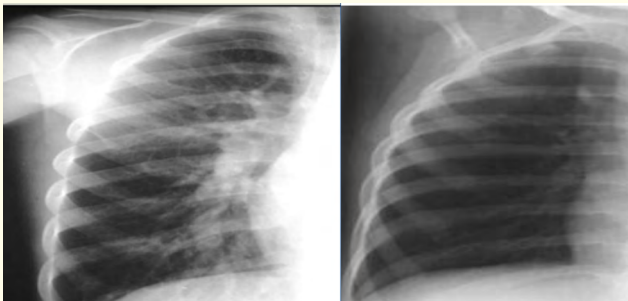

Figure 3: High PBF (left) and low PBF (right).

- Rule out respiratory issues
- Assess pulmonary blood flow and presence of Cardiomegaly

Increased PBF features on CXR

- Cardiomegaly
- Increased vascularity

Shock

Case 2

D3 old baby –suddenly sick

- Poor feeding, Not passing urine
- Color not Looking good –pale
- Cold peripheries, Tachypnoea, tachycardia poor pulses, BP 32/20, metabolic acidosis, raised lactates

- A healthy newborn who presents after 48-72 hrs of life with sudden onset of pallor, grey appearance and breathing difficulty.
- Not passing urine and not taking feeds over last 4-6 hrs
- Metabolic acidosis
- Start prostaglandin E1 suspecting duct dependent systemic circulation??
- Other measures to stabilize including ventilation and inotropes (unless echo rules out cardiac lesion).

Cardiac causes of shock:

- Duct dependent systemic circulation and Left ventricular outflow Tract obstructions
 - Critical Aortic stenosis and coarctation, Interrupted aortic arch
 - Hypoplastic Left Heart Syndrome (HLHS)
- Obstructive TAPVC
- Rhythm disturbances: Tachyarrhythmias and Brady arrhythmias (e.g. complete heart block)

Prostaglandin E1

How do we start Prostaglandin?

- Dose - 0.001-0.4 microgram/kg/min infusion
- Higher doses 0.1 mic/kg/min should be used to reopen the closed PDA (or if there is sudden onset of severe cyanosis or shock).
- Once the duct has opened, dose can be reduced to a minimum

If no Response to prostaglandin Infusion (Table 3).

Diagnosis	Management
Transposition of Great Arteries with Intact Ventricular Septum and a restrictive interatrial communication	Needs emergency Balloon Atrial Septostomy
Obstructed TAPVC	Emergency surgery
Non Cardiac Diagnosis	Treatment of etiology

Table 3

Congestive heart failure

Cyanotic heart disease with high pulmonary flow

- Truncus Arteriosus
- Single ventricle physiology without Pulmonary Stenosis
- Transposition of Great Arteries with VSD
- Double Outlet Right Ventricle with VSD

- Total Anomalous Pulmonary venous connection anotic heart disease with high pulmonary flow
 - Not significantly cyanotic due to high pulmonary blood flow
 - Saturation may vary in the range of 90's.
 - Naked eyes will not pick up the cyanosis
 - Pulse oximetry -- early detection
- Left sided obstructive lesions (Collapse) – critical AS, IAA, COA, HLHS
- Mixing lesions (cyanosis with CHF) – TGA
- ASD dependent lesions (cyanosis with CHF) TAPVC, Tricuspid atresia

Acyanotic heart disease with high pulmonary flow

- Preterm with significant post tricuspid shunt lesions (e.g. VSD, PDA, Aorto- Pulmonary window)
- Severe valvular regurgitant lesions (e.g. Mitral regurgitation associated with AV canal defects)
- Anomalous Left Coronary Artery from Pulmonary Artery (ALCAPA)
- Cardiomyopathy

Rhythm disturbances

- Tachyarrhythmias
- Brady arrhythmias (e.g. complete heart block, High degree second heart block)

Non Cardiac causes

- High output states like anemia, thyrotoxicosis, systemic Arteriovenous malformations (g.e.Vein of Galen)

Clinical features

- Difficulty in feeding
- sub costal indrawing
- sweating with feeds
- Tachypnoea
- Tachycardia
- gallop rhythm and hepatomegaly.

Arrhythmias

- SVT
- Brady arrhythmias with Long QTc

Neonatal Interventions

- BAS-Ballon atrial Septostomy
- BPV-Ballon pulmonary valvuloplasty
- BAV-Ballon aortic valvuloplasty
- Ballon Coarct angioplasty
- PDA stenting

Conclusion

- Right sided obstructive lesions(cyanosis) - critical PS, pulmonary atresia

Important message

- Vital signs and clinical examination in newborns are very important
- Starting PGE1 when there is any suspicion of PDA dependent lesion (systemic or pulmonary) before the Echo.

Bibliography

1. Tsao PC., et al. "Development of a newborn screening program for critical congenital heart disease (CCHD) in Taipei". *PLoS One* 11 (2018): e0153407.
2. Meyer S., et al. "Specific aspects of pediatric emergencies in the prehospital setting". *Medizinische Klinik, Intensivmedizin* 111 (2016): 65-77.
3. Gardner TH. "Cardiac emergencies in the newborn period". *Radiology clinic of North America* 9 (1999): 385-397.
4. Schamberger M. "Cardiac emergencies in Children". *Pediatric Annuals* 25 (1996): 339-344.
5. Gewitz M and Vetter V. "Cardiac Emergencies". In: Fleisher GR, Ludwig S (edr) Text book of Pediatric Emergency Medicine. Lippincott Williams and Wilkins, Philadelphia (2010).
6. Colli AM., et al. "Balloon dilation of critical valvar pulmonary stenosis in the first month of life". *Journal of the American College of Cardiology* 34 (2005): 23-28.
7. Schranz D., et al. "Stent implantation of the arterial duct in newborns with duct dependent circulation". *European Heart Journal* 19 (1995): 1401-1409.
8. Watson T., et al. "Eustachian valve remnant". *Cardiology Journal* 14 (2007): 508-509.
9. Kabbani MS and Cassin S. "The effects of cGMP on fetal sheep pulmonary blood flow and lung liquid production". *Pediatrics Research* 43 (2008): 325-330.
10. Anilkumar M. "Patent ductus arteriosus". *Cardiology Clinics* 31 (2013): 417-430.

Volume 3 Issue 6 June 2019

© All rights are reserved by Samah Alasrawi.