



## Anterolateral (Supra-Iliac) Extra-Anatomic Ilio-Femoral Bypass for an Infected Prosthetic Femoral Graft: A Case Report

Jassim Al-Ali<sup>1</sup>, Huthayfa Ghanem<sup>2\*</sup>, Emad Kamal<sup>3</sup>, Ibrahim Hanbal<sup>4</sup>, Harun Sestic<sup>5</sup>, Marzouk Al-Bader<sup>1</sup>, Sami Asfar<sup>6</sup>

<sup>1</sup>Consultant Vascular Surgeon – Mubarak Al-Kabeer Hospital

<sup>2</sup>Senior Vascular Fellow, Bedford Hospital NHS Trust, UK

<sup>3</sup>Senior Vascular Surgery Registrar – Mubarak Al-Kabeer Hospital

<sup>4</sup>Professor of Vascular Surgery, Al-Azhar Faculty of Medicine, Egypt

<sup>5</sup>Senior Vascular Surgery Specialist, Mubarak Al-Kabeer Hospital, Kuwait

<sup>6</sup>Professor of Surgery and Senior Consultant Vascular and Hepatic Surgeon, Kuwait University Health Sciences Center, Kuwait

\*Corresponding Author: Huthayfa Ghanem, Senior Vascular Fellow, Bedford Hospital NHS Trust, UK.

Received: April 29, 2019; Published: May 09, 2019

### Abstract

One of the easy and effective temporary approaches to manage significant vascular prosthetic infections and to rescue the limbs perfusion is to bypass the groin and pelvis altogether. This can be done by routing the new graft antero-laterally above the iliac crest, which is a less time-consuming and less technically demanding procedure that is available for such ominous situations.

**Keywords:** Extra-anatomic; Antero-lateral; Supra-cristal; Septic Groin; Vascular Graft Infection

### Introduction

Many different routes are available to bypass septic vascular prostheses in the groin such as trans-obturator, crossover trans-obturator tunneling, creation of a window in the iliac bone [1-3]. However, pelvic sepsis may be overwhelming and, in such conditions, tunneling through these routes may be exceedingly risky [4-6].

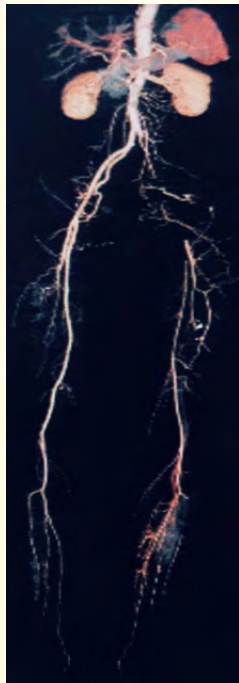
### Case Presentation

A 64-year-old lady who is diabetic and hypertensive, with a history of colonic polyposis and breast fibroadenomata, presented with a delayed acute on chronic left lower limb ischaemia in May 2013. Iliac lesion angioplasty was tried but the procedure was complicated by femoral artery (puncture-site) injury; consequently, a Dacron 7 mm graft interposition was done as there was no suitable vein graft, along with decompressive fasciotomies for the accompanying compartment syndrome, which required split-thickness skin grafting.

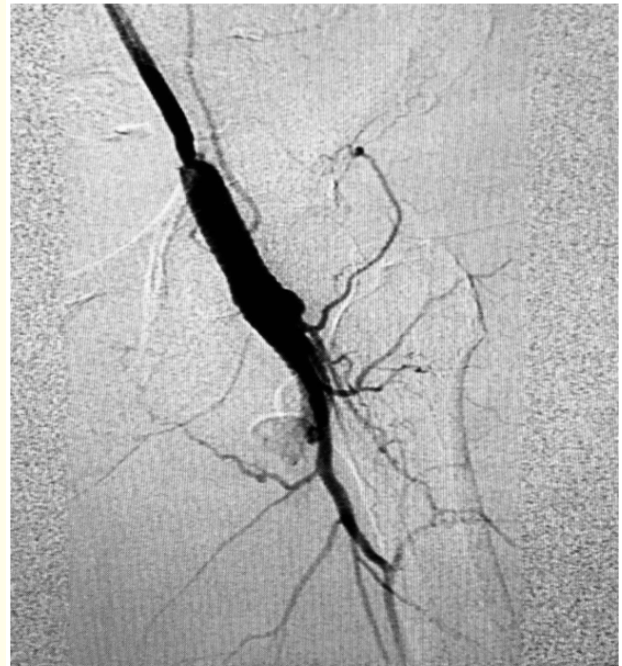In August 2017, she came with a picture of vascular graft infection (presented with a pulsating left groin mass with skin

breakdown and was discharging turbid blood-stained fluid, as well as signs of systemic toxicity such as high temperature, leukocytosis 22,000 cells/mm<sup>3</sup> and CRP was 200 mg/L. CT angiography showed pseudoaneurysm at the distal anastomosis with a surrounding contrast blush); therefore, broad-spectrum parenteral antibiotics (meropenem and ciprofloxacin) were started, the graft was removed, and external iliac and superficial and profunda femoral segments were ligated. Emergency bypass was done with Gore-Tex® 8 mm graft and Gore-Tex® 5/0 sutures from the left common iliac artery (retro-peritoneally) to the left distal superficial femoral artery (very distant from the previous thigh wound) and the graft was tunneled over the iliac crest antero-laterally to avoid the infected pelvic tissues. Post-operatively, the infected wounds of the first surgery improved on VAC wound therapy, and the parenteral antibiotics were modified (Tazocin and teicoplanin) according to culture and sensitivity results (Discharge fluid and a deeper tissue specimen grew *ESBL E. coli* and so did the deeper tissue specimen) and continued for 6 weeks.

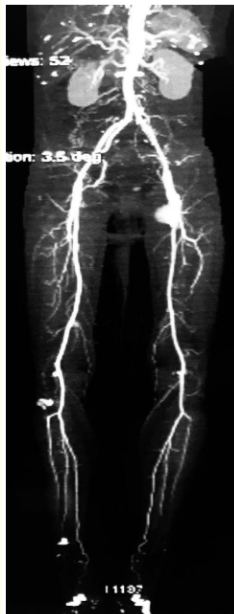During her last visit in July 2018 the wounds were healed, posterior tibial pulses were clinically palpable, bilaterally, and the ABI was 1.1 on the right side and 0.95 on the operated side.



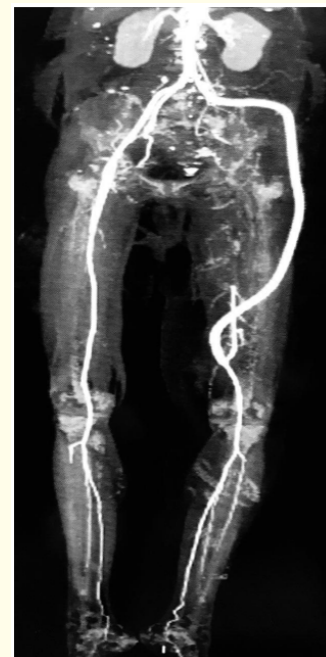**Figure 1:** CTA done after the initial presentation and revealed left iliac and femoral total occlusion, calcifications and collateralization.



**Figure 3:** DSA showing proximal SFA pseudoaneurysm and contrast blushing.



**Figure 2:** CTA done 4 years after the initial revascularization and showed patent interposition graft and a distal anastomotic (proximal SFA) pseudoaneurysm.



**Figure 4:** CTA one month after the extra-anatomic bypass showing the course and patency of the graft and ruled-out peri-graft collections.

## Discussion

Vascular graft infection may present many years after the graft implantation and carries a high risk of morbidity and mortality. The appropriate stage of this vascular prosthetic infection was Szilagyi III, Samson V, and Karl VI i.e. this was a deep graft infection associated with a complication that warrants graft removal [7-9]. The reported mortality rate is 17% and amputation rate is as high as 41% [1]. The best option for limb revascularization is to make an extra-anatomic bypass totally extraperitoneal and antero-laterally, using iliac artery as an inflow, away from the groin and infected tissues.<sup>10</sup> Iain J. D. McCallum, *et al.* reported that the primary graft patency is 45% at 1 year and this bypass is only justified if multilevel skip grafting is contraindicated [11].

*Staphylococcus aureus* is the commonest pathogen responsible for vascular graft infections [6,12]. In this patient, the growth of *E. coli* may be related to a bout of colitis or sigmoiditis that might have followed a colonoscopic examination of the polypi as a part of the regular surveillance, which was done 9 months earlier to the last presentation.

## Conclusion

The antero-lateral (supra-iliac) approach is an effective and safe temporary (and possibly long-term) extra-anatomic revascularization option to bypass a septic groin, which might be considered in limb-threatening ligation of the ilio-femoral arterial segment.

## Bibliography

1. Carlos A Hinojosa, *et al.* "Aortobifemoral Reconstruction with Right Extra-Anatomic Obturator Foramen Bypass due to a Septic Groin". *Vascular Specialist International* 32.2 (2016): 57-61.
2. Trout HH and Smith CA. "Lateral iliopopliteal arterial bypass as an alternative to obturator bypass". *American Surgery* 48.2 (1982): 63-64.
3. Robert B, *et al.* "Extra-anatomic bypass: A closer view". *Journal of Vascular Surgery* 6 (1987): 437-446.
4. Joseph R Schneider. "Extra-Anatomic Bypass. Rutherford's Vascular Surgery, 8th ed". Elsevier Saunders. Chapter 111 (2014): 1736-1739.
5. Carbs E., *et al.* "Iliac to Popliteal Artery Bypass through the Iliac Wing: An Alternative Extracavitary Route for Management of Complex Groin Injuries". *Annals of Vascular Surgery* 13.2 (1999): 209-215.
6. Cagatay Engin., *et al.* "Management of Vascular Infection in the Groin". *Texas Heart Institute Journal* 32.4 (2005): 529-534.
7. Szilagyi DE, *et al.* "Infection in arterial reconstruction with synthetic grafts". *Annual Surgery* 176.3 (1972): 321-333.
8. Samson RH., *et al.* "A modified classification and approach to the management of infections involving peripheral arterial prosthetic grafts". *Journal of Vascular Surgery* 8.2 (1988): 147-153.
9. Karl T., *et al.* "Indications of V.A.C. ®- Therapy in the treatment of postoperative wound healing disorders after alloplastic bypass implantation. A modified classification". *Vasomed* 22 (2010): 160-163.
10. Ascer E., *et al.* "The preferential use of the external iliac artery as an inflow source for redo femoropopliteal and infrapopliteal bypass". *Journal of Vascular Surgery* 18.2 (1993): 234-239.
11. Iain JD McCallum., *et al.* "Outcome of Ilio- Popliteal Grafting for Peripheral Arterial Disease". *Angiology* 61 (2010): 74-77.
12. Kiriakos Ktenidis and Argyrios Giannopoulos. "Current Management of Vascular Infections. Vascular Surgery – Principles and Practice". Dai Yamanouchi (2012): 31-34.

**Volume 3 Issue 6 June 2019**

**© All rights are reserved by Huthayfa Ghanem., et al.**