



Does all Acute Hiatal Hernia Needs Surgical Management? Role of Nasogastric Decompression in Hiatal Hernia

Alejandro Castaneda¹, Antonio Galindo¹, Chinthaka Bulathsinghala², Joseph Varon³ and Salim Surani^{4*}

¹Research Assistant, Dorrington Medical Associates, Universidad Autónoma de Baja California, Houston, Texas, USA

²Assistant Professor, University of North Texas, USA

³Professor of Acute and Continuing Care, The University of Texas Health Science Center at Houston, Clinical Professor of Medicine, the University of Texas Medical Branch at Galveston, Chief of Critical Care Services, United Memorial Medical Center, United General Hospital, Houston, Texas, USA

⁴Adjunct Clinical Professor of Medicine, Division of Pulmonary, Critical Care and Sleep Medicine, Texas A&M University, Health Science Center, Corpus Christi, Texas, USA

***Corresponding Author:** Salim Surani, Adjunct Clinical Professor of Medicine, Division of Pulmonary, Critical Care and Sleep Medicine, Texas A&M University, Health Science Center, Corpus Christi, Texas, USA

Received: April 08, 2019; **Published:** April 24, 2019

Abstract

Hiatal hernia is a condition involving herniation of abdominal cavity contents through the diaphragm into the mediastinum. These hernias may compromise mediastinal structures and can be life threatening for which emergent treatment may be required. We recently had such one case of a 56-year old gentleman with a large transverse left posterior diaphragmatic hernia and herniation of the stomach and spleen into the left pleural cavity compromising the mediastinal structures. Conservative management with a nasogastric tube decompression provided emergent resolution of symptoms. Nasogastric decompression may be used as a temporary therapeutic intervention in these patients.

Keywords: Hiatal Hernia; Respiratory Distress; Nasogastric Decompression; Nasogastric Tube

Introduction

Hiatal hernia is a condition involving herniation of abdominal cavity contents into the thoracic cage via the diaphragm. It is commonly associated with laxity of the phreno-esophageal membrane. These hernias are typically asymptomatic, but several complications can occur including but not limiting to gastroesophageal reflux disease (GERD), acute bleeding and in some cases even severe compromise of mediastinal structures that can be life threatening for which emergent treatment may be required [1].

Case Presentation

A 56-year old gentleman with a history of hypertension, hyperlipidemia, diabetes, seizures, diverticulosis, cerebral vascular accident with residual right sided hemiparesis, presented to the emergency department (ED) with complaints of right upper quadrant pain, persistent nausea and vomiting for 1 day, chills, generalized weakness, shortness of breath and headache. In the ED, the patient appeared anxious and was dyspneic. Blood pressure was 100/60 mm hg, heart rate 128 beats per minute, respiratory rate 26/min, SaO₂ 93%, temperature 101.5 °F

Physical examination revealed, left bowel sounds in left lung base. The rest of the physical examination was otherwise unremarkable. Complete blood count revealed a white blood count of 22.48×10^3 . Blood chemistry showed creatinine of 2.56 mg/dL and lactic acid 4.64 mmol/L. B-type natriuretic peptide was 5934 pg/mL and troponin-I 0.24 ng/mL.

Chest radiograph and abdominal computed tomography (CT) scan revealed a massive distention of the stomach, left diaphragmatic rupture, and herniation of abdominal content compromising the mediastinal structures (Figure 1 and 2).

A nasogastric tube (NGT) was placed draining 1500ml of bilious liquid. Intravenous (IV) fluid resuscitation and empiric antibiotic therapy were started while optimizing his cardiac function. Follow up chest radiograph revealed the NGT in place. The following day the patient had almost complete resolution of his initial symptoms. After the cardiac clearance, the patient underwent exploratory laparotomy with reduction of left diaphragmatic hernia and primary repair of left hemidiaphragm. He was found to have a large transverse left posterior diaphragmatic hernia with herniation of nearly the entire stomach and spleen into the left pleural cavity.

The patient condition improved and was discharged home. On follow-up appointment as out-patient he has no recurrent symptoms.

Discussion

Over the past few decades, hiatal hernia has been listed as a primary or secondary cause of hospital admissions [2]. The exact prevalence of hiatal hernia is difficult to determine, with estimates from 10% to 80% of the adult population and increasing with obesity and age [3]. These hernias are subdivided into sliding hernias (85-95%), and para-esophageal hernias (5-15%) [4]. In cases of sliding hiatal hernias, there is a widening of the muscular hiatal tunnel, and circumferential laxity of the phreno-esophageal membrane, allowing the stomach to herniate into the thoracic cavity [4]. Paraesophageal hernias, are less common [5]. Approximately 50% of patients with this type of hernias are asymptomatic [6]. However, if mechanical obstruction of either the distal esophagus or stomach is present, the patient could develop dysphagia, epigastric pain, vomiting, postprandial fullness, early satiety or dyspnea [6].

The diagnosis of hiatal hernia typically is done through four different methods: radiographic barium swallow examination, esophagogastroduodenoscopy ambulatory multichannel intraluminal impedance pH monitoring and high-resolution esophageal manometry [7].

The highly unspecific clinical presentation of paraoesophageal hernias, in addition to the need of specific imaging resources, entails a possible delayed diagnosis and treatment of this condition, that may present an increased risk of a wide variety of life threatening complications [8].

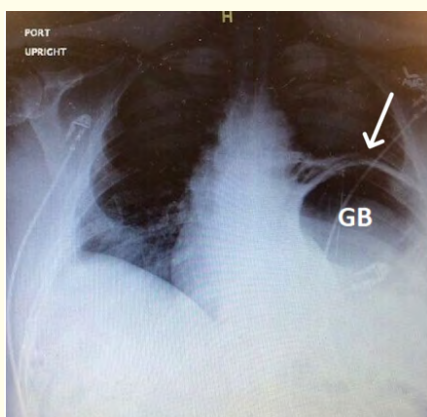


Figure 1: Chest radiograph depicts massive gastric bubble (GB) with elevation of left hemidiaphragm (arrow), compromising mediastinal structures, shifting them to the right.

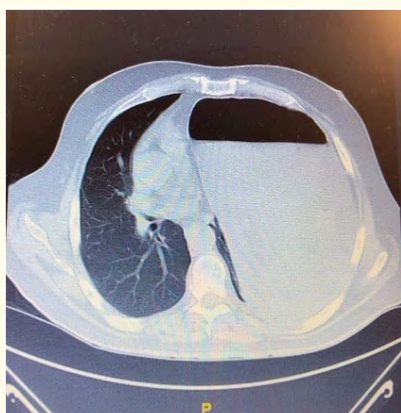

Figure 2: Computed tomography of abdomen shows distention of the stomach due to air, with herniation, compromising mediastinal structures.

Amongst the most recognized complications associated with hiatal hernias, hemorrhage is one of the most urgent situations related to this condition. The blood loss may be secondary to ulcerations or erosions of the mucosa in an area of gastric folding, known as Cameron lesions and iron deficiency anemia from these specific lesions being the common finding. Other important complications include perforation, ischemia, strangulation or aspiration pneumonia. The last one could be especially important in our patient with 1500 cc of bilious liquid (a potential risk for aspiration), which was successfully evacuated with the NGT decompression [8,9].

Prompt management of hiatal hernias is recommended for all symptomatic patients due to the tendency of paraesophageal hernias to enlarge, making the therapeutic intervention more difficult and increasing the risk of complications [6].

The therapeutic approach of this clinical entity is based on the severity of the presentation and the data obtained from the diagnostic methods previously mentioned. The two main approaches to the management of this condition, are the medical approach, that focuses in the alleviation of the symptoms caused by gastroesophageal reflux, achieved with medications that inhibit gastric acid secretions, such as proton pump inhibitors and histamine 2 receptor antagonists and the surgical approach that is considered the first line of treatment in high risk situations such as gastric obstruction or ischemia and in situation on which the gastric component is severely compromised [3,6].

In this case, our patient underwent a chest x-ray and abdominal CT scan which revealed a large gastric bubble in the thoracic cavity, compromising mediastinal structures and leading to his symptom. Our patient underwent immediate placement of NGT and decompression of the gastric content resulting in improvement of his symptoms.

Decompression of the stomach has been shown to offer clinical benefits, such as decreasing the severity of symptoms in the first 24hrs. In our case, due to the patient's cardiac status, utilizing a NGT decompression was elected as initial conservative management with adequate response.

Conclusion

Patients with symptomatic hiatal hernias may require urgent surgical care to avoid the possibility of life-threatening complications. Gastric decompression with an NGT insertion may be considered

as a first line therapy in some patients. This method represents a reliable alternative to traditional surgical management while allowing time for optimizing the patient condition.

Conflict of Interest

There is no declared competing conflict of interest from the authors.

Bibliography

1. Hyun J and Bak Y. "Clinical significance of hiatal hernia". *Gut and Liver* 5.3 (2011): 267-277.
2. Mohammed I., et al. "Risk factors for gastroesophageal reflux disease symptoms: A community study". *Alimentary Pharmacology and Therapeutics* 21.7 (2005): 821-827.
3. Roman S and Kahrilas P. "The diagnosis and management of hiatus hernia". *BMJ* 349 (2014): g6154-g6154.
4. Kahrilas P., et al. "Approaches to the diagnosis and grading of hiatal hernia". *Best Practice and Research: Clinical Gastroenterology* 22.4 (2008): 601-616.
5. Verma A., et al. "Hiatus hernia in a 6-year-old boy: A rare presentation". *International Journal of Medicine and Public Health* 4.4 (2014): 514.
6. Schieman C., et al. "Paraesophageal hernia: clinical presentation, evaluation, and management controversies". *Thoracic Surgery Clinics* 19.4 (2009): 473-484.
7. Yu H., et al. "Esophageal hiatal hernia: Risk, diagnosis and management". *Expert Review of Gastroenterology and Hepatology* 12.4 (2018): 319-329.
8. Kapadia S., et al. "Cameron ulcers: An atypical source for a massive upper gastrointestinal bleed". *World Journal of Gastroenterology* 18.35 (2012): 4959-4961
9. Shafii A., et al. "Perforated gastric corpus in a strangulated paraesophageal hernia: a case report". *Journal of Medical Case Reports* 3.1 (2009): 6507.

Volume 3 Issue 5 May 2019

© All rights are reserved by Salim Surani, et al.